

# Management of adrenal incidentalomas: European Society of Endocrinology Clinical Practice Guideline in collaboration with the European Network for the Study of Adrenal Tumors

Martin Fassnacht<sup>1,2</sup>, Wiebke Arlt<sup>3,4</sup>, Irina Bancos<sup>3,4,5</sup>, Henning Dralle<sup>6</sup>,  
John Newell-Price<sup>7,8</sup>, Anju Sahdev<sup>9</sup>, Antoine Tabarin<sup>10</sup>, Massimo Terzolo<sup>11</sup>,  
Stylianos Tsagarakis<sup>12</sup> and Olaf M Dekkers<sup>13,14</sup>

<sup>1</sup>Department of Internal Medicine I, Division of Endocrinology and Diabetes, University Hospital, University of Würzburg, Würzburg, Germany, <sup>2</sup>Comprehensive Cancer Center Mainfranken, University of Würzburg, Würzburg, Germany, <sup>3</sup>Institute of Metabolism & Systems Research, University of Birmingham, Birmingham, UK, <sup>4</sup>Centre for Endocrinology, Diabetes and Metabolism, Birmingham Health Partners, Birmingham, UK, <sup>5</sup>Division of Endocrinology, Metabolism, Nutrition and Diabetes, Mayo Clinic, Rochester, Minnesota, USA, <sup>6</sup>Department of General, Visceral, and Vascular Surgery, Martin-Luther-University Halle-Wittenberg, Halle (Saale), Germany, <sup>7</sup>Department of Oncology and Metabolism, Medical School, University of Sheffield, Sheffield, UK, <sup>8</sup>Endocrine Unit, Royal Hallamshire Hospital, Sheffield Teaching Hospitals NHS Foundation Trust, Sheffield, UK, <sup>9</sup>Department of Imaging, St Bartholomew's Hospital, Barts Health, London, UK, <sup>10</sup>Department of Endocrinology and INSERM U862, University and CHU of Bordeaux, Pessac, France, <sup>11</sup>Internal Medicine 1, Department of Clinical and Biological Sciences, University of Turin, Turin, Italy, <sup>12</sup>Department of Endocrinology, Diabetes and Metabolism, Evangelismos Hospital, Athens, Greece, <sup>13</sup>Departments of Clinical Epidemiology and Internal Medicine, Leiden University Medical Centre, Leiden, The Netherlands, and <sup>14</sup>Department of Clinical Epidemiology, Aarhus University, Aarhus, Denmark

Correspondence  
should be addressed  
to M Fassnacht  
**Email**  
fassnacht\_m@ukw.de

## Abstract

By definition, an adrenal incidentaloma is an asymptomatic adrenal mass detected on imaging not performed for suspected adrenal disease. In most cases, adrenal incidentalomas are nonfunctioning adrenocortical adenomas, but may also represent conditions requiring therapeutic intervention (e.g. adrenocortical carcinoma, pheochromocytoma, hormone-producing adenoma or metastasis). The purpose of this guideline is to provide clinicians with best possible evidence-based recommendations for clinical management of patients with adrenal incidentalomas based on the GRADE (Grading of Recommendations Assessment, Development and Evaluation) system. We predefined four main clinical questions crucial for the management of adrenal incidentaloma patients, addressing these four with systematic literature searches: (A) How to assess risk of malignancy?; (B) How to define and manage low-level autonomous cortisol secretion, formerly called 'subclinical' Cushing's syndrome?; (C) Who should have surgical treatment and how should it be performed?; (D) What follow-up is indicated if the adrenal incidentaloma is not surgically removed?

*Selected recommendations:* (i) At the time of initial detection of an adrenal mass establishing whether the mass is benign or malignant is an important aim to avoid cumbersome and expensive follow-up imaging in those with benign disease. (ii) To exclude cortisol excess, a 1 mg overnight dexamethasone suppression test should be performed (applying a cut-off value of serum cortisol  $\leq 50$  nmol/L (1.8  $\mu\text{g/dL}$ )). (iii) For patients without clinical signs of overt Cushing's syndrome but serum cortisol levels post 1 mg dexamethasone  $>138$  nmol/L ( $>5$   $\mu\text{g/dL}$ ), we propose the term 'autonomous cortisol secretion'. (iv) All patients with '(possible) autonomous cortisol' secretion should be screened for hypertension and type 2 diabetes mellitus, to ensure these are appropriately treated. (v) Surgical treatment should be considered in an individualized approach in patients with 'autonomous cortisol secretion' who also have comorbidities that are potentially related to cortisol excess. (vi) In principle, the appropriateness of surgical intervention should be guided by the likelihood of malignancy, the presence and degree of hormone excess, age, general health and patient preference. (vii) Surgery is not usually indicated in patients

with an asymptomatic, nonfunctioning unilateral adrenal mass and obvious benign features on imaging studies. We provide guidance on which surgical approach should be considered for adrenal masses with radiological findings suspicious of malignancy. Furthermore, we offer recommendations for the follow-up of patients with adrenal incidentaloma who do not undergo adrenal surgery, for those with bilateral incidentalomas, for patients with extra-adrenal malignancy and adrenal masses and for young and elderly patients with adrenal incidentalomas.

*European Journal of  
Endocrinology*  
(2016) **175**, G1–G34

## 1. Summary of recommendations

The recommendations are worded as recommend (strong recommendation) and suggest (weak recommendation). The quality of evidence behind the recommendations is classified as low very low (⊕○○○), low (⊕⊕○○), moderate (⊕⊕⊕○) and strong (⊕⊕⊕⊕). For further details, see Section 3.4.

### 1.1. General remarks

**R 1.1.** We recommend that patients with adrenal incidentaloma be discussed in a multidisciplinary expert team meeting, if at least one of the following criteria is met:

- Imaging is not consistent with a benign lesion.
- There is evidence of hormone excess (including ‘autonomous cortisol secretion’).
- Evidence of significant tumor growth during follow-up imaging.
- Adrenal surgery is considered.

### 1.2. Assessment of the risk of malignancy

**R 2.1.** We recommend aiming to establish if an adrenal mass is benign or malignant at the time of initial detection.

**R 2.2.** We recommend that all adrenal incidentalomas undergo an imaging procedure to determine if the mass is homogeneous and lipid-rich and therefore benign (⊕○○○). For this purpose, we primarily recommend the use of noncontrast CT (⊕○○○).

**R 2.3.** We suggest that if the noncontrast CT is consistent with a benign adrenal mass (Hounsfield units ≤10) that is homogeneous and smaller than 4 cm, no further imaging is required (⊕○○○).

**R 2.4.** If the adrenal mass is indeterminate on noncontrast CT and the results of the hormonal work-up do not indicate significant hormone excess, three options should be considered by a multidisciplinary team acknowledging the patient’s clinical context: immediate

additional imaging with another modality, interval imaging in 6–12 months (noncontrast CT or MRI), or surgery without further delay.

**R 2.5.** We recommend against the use of an adrenal biopsy in the diagnostic work-up of patients with adrenal masses unless there is a history of extra-adrenal malignancy and additional criteria are fulfilled (see **R 6.3.5**).

### 1.3. Assessment for hormone excess

**R 3.1.** We recommend that every patient with an adrenal incidentaloma should undergo careful assessment including clinical examination for symptoms and signs of adrenal hormone excess.

**R 3.2.** We recommend that all patients with adrenal incidentalomas undergo a 1 mg overnight dexamethasone suppression test to exclude cortisol excess (⊕⊕○○).

**R 3.3.** We suggest interpretation of the results of the 1 mg overnight dexamethasone test as a continuous rather than categorical (yes/no) variable (⊕○○○). However, we recommend using serum cortisol levels post dexamethasone ≤50 nmol/L (≤1.8 μg/dL) as a diagnostic criterion for the exclusion of autonomous cortisol secretion (⊕⊕○○).

**R 3.4.** We suggest that post-dexamethasone serum cortisol levels between 51 and 138 nmol/L (1.9–5.0 μg/dL) should be considered as evidence of ‘possible autonomous cortisol secretion’ and cortisol levels post dexamethasone >138 nmol/L (>5.0 μg/dL) should be taken as evidence of ‘autonomous cortisol secretion’. Additional biochemical tests to confirm cortisol secretory autonomy and assess the degree of cortisol secretion might be required. However, for the clinical management, the presence of potentially cortisol-related comorbidities and age of the patient are of major importance.

**R 3.5.** We recommend against considering ‘autonomous cortisol secretion’ as a condition with a high risk for the development of overt Cushing’s syndrome (⊕⊕○○).

**R 3.6.** We recommend screening patients with ‘possible autonomous cortisol secretion’ or ‘autonomous cortisol

secretion' for hypertension and type 2 diabetes mellitus (⊕000) and suggest offering appropriate treatment of these conditions.

**R 3.7.** We suggest screening patients with 'autonomous cortisol secretion' for asymptomatic vertebral fractures (⊕000) and to consider appropriate treatment of these conditions (⊕000).

**R 3.8.** We suggest an individualized approach to consider patients with 'autonomous cortisol secretion' due to a benign adrenal adenoma and comorbidities potentially related to cortisol excess for adrenal surgery (⊕000). Age, degree of cortisol excess, general health, comorbidities and patient's preference should be taken into account. In all patients considered for surgery, ACTH-independency of cortisol excess should be confirmed.

**R 3.9.** We recommend excluding pheochromocytoma by measurement of plasma-free metanephrines or urinary fractionated metanephrines.

**R 3.10.** In patients with concomitant hypertension or unexplained hypokalemia, we recommend the use of the aldosterone/renin ratio to exclude primary aldosteronism.

**R 3.11.** We suggest measurement of sex hormones and steroid precursors in patients with clinical or imaging features suggestive of adrenocortical carcinoma.

#### 1.4. Surgical treatment

**R 4.1.** We recommend adrenalectomy as the standard of care for unilateral adrenal tumors with clinically significant hormone excess.

**R 4.2.** We recommend against performing surgery in patients with an asymptomatic, nonfunctioning unilateral adrenal mass and obvious benign features on imaging studies (⊕000).

**R 4.3.** We suggest performing laparoscopic adrenalectomy in patients with unilateral adrenal masses with radiological findings suspicious of malignancy and a diameter ≤6 cm, but without evidence of local invasion (⊕000).

**R 4.4.** We recommend performing open adrenalectomy for unilateral adrenal masses with radiological findings suspicious of malignancy and signs of local invasion (⊕000).

**R 4.5.** We suggest an individualized approach in patients that do not fall in one of the above-mentioned categories (⊕000).

**R 4.6.** We recommend perioperative glucocorticoid treatment at major surgical stress doses as recommended by guidelines, in all patients undergoing surgery for an

adrenal tumor where there is evidence of '(possible) autonomous cortisol secretion', i.e. who do not suppress to <50 nmol/L after 1 mg dexamethasone overnight.

#### 1.5. Follow-up of patients not undergoing adrenal surgery after initial assessment

**R 5.1.** We suggest against further imaging for follow-up in patients with an adrenal mass <4 cm with clear benign features on imaging studies (⊕000).

**R 5.2.** In patients with an indeterminate adrenal mass (by imaging) opting not to undergo adrenalectomy following initial assessment, we suggest a repeat noncontrast CT or MRI after 6–12 months to exclude significant growth (⊕000). We suggest surgical resection if the lesion enlarges by more than 20% (in addition to at least a 5 mm increase in maximum diameter) during this period. If there is growth of the lesion below this threshold, additional imaging after 6–12 months should be performed.

**R 5.3.** We suggest against repeated hormonal work-up in patients with a normal hormonal work-up at initial evaluation unless new clinical signs of endocrine activity appear or there is worsening of comorbidities (e.g. hypertension and type 2 diabetes) (⊕000).

**R 5.4.** In patients with 'autonomous cortisol secretion' without signs of overt Cushing's syndrome, we suggest annual clinical reassessment for cortisol excess comorbidities potentially related to cortisol excess (⊕000). Based on the outcome of this evaluation, the potential benefit of surgery should be considered.

#### 1.6. Special circumstances

##### 1.6.1. Patients with bilateral adrenal incidentalomas

**R 6.1.1.** We recommend that for patients with bilateral adrenal masses, each adrenal lesion be assessed at the time of initial detection according to the same imaging protocol as for unilateral adrenal masses to establish if either or both masses are benign or malignant.

**R 6.1.2.** We recommend that all patients with bilateral adrenal incidentalomas should undergo clinical and hormonal assessment identical to that in patients with unilateral adrenal incidentaloma (see Section 5.3). The same applies for the assessment of comorbidities that might be related to autonomous cortisol secretion. In addition, serum 17-hydroxyprogesterone should be measured to exclude congenital adrenal hyperplasia, and testing for adrenal insufficiency should be considered,

if suspected on clinical grounds or if imaging suggests bilateral infiltrative disease or hemorrhages.

**R 6.1.3.** We suggest that for patients with bilateral incidentaloma, the same recommendations regarding the indication for surgery and follow-up are used as for patients with unilateral adrenal incidentalomas.

**R 6.1.4.** We suggest that in patients with bilateral adrenal masses, bilateral adrenalectomy is not performed for ACTH-independent 'autonomous cortisol secretion' without clinical signs of overt Cushing's syndrome. In selected patients, a unilateral adrenalectomy of the dominant lesion might be considered using an individualized approach considering age, degree of cortisol excess, general condition, comorbidities and patient preference.

#### 1.6.2. Adrenal incidentalomas in young or elderly patients

**R 6.2.1.** We recommend urgent assessment of an adrenal mass in children, adolescents, pregnant women and adults <40 years of age because of a higher likelihood of malignancy.

**R 6.2.2.** We suggest the use of MRI rather than CT in children, adolescents, pregnant women and adults <40 years of age if dedicated adrenal imaging is required.

**R 6.2.3.** We recommend that the management of patients with poor general health and a high degree of frailty be kept in proportion to potential clinical gain.

#### 1.6.3. Patients with a newly diagnosed adrenal mass and a history of extra-adrenal malignancy

**R 6.3.1.** We recommend measurement of plasma or urinary metanephrines to exclude pheochromocytoma in patients with extra-adrenal malignancy with an indeterminate mass, even if the adrenal mass is likely to be a metastasis. We suggest additional hormonal work-up based on an individualized approach.

**R 6.3.2.** We suggest that in patients with a history of extra-adrenal malignancy, FDG-PET/CT, performed as part of investigations for the underlying malignancy, can replace other adrenal imaging techniques.

**R 6.3.3.** We recommend that in patients with a history of extra-adrenal malignancy, adrenal lesions, characterized as benign (see also **R 2.3.**) by noncontrast CT, require no further specific adrenal imaging follow-up.

**R 6.3.4.** For indeterminate lesions in patients with a history of extra-adrenal malignancy, we recommend imaging follow-up assessing the potential growth of the lesion at the same interval as imaging for the primary

malignancy. Alternatively, FDG-PET/CT, surgical resection or a biopsy (see also **R 6.3.5.**) can be considered.

**R 6.3.5.** We suggest performing a biopsy of an adrenal mass only if all of the following criteria are fulfilled: (i) the lesion is hormonally inactive (in particular, a pheochromocytoma has been excluded), (ii) the lesion has not been conclusively characterized as benign by imaging and (iii) management would be altered by knowledge of the histology.

**R 6.3.6.** We recommend assessment of residual adrenal function in patients with large bilateral adrenal metastases.

## 2. Adrenal Incidentaloma – clinical presentation and terminology

### 2.1. Definition, etiology and epidemiology of adrenal incidentalomas

An adrenal incidentaloma is an adrenal mass detected on imaging not performed for suspected adrenal disease. By this strict definition, the imaging study is not done for symptoms related to adrenal hormone excess (e.g. pheochromocytoma, Cushing's or Conn's syndrome) or an otherwise suspected adrenal mass, but rather for the evaluation of symptoms that are not obviously related to an adrenal problem, such as abdominal or back pain or kidney stones. Similarly, screening imaging in patients with a hereditary syndrome leading to adrenal tumors is outside the definition of an adrenal incidentaloma. In addition, adrenal masses discovered on an imaging study performed during tumor evaluation for extra-adrenal malignancies ('tumor staging' or follow-up) do not meet the strict definition of adrenal incidentaloma. However, as this is a clinically frequent scenario, we will address this in a specific chapter (see 5.6.3).

Previous recommendations and reviews (1, 2, 3, 4, 5, 6, 7, 8, 9, 10, 11, 12, 13) have not considered adrenal incidentalomas smaller than 1 cm. Although this cut-off is obviously somewhat arbitrary, we agree with this approach and would perform additional diagnostic work-up only in lesions  $\geq 1$  cm unless clinical signs and symptoms suggestive of adrenal hormone excess are present.

The etiology of adrenal incidentalomas varies and includes benign and malignant lesions derived from the adrenal cortex, the medulla or of extra-adrenal origin. The reported frequency varies, depending on the context of the study and inclusion size criteria (Table 1). Some authors conclude, however, that the prevalence of malignant and functional lesions is likely to be overestimated (3), mainly because the prevalence of malignancy in surgical

**Table 1** Adrenal incidentalomas – frequency of the different underlying tumor types (adapted according (9)). Due to the nature of these studies, a selection bias is very probable (the populations studied not reflecting a random sample of all patients with an adrenal incidentalomas) and most likely leads to an overestimation of the frequency of some tumor entities.

Tumor entity	Median (%)	Range (%)
Series including all patients with an adrenal mass*		
Adenoma	80	33–96
Nonfunctioning	75	71–84
Autonomously cortisol-secreting	12	1.0–29
Aldosterone-secreting	2.5	1.6–3.3
Pheochromocytoma	7.0	1.5–14
Adrenocortical carcinoma	8.0	1.2–11
Metastasis	5.0	0–18
Surgical series**		
Adenoma	55	49–69
Nonfunctioning	69	52–75
Cortisol-secreting	10	1.0–15
Aldosterone-secreting	6.0	2.0–7.0
Pheochromocytoma	10	11–23
Adrenocortical carcinoma	11	1.2–12
Myelolipoma	8.0	7.0–15
Cyst	5.0	4.0–22
Ganglioneuroma	4.0	0–8.0
Metastasis	7.0	0–21

\*Data from references: (2, 6, 14); \*\*Data from references: (2, 3, 6, 7, 10, 14, 17, 18).

series is usually higher than in series including all patients presenting with an adrenal mass. There is, however, clear evidence that the vast majority of adrenal incidentalomas are benign adrenocortical adenomas.

The incidence and prevalence of adrenal incidentalomas can only be extrapolated from imaging or autopsy studies. Autopsy studies suggest a prevalence of clinically unapparent adrenal masses of around 2% (range 1.0–8.7%), which increases with age (5, 6, 7). Radiological studies report a frequency of around 3% in the age of 50 years, which increases up to 10% in the elderly (2, 5, 6, 7, 14, 15, 16). In childhood, adrenal incidentalomas are extremely rare.

## 2.2. Remarks on terminology

As already discussed above, the term ‘adrenal incidentaloma’ can be defined by very restrictive criteria, but is sometimes used in a much broader sense, referring to any adrenal mass. Therefore, in the guideline, we frequently speak of adrenal masses or lesions.

Another term, which is widely used in the literature in the context of adrenal incidentaloma, is ‘subclinical Cushing’s syndrome’ (19). This term aims to define

**Table 2** Comorbidities possibly associated with adrenal incidentalomas with ‘autonomous cortisol secretion’.

Comorbidities	Reference
Hypertension	(23, 31, 32, 33, 34, 35, 36)
Glucose intolerance/type 2 diabetes mellitus	(23, 31, 32, 33, 34, 35, 36, 37, 38, 39)
Obesity	(23, 31, 32, 33)
Dyslipidemia	(23, 31, 32, 36, 40)
Osteoporosis	(35, 38, 41, 42, 43, 44, 45, 46)

patients with biochemical evidence of cortisol excess, but without the so-called ‘specific’ clinical signs of Cushing’s syndrome (mainly the lack of catabolic features such as myopathy and skin fragility). There is, however, clear evidence that patients with clinically unapparent cortisol excess very rarely develop Cushing’s syndrome (1, 2, 20, 21, 22, 23, 24, 25) and that this condition is different from overt Cushing’s syndrome, which is clearly associated with severe morbidity and elevated mortality (26, 27, 28, 29, 30). Nevertheless, there is some evidence that this low-grade autonomous cortisol excess might be associated with certain comorbidities (Table 2). Thus, the panel unanimously decided to avoid the term ‘subclinical Cushing’s syndrome’ and to use instead the term ‘autonomous cortisol secretion’ in the context of an adrenal incidentaloma throughout the guideline text (for the exact definition, see chapter 5.3).

Although the term ‘laparoscopic adrenalectomy’ is actually reserved for operations that use a transperitoneal approach and should be distinguished from the term retroperitoneoscopic adrenalectomy, this never gained general acceptance. Therefore, in this guideline, we use the term ‘laparoscopic adrenalectomy’ to refer to minimally invasive approaches including retroperitoneoscopic surgery.

## 2.3. Short overview on adrenal imaging

For the differentiation of malignant from benign adrenal tumors, there are three main imaging techniques in current use: computed tomography (CT), magnetic resonance imaging (MRI) and positron emission tomography with <sup>18</sup>F-2-deoxy-D-glucose (mostly combined with CT; FDG-PET/CT). CT and MRI are techniques mainly aiming to identify benign lesions, therefore representing tools designed for the exclusion of adrenal malignancy (47, 48, 49, 50). Conversely, FDG-PET/CT is mainly used for the detection of malignant disease (51, 52, 53).

CT has a high spatial and quantitative contrast resolution, which allows assessment of tissue density by measuring X-ray absorption of tissues. This allows

calculation of tissue attenuation or tissue density values, which are measured in Hounsfield units (HU) and quantify X-ray absorption of tissues compared with water, which is conventionally allocated a HU value of 0. For noncontrast (or 'unenanced') CT, HU of  $\leq 10$  is the most widely used threshold attenuation value for the diagnosis of a lipid-rich, benign adrenal adenoma (54). However, on noncontrast CT, some 30% of benign adenomas have an attenuation value of  $>10$  HU and are considered lipid-poor, overlapping in density with malignant lesions and pheochromocytomas (55, 56, 57).

**Contrast-enhanced washout CT** utilizes the unique perfusion pattern of adenomas. Adenomas take up intravenous CT contrast rapidly, but also have a rapid loss of contrast – a phenomenon termed 'contrast enhancement washout'. It is assumed that malignant adrenal lesions usually enhance rapidly but demonstrate a slower washout of contrast medium. This washout phenomenon can be quantified by 'contrast washout values', which involve lesion attenuation measurements at specific time points acquired in a dedicated adrenal CT: before injection of contrast medium ( $HU_{\text{native}}$ ), at 60s following injection of contrast medium ( $HU_{\text{max}}$ ) and then at 10 or 15 min after contrast injection. This allows calculation of the relative contrast enhancement washout ( $=100 \times (HU_{\text{max}} - HU_{10/15 \text{ min}}) / HU_{\text{max}}$ ) and absolute contrast enhancement washout ( $=100 \times (HU_{\text{max}} - HU_{10/15 \text{ min}}) / (HU_{\text{max}} - HU_{\text{native}})$ ). A relative washout  $>40\%$  and an absolute washout  $>60\%$  is assumed to suggest that an adrenal lesion is benign (56, 58, 59, 60).

**MRI** is a nonionizing radiation-based imaging modality utilizing weak radio wave signals emitted by body tissues when the body is placed in a strong magnetic field and radio frequency pulses are applied. The advantages of MRI over CT are its lack of radiation exposure, lack of iodine-based contrast media and its superior tissue contrast resolution. For the differentiation of benign and malignant adrenal masses, the MRI technique of chemical shift imaging is most commonly used (60, 61, 62, 63, 64, 65). Chemical shift imaging relies on the fact that, within magnetic fields, protons in water vibrate at a slightly different frequency than protons in lipid. As a result, water and fat protons oscillate in and out of phase with respect to one another. By selecting appropriate sequencing parameters, separate images can be generated with water and fat protons oscillating in phase or out of phase to each other. Adrenal adenomas

with a high content of intracellular lipid usually lose signal intensity on out-of-phase images compared with in-phase images, whereas malignant lesions and pheochromocytomas (but also lipid-poor adrenal adenomas) that all lack intracellular lipid remain unchanged (58, 65, 66). Simple visual assessment of signal intensity loss is diagnostic in most cases, but quantitative methods may be useful in less clear-cut cases. Quantitative analysis can be made using the adrenal-to-spleen signal ratio and the signal intensity index. MR signal intensity units are arbitrary units, unlike CT, and, therefore, are subject to numerous technical variations.

**$^{18}\text{F}$ -FDG-PET** is a nuclear medicine modality that provides quantitative tomographic images after intravenous injection of a beta-radiation-emitting radiotracer (18-Fluorine) used to label 2-deoxy-D-glucose rendering fluoro-deoxyglucose ( $^{18}\text{F}$ -FDG). Both glucose and deoxyglucose enter cells via cell glucose transporters and undergo phosphorylation, but while glucose undergoes further enzymatic breakdown, deoxyglucose becomes trapped in intracellular compartments. Cancer cells have an increased requirement for glucose and, therefore, take up more glucose and deoxyglucose than normal cells (67). However,  $^{18}\text{F}$ -FDG is not a specific marker for cancer cells but a marker only for increased glucose metabolism; thus, uptake can also be increased in cells with an increased energy requirement due to conditions other than cancer. Quantitative measurement of  $^{18}\text{F}$  concentrations within tissues provides the most commonly used clinical measurement index, standard uptake value (SUV), which compares the intensity of uptake of  $^{18}\text{F}$  in the adrenal lesion to the average uptake of whole body. SUV values have been utilized to differentiate between benign and malignant adrenal lesions. FDG-PET has a high sensitivity for detection of metabolic changes, but its spatial resolution for anatomical localization is poor. The solution is a hardware fusion between PET and CT (PET/CT) allowing simultaneous acquisition of PET and CT data. In clinical practice, this involves injecting patients with  $^{18}\text{F}$ -FDG tracers at least 1 h before the start of combined PET/CT. Once postprocessing is complete, PET and CT data can be viewed separately, side-by-side or as a fused images (68).

Other potentially emerging imaging techniques (e.g. metomidate-based adrenal imaging (69, 70)) are not yet clinically widely available and, therefore, will not be discussed in this guideline.

## 2.4. Remarks on the difficulties with hormonal testing

Hormone assessment is crucial in the context of the work-up for an adrenal incidentaloma. However, there are several pitfalls that have to be considered (e.g. daily rhythm, sex/age dependency, limitations of assays, drug interactions). Furthermore, normal ranges vary substantially, depending on the method used, so it is essential to interpret test results in the context of the appropriate reference range. Due to space restrictions, we refer to other guidelines that have addressed these issues in more detail (71, 72).

## 3. Methods

### 3.1. Guideline working group

This guideline was developed by the *European Society of Endocrinology* (ESE) in collaboration with the *European Network for the Study of Adrenal Tumors* (ENSAT), supported by CBO (Dutch Institute for Health Care Improvement). The chairs of the working group Martin Fassnacht (clinical) and Olaf Dekkers (methodology) were appointed by the ESE Clinical Committee. The other members were suggested by the chairs and approved by the Clinical Committee of ESE: endocrinologists (Wiebke Arlt (UK), Irina Bancos (USA), John Newell-Price (UK), Antoine Tabarin (France), Massimo Terzolo (Italy), Stylianos Tsagarakis (Greece)), a radiologist (Anju Sahdev (UK) and an endocrine surgeon (Henning Dralle (Germany)). Irina Bancos served as representative of the *Endocrine Society USA*. The working group had three in-person meetings (December 2013, October 2014 and June 2015) and communicated by phone and email. Consensus was reached upon discussion; minority positions were taken into account in the reasoning behind recommendations. Before the process, all participants completed conflict of interest forms.

### 3.2. Target group

This guideline was developed for healthcare providers of patients with adrenal incidentalomas, i.e. endocrinologists, radiologists, surgeons and specialists in internal medicine. However, general practitioners might also find the guideline useful, as might our patients. In addition, the guideline document can serve as guidance for patient information leaflets. A draft of the guideline was reviewed by three experts in the field (see 'Acknowledgements'

section) and has been submitted for comments by ESE and ENSAT members. All comments and suggestions were then discussed and implemented as appropriate by the panel.

### 3.3. Aim

The overall purpose of this guideline is to provide clinicians with practical guidance for the management of patients with adrenal incidentalomas.

### 3.4. Summary of methods used for guideline development

The methods used have been described in more detail previously (73). In short, the guideline used GRADE (Grading of Recommendations Assessment, Development and Evaluation) as a methodological base. The first step was to define clinical question(s) (see Section 3.5), the second being a systematic literature search (see Section 3.6). After including relevant articles, we (i) estimated an average effect for specific outcomes (if possible) and (ii) rated the quality of the evidence. The quality of evidence behind the recommendations is classified as very low (⊕○○○), low (⊕⊕○○), moderate (⊕⊕⊕○) and strong (⊕⊕⊕⊕). Evidence tables are provided in the [Appendix](#) (see section on [Appendix](#) given at the end of this article).

For the recommendations, we took into account: (i) quality of the evidence; (ii) balance of desirable and undesirable outcomes and (iii) values and preferences (patient preferences, goals for health, costs, management inconvenience, feasibility of implementation etc.). (74, 75). The recommendations are worded as *recommend* (strong recommendation) and *suggest* (weak recommendation). Formal evidence syntheses were performed and graded only for recommendations addressing our initial questions. Additional recommendations based on good practice were not graded (76). Recommendations were derived from majority consensus of the Guideline Development Committee, but if members had substantive disagreements, this is acknowledged in the manuscript. For transparency, all recommendations provided are accompanied by text explaining why specific recommendations were made.

### 3.5. Clinical question, eligibility criteria and endpoint definition

At the beginning of the guideline development process, the panel agreed on the four most important clinical

**Table 3** Overview of the key clinical questions and predefined outcome parameters.

Clinical question	Predefined selection criteria and key outcome parameters <sup>a</sup>	Metrics of the literature search
<p><b>Question 1a</b> What is the most accurate diagnostic imaging procedure to determine whether an adrenal mass is benign in patients with unilateral or bilateral adrenal mass(es) on imaging with or without history of other malignant lesions?</p>	<ul style="list-style-type: none"> <li>Original studies on imaging in patients with incidentally discovered adrenal mass(es), including those undergoing staging for known extra-adrenal malignancy</li> <li>Diagnostic intervention: CT (noncontrast, contrast-enhanced, washout), MRI, FDG PET(CT)</li> <li>Reference standard: at least 50% of population had imaging-guided follow-up of any duration (for benign adrenal tumors), or histology after surgery or biopsy (for benign or malignant adrenal tumors)</li> <li>Reporting 2 × 2 contingency table data or at least two indices of diagnostic accuracy (sensitivity, specificity, negative or positive predictive value) and disease prevalence</li> </ul>	<ul style="list-style-type: none"> <li>5496 abstracts<sup>b</sup></li> <li>525 potentially relevant articles</li> <li>37 studies included in systematic review, 18 in meta-analysis</li> <li>Major reasons for exclusion of articles were lack of test accuracy data, inadequate or unclear reference standard and ineligible populations</li> </ul> <p>Other reasons for exclusion data collection pre-1990, sample size &lt;10, &lt;50% histology in malignant group, &gt;30% pheochromocytomas in malignant group, &gt;10% pheochromocytomas in benign group, no differentiation of children vs adults</p>
<p><b>Question 1b</b> What is the diagnostic accuracy of adrenal biopsy?</p>	<ul style="list-style-type: none"> <li>Original studies on patients with adrenal masses undergoing an adrenal biopsy procedure</li> <li>Outcomes: nondiagnostic rate, diagnostic accuracy data, complication rate</li> </ul> <p>For studies included in the diagnostic accuracy analysis: (i) Reference standard: at least 50% of population histology from either adrenalectomy or autopsy, imaging follow up 3–12 months or clinical follow-up of 2 years and (ii) reporting 2 × 2 contingency table data or at least two indices of diagnostic accuracy (sensitivity, specificity, negative or positive predictive value) and disease prevalence</p>	<ul style="list-style-type: none"> <li>175 abstracts<sup>c</sup></li> <li>80 potentially relevant article</li> <li>32 studies included in systematic review of at least one outcome</li> <li>Diagnostic accuracy data included from 8 studies</li> <li>Major reasons for exclusion overall were: no outcomes of interest, fewer than 10 patients, abstract only, patient overlap.</li> <li>Major exclusions from diagnostic accuracy analysis were: suboptimal reference standard and &gt;30% nonadenomas</li> </ul>
<p><b>Question 2a</b> Are certain biochemical profiles (see 4.2.1) associated with an increased cardiovascular, metabolic and fracture risk in patients with adrenal mass(es), in whom endocrine work-up for glucocorticoid excess was performed?</p>	<ul style="list-style-type: none"> <li>Original studies on patients with adrenal mass(es), in which endocrine work-up for glucocorticoid excess was performed. Studies independently of their respective definition of 'autonomous cortisol secretion' were eligible</li> <li>Comparison between patients based on biochemical profiles (including post-dexamethasone serum cortisol level) (question 2a)</li> </ul>	<p>Question 2a:</p> <ul style="list-style-type: none"> <li>201 abstracts</li> <li>23 potentially relevant articles</li> <li>12 studies included</li> </ul> <p>Question 2b:</p> <ul style="list-style-type: none"> <li>152 abstracts</li> <li>18 potentially relevant articles</li> </ul>
<p><b>Question 2b</b> Should surgery or a conservative/medical approach be recommended in patients with adrenal mass(es) and with defined biochemistry and cardiovascular, metabolic and fracture risk potentially indicative of mild glucocorticoid excess?</p>	<ul style="list-style-type: none"> <li>Comparison between surgery and conservative approach (question 2b)</li> <li>Reporting at least one of the crucial outcome: major cardiovascular events or mortality, vertebral fractures, metabolic profile, cardiovascular profile</li> </ul>	<ul style="list-style-type: none"> <li>4 studies included</li> <li>Excluded articles were not relevant for outcome parameters (<math>n=17</math>), no relevant design (<math>n=4</math>), overlapping populations (<math>n=2</math>), position paper (<math>n=1</math>), poorly defined patient cohort (<math>n=1</math>)</li> </ul>



**Question 3**

Should laparoscopic (=minimally-invasive) or open surgery be used for patients with nonmetastatic adrenal masses suspected to be malignant?

- Original studies on adults with suspected nonmetastatic adrenocortical carcinoma
- Comparison between laparoscopic vs open surgery
- Reporting at least one of the crucial outcomes: perioperative morbidity and mortality; completeness of resection; recurrence-free and overall survival; pain or patient satisfaction
- Publications with less than 10 patients per study arm were excluded

- 377 abstracts
- 13 potentially relevant articles
- 3 excluded due to samples size <10 patients per arm, 1 excluded as review
- 9 studies included

**Question 4**

What is the optimal follow-up in patients with an apparently benign adrenal incidentaloma in order to detect malignant transformation and/or development of overt hormone excess?

- Original studies on patients with an adrenal mass without hormone excess and no clear evidence of malignant adrenal tumor at time of primary diagnosis
- Reporting at least one of the following outcomes: malignancy in the adrenal (any kind); development of clinically relevant overt hormone excess (Cushing's syndrome, pheochromocytoma, primary hyperaldosteronism)

- 133 abstracts
- 19 potentially relevant articles
- 9 excluded due to overlapping population ( $n=3$ ), not relevant to question ( $n=3$ ), not available in full text ( $n=2$ ), unclear methods ( $n=1$ )
- Included:
  - 1 systematic review of 14 studies
  - 10 additional cohort studies

<sup>a</sup>For each question, we searched separately for systematic reviews between 2000 and February 2014 in NHS Economic Evaluation Database (NHSEED), Cochrane Database of Systematic Reviews and Database of Abstracts of Reviews of Effects. This revealed no relevant systematic review. Then, we searched for original articles in Medline published between 2000 and July 2014 (Question 3), October 2014 (Question 4), November 2014 (Question 2) and August 2015 (Question 1). <sup>b</sup>Summary of separately published meta-analysis (77). <sup>c</sup>Summary of separately published meta-analysis (78).

questions in the management of patients with adrenal incidentalomas (Table 3), for which a detailed literature search was subsequently performed.

### 3.6. Description of search and selection of literature

A literature search in electronic medical databases was performed for all four clinical questions separately. Of note, the approach for clinical question 1 (assessment of the risk of malignancy) differed as the search, study selection and also the evidence synthesis were performed in the context of a formal systematic review and meta-analysis published separately from the current guideline. For all four clinical questions, details of the yield of the search are shown in Table 3. In summary, we included 37 studies for clinical question 1 (with 18 fulfilling the criteria for inclusion in the meta-analysis), 12 studies for clinical question 2a (biochemical profile in adrenal incidentaloma), 4 studies for clinical question 2b (therapeutic approach in mild glucocorticoid excess), 9 studies for clinical question 3 (surgery) and 10 studies plus 1 relevant systematic review for clinical question 4 (follow-up).

## 4. Summary and conclusions from systematic literature reviews

### 4.1. Assessment of the risk of malignancy (Question 1)

#### 4.1.1. Assessment of the risk of malignancy by imaging (Question 1a)

The following paragraph represents a summary of a recent meta-analysis on the use of imaging for differentiating benign from malignant adrenal incidentalomas carried out with involvement of some of the guideline panel members (77). All studies using CT, MRI or FDG-PET in adults were considered eligible if: (i) included patients underwent imaging for any indications other than investigation of suspected adrenal mass; (ii) index imaging test characteristics were reported and (iii) at least 50% of patients had an optimal reference standard: histological diagnosis in malignant masses and availability of histology or imaging follow-up of any duration in the case of benign adrenal masses. Exclusion criteria are summarized in Table 3. The review looked separately at patients with true adrenal incidentaloma and patients with adrenal mass and a history of extra-adrenal malignancy.

We identified 37 studies for inclusion in the systematic review (49, 52, 61, 79, 80, 81, 82, 83, 84, 85, 86, 87, 88, 89, 90, 91, 92, 93, 94, 95, 96, 97, 98, 99, 100, 101, 102, 103, 104, 105, 106, 107, 108, 109, 110, 111, 112), with only 18 of them fulfilling the criteria for inclusion in the actual meta-analysis (61, 79, 80, 81, 82, 83, 84, 85, 86, 87, 88, 89, 90, 91, 92, 93, 94, 95). No randomized studies comparing imaging tests were identified. Risk of bias ranged from low to high, with the majority having unclear or high risk of bias (mainly due to unclear population selection, retrospective selection of the diagnostic threshold and inadequate reference standards with resulting concerns of the applicability of results).

Five commonly used diagnostic thresholds were studied: (i) tumor density >10HU on noncontrast CT; (ii) CT with delayed contrast media washout: absolute percentage washout and/or relative percentage washout at any washout percentage or delay time on enhanced CT; (iii) MRI chemical shift analysis: loss of signal intensity between in- and out-of-phase images (including both qualitative and quantitative estimates of signal loss) and, for FDG-PET or PET-CT, (iv) the maximum standardized uptake value (SUVmax) and (v) the ratio of SUVmax in the adrenal gland compared with the liver (adrenal–liver ratio).

The 37 studies included were generally small with a median sample size of 45 (range 12–181). Of the 18 studies included in the formal meta-analysis, 7 addressed purely incidental adrenal masses and 11 studies focused on patients with known extra-adrenal malignancy.

Limited data (2 studies with 102 true incidentalomas) suggest that CT density >10HU has a high sensitivity for detection of adrenal malignancy (100%, 95% CI: 91–100%), meaning that adrenal masses with a density of ≤10HU are unlikely to be malignant. In patients with a history of extra-adrenal malignancy, five studies evaluating the >10HU cut-off as indicative of malignancy showed high sensitivity (93%) for the detection of malignancy but variable specificity; this means that 7% of adrenal metastases were found to have a tumor density of ≤10HU.

Disappointingly, all other estimates of test performance are based on small numbers of studies with very few patients and accompanying wide 95% confidence intervals, indicating much uncertainty in test performance for all other imaging markers. For true adrenal incidentalomas, two of three MRI studies reported slightly lower sensitivity and specificity than CT for measures of adrenal–liver and adrenal–spleen ratios and loss of signal intensity. The performance of

PET for adrenal–liver ratio and SUVmax measures in the two included studies was not clearly better than CT. In patients with a history of extra-adrenal malignancy, only one study reported on CT contrast-enhanced washout tests, which showed very low sensitivity (16%). Four of the five studies of MRI used 1.5Tesla machines and reported high sensitivity (89–99%) for measures of adrenal–liver, adrenal–spleen, adrenal–muscle ratios and loss of signal intensity. Specificity varied (60–93%) but was high for most MRI measures. The performance of PET was similar to MRI for adrenal–liver ratio and max SUV measures. Although more studies had evaluated CT, MRI and PET in the pathway for follow-up of known extra-adrenal malignancy than for incidentally discovered adrenal lesions, estimates of test performance are still based on too small numbers of studies to be able to discern whether any test performs adequately or better than alternative tests from the available data.

#### 4.1.2. Value of an adrenal biopsy (Question 1b)

The following paragraph represents a summary of a recent systematic review carried out with involvement of some of the guideline panel members on published experience with adrenal biopsy and its outcomes (78). Inclusion criteria and definition of reference standard differed from the imaging meta-analysis mainly in population selection criteria (as adrenal biopsy is not indicated in incidentaloma population but rather in patients at high risk for malignancy) and in reference standard (where we accepted imaging and clinical follow-up in addition to histopathology, as most metastases would not undergo adrenalectomy). We identified 32 studies (90, 113, 114, 115, 116, 117, 118, 119, 120, 121, 122, 123, 124, 125, 126, 127, 128, 129, 130, 131, 132, 133, 134, 135, 136, 137, 138, 139, 140) with a total of 2174 patients which reported at least one outcome of interest (complication rate, nondiagnostic rate, diagnostic accuracy parameters). Of these, only 8 studies (90, 126, 127, 130, 131, 132, 133, 140) were included for the diagnostic accuracy analysis, reasons for exclusion being lack of any or optimal reference standard for at least 50% patients ( $n=20$ ) and more than 30% patients with nonadenomas in benign cohort ( $n=4$ ). Included studies were assessed to be at a moderate risk for bias, most limitations relating to patient selection, assessment of outcome and adequacy of follow-up of the study population.

Studies had diverse population inclusion criteria, reference standards and biopsy techniques. Pathology of

adrenal lesion was reported only for 1621/2190 cases. Out of these, 828 were malignant (689 metastases, 68 ACCs, 71 other malignancies or not specified), 718 were benign and 75 were various other nonmalignant lesions (36 pheochromocytomas, 29 granulomas, 10 other). Pooled nondiagnostic rate derived from 30 studies (2030 adrenal biopsy procedures) was 8.7% (CI: 6.2–11.2%;  $I^2=84%$ ,  $P<0.001$ ). Pooled overall complication rate derived from 25 studies (1339 biopsies) was 2.5% (CI 1.5–3.4%;  $I^2=19%$ ,  $P=0.195$ ), though likely under-represented due to differences in both assessment and reporting of complication as well as retrospective nature of the studies. The diagnostic performance of adrenal biopsy was calculated using the data from the 8 studies (240 adrenal biopsy procedures) meeting pre-established eligibility criteria. Performance of adrenal biopsy in the diagnosis of malignancy overall was: sensitivity 87% (CI: 95% of 78–93%), specificity 100% (CI: 95% of 76–100%), positive likelihood ratio of 229 (CI: 95% of 2.9–18145) and negative likelihood ratio of 0.13 (CI: 95% of 0.07–0.23). Performance was lower (and with even wide 95% CIs) for ACC: sensitivity 70% (CI: 95% of 42–88%), specificity 98% (CI: 95% of 86–100%), positive likelihood ratio of 100.43 (CI: 95% of 8–1245) and negative likelihood ratio of 30.9 (CI: 95% of 4.16–229).

## 4.2. Assessment of autonomous cortisol secretion in adrenal incidentalomas

### 4.2.1. Assessment of autonomous cortisol secretion in relation to clinical outcomes (Question 2a, Appendices I and II)

Studies were eligible for inclusion independent of the criteria used to define autonomous cortisol secretion. Three different hormonal profiles were distinguished to describe autonomous cortisol secretion associated with adrenal adenomas; Profile 1: serum cortisol  $>50$  nmol/L ( $>1.8$   $\mu\text{g/dL}$ ) after 1, 2 or 8 mg overnight dexamethasone suppression tests, or 2-day low-dose dexamethasone test, and one of the following additional endocrine alterations: increased 24-h urinary-free cortisol (UFC), low plasma ACTH, elevated midnight serum or salivary cortisol. Profile 2: serum cortisol  $>83$  nmol/L ( $>3.0$   $\mu\text{g/dL}$ ) after 1 mg overnight dexamethasone test and one additional endocrine alteration (same as above). Profile 3: cortisol  $>138$  nmol/L ( $>5$   $\mu\text{g/dL}$ ) after 1 mg overnight dexamethasone test as sole criterion. The defined profiles do not fit completely with the specific

criteria used in all of the studies included. Virtually, all diagnostic algorithms are, however, variations of these profiles.

In total, 12 studies were included: 7 cross-sectional studies (38, 42, 43, 45, 141, 142, 143) and 5 cohort studies (40, 46, 144, 145, 146). In eight studies, a comparison was made between patients with elevated (group 1) or normal (group 2) cortisol levels after a 1 mg dexamethasone test. Two studies used the biochemical profile 1 and four studies used the biochemical profile 2 with a variation since the post-dexamethasone serum cortisol cut-off was not a mandatory criterion. Three studies identified three subgroups of patients (38, 144, 145), normal, intermediate and frankly altered cortisol suppression corresponding to cortisol levels after 1 mg dexamethasone of  $<50$  nmol/L ( $<1.8$   $\mu\text{g/dL}$ ), between 50 and 138 nmol/L (1.8–5.0  $\mu\text{g/dL}$ ) and  $>138$  nmol/L ( $>5.0$   $\mu\text{g/dL}$ ) respectively.

In the cross-sectional studies, the risk of bias is estimated as high, given the inability to assess causality and the potential for residual confounding factors, and these issues hamper the ability to make firm conclusions from these studies. Differences in diagnostic protocols, definitions of outcome and duration of follow-up were associated with considerable heterogeneity between studies.

## Outcome measures

### Change in biochemical profile

In three studies with a median follow-up of 3, 6.9 and 7.5 years, no patient progressed to overt Cushing's syndrome during follow-up (40, 145, 146).

### Change in metabolic and cardiovascular profile

The risk of type 2 diabetes was higher in patients with impaired cortisol suppression after 1 mg dexamethasone test and increased further during follow-up (38, 145, 146). Also, the risk of hypertension was higher in patients with impaired cortisol suppression and increased further with follow-up (38, 142, 146, 147). A smaller study did not confirm the increase in diabetes and hypertension with time (40).

### Major cardiovascular incidents

In two cohort studies (145, 146), the incidence of cardiovascular events was higher in patients with altered cortisol suppression.

### Mortality

Two studies reported on mortality (144, 145) and found an increased mortality risk in patients with higher cortisol levels after 1 mg dexamethasone. However, the results were adjusted for other prognostic factors only in the first study, and effect estimates were uncertain due to low number of events.

### Risk of vertebral fractures

Four studies reported a higher prevalence of vertebral fractures (38, 42, 43, 45) in patients with impaired cortisol suppression. In a cohort study (46), the incidence of new vertebral fractures was higher in patients with impaired cortisol suppression. However, most of the detected vertebral fractures were minor and of uncertain clinical impact.

#### 4.2.2. Surgery vs conservative management in patients with autonomous cortisol secretion (Question 2b, Appendices III and IV)

For question 2b, four studies were included in which surgery was compared with a conservative approach: one randomized controlled trial and three observational studies. The randomized trial (148) reported on patients with autonomous cortisol secretion who underwent surgery ( $n=23$ ) or were treated by a conservative approach ( $n=22$ ). The mean follow-up was 7.7 years and the results were only a qualitative description of changes in hypertension, diabetes mellitus or dyslipidemia.

Tsuiki *et al.* included patients with autonomous cortisol secretion and compared a group treated by surgery ( $n=10$ ) and a group treated conservatively ( $n=10$ ) (149). Follow-up was 7–19 months. The second cohort study included 41 patients with autonomous cortisol secretion (25 treated by surgery and 16 conservatively treated) (44). Outcome measures included: proportion of patients with steady, improved or worsened blood pressure, fasting glucose or LDL cholesterol. In the third study by Iacobone *et al.*, 372 patients with autonomous cortisol secretion (20 treated by surgery and 15 conservatively treated) (150). Outcomes were blood pressure, glucose and cholesterol.

The quality of evidence from these studies is low to very low, mainly due to confounding factors. Only one study was randomized, and none of the studies reported blinded outcome assessment. Most studies were also downgraded for imprecision, due to low number of events. Differences in diagnostic protocols, definitions of

outcome and duration of follow-up were associated with considerable heterogeneity between and within studies.

### Outcome measures

#### *Change in metabolic and cardiovascular profile in patients with autonomous cortisol secretion*

In the randomized trial, 25% of patients with type 2 diabetes mellitus had normalized glycemic control after surgery (148), compared with none in the conservative group. The cohort studies (44, 149, 150) reported an improvement in glucose levels in 10–48% of patients after surgery. In the conservatively treated groups, none of the patients improved.

The cohort studies (44, 149, 150) reported an improvement in hypertension and dyslipidemia in some patients after surgery. In the conservatively managed group, none of the patients improved.

#### *Risk of vertebral fractures*

None of the included studies reported on the risk of vertebral fractures.

#### *Major cardiovascular incidents and mortality*

None of the included studies reported on the risk of major cardiovascular events or mortality.

### 4.3. Surgical approach: open vs minimally invasive adrenalectomy (Question 3, Appendices V and VI)

As adrenocortical carcinoma is the main threat for an adverse outcome in patients with adrenal incidentaloma undergoing surgery, we focused our efforts with regard to surgery on the management of adrenocortical carcinoma. Nine cohort studies on the surgical treatment of patients with nonmetastatic adrenocortical carcinoma were included (151, 152, 153, 154, 155, 156, 157, 158, 159). Three studies reported on the patients in whom complete resection of the tumor was achieved (153, 155, 159).

The quality of evidence from these observational studies is very low, mainly because patient groups were not comparable at baseline with regard to important prognostic characteristics, such as tumor stage or size. Tumor stage was, on average, lower in patients with laparoscopic surgery as compared with open surgery. In few studies (151, 158), treatment effects were adjusted for differences in tumor stage. Mostly, however, only

uncorrected estimates of recurrence-free and overall survival were reported. Moreover, most studies had imprecise effect estimates.

### Outcome measures

#### *Perioperative mortality and morbidity*

One study reported on perioperative mortality (151). In this study, none of the 152 patients died perioperatively. Three studies reported on intraoperative or postoperative complications (154, 155, 158). Major postoperative complications (Clavien-classification score 3–5) occurred more often in open surgeries compared with laparoscopic surgeries (RR 1.7, 95% CI: 0.5–6.2), but these estimates are imprecise due to low numbers of events.

#### *Completeness of resection*

In five studies, the completeness of resection was reported (151, 152, 154, 156, 158). The pooled estimate of these five studies indicated no clear difference in complete resection between surgical approaches (RR 0.8 (95% CI: 0.6–1.1)). The results of these studies were inconsistent, leading to much uncertainty regarding this conclusion.

#### *Recurrence-free and overall survival*

Eight studies reported on recurrence after surgery, but differed in the presentation of these data. These studies also provided data on overall or disease-specific survival (151, 152, 153, 154, 155, 157, 158, 159). There is no compelling evidence that one of the approaches (laparoscopic or open adrenalectomy) is superior with regard to time to recurrence and/or survival in patients with adrenocortical carcinoma, provided that rupture of tumor capsule is excluded. However, the studies have significant limitations, inconsistencies and imprecision precluding reliance on this conclusion.

#### *Pain/patient satisfaction*

None of the studies reported on pain or patient satisfaction.

### 4.4. Natural course of apparently benign adrenal incidentaloma (risk of malignancy or development of hormone excess) (Question 4, Appendices VII and VIII)

A systematic review of 14 studies assessing the natural course of 1410 patients with apparently benign, nonfunctioning adrenal incidentalomas (3) and 10

additional cohort studies were included (21, 40, 44, 46, 146, 147, 160, 161, 162, 163, 164, 165, 166, 167). The systematic review included studies reporting the follow-up of adrenal incidentaloma patients, published between 1980 and 2008, including publications that reported more than 20 patients, and in which the majority were referred to an endocrinologist (excluding oncology series). The additional 10 studies, published between 2005 and 2014, included 1131 incidentaloma patients with apparently benign nonfunctioning tumors or with autonomous cortisol secretion.

The quality of evidence from these studies was judged moderate or low. Selection criteria were often not reported, the duration of follow-up was heterogeneous across studies (medians ranging from 19 to 90 months) and the completeness of follow-up was difficult to assess. Information on the protocol of biochemical or radiological re-evaluation was not always provided and standardized. In addition, criteria for hormonal excess were heterogeneous across studies.

### Outcome measures

#### *Malignancy*

The estimated pooled risk for developing malignancy in the systematic review was 0.2% (95% CI: 0.0–0.4) (3). In two cohort studies, one case of malignancy was found: one patient with adrenal non-Hodgkin lymphoma and one patient with renal cancer metastasis. In the first case, the imaging characteristics of the adrenal incidentaloma at the first evaluation were not consistent with benign characteristics and the lymphoma may have been misdiagnosed initially (22). The second case had a history of renal cell carcinoma, and it is unclear whether the adrenal mass was found incidentally or during the follow-up for cancer (168). No case of malignancy was reported in the other 904 patients included in the cohort studies. Importantly, no malignant transformation of a presumably benign incidentaloma was reported.

#### *Development of clinically overt hormone excess*

The risk of developing 'autonomous cortisol secretion' without signs of overt Cushing's syndrome may occur in 0–11% of patients with nonfunctioning adrenal incidentalomas. The risk of clinically overt Cushing's syndrome however is very low, with a pooled estimate from a systematic review of 0.3% (3). The risk of developing an aldosterone-producing adenoma in the

individual studies ranged from 0 to 2%. The risk of developing a pheochromocytoma ranged from 0 to 2%, but it is unclear whether an accurate initial imaging and biochemical screening was performed.

## 5. Recommendations, rationale for the recommendations

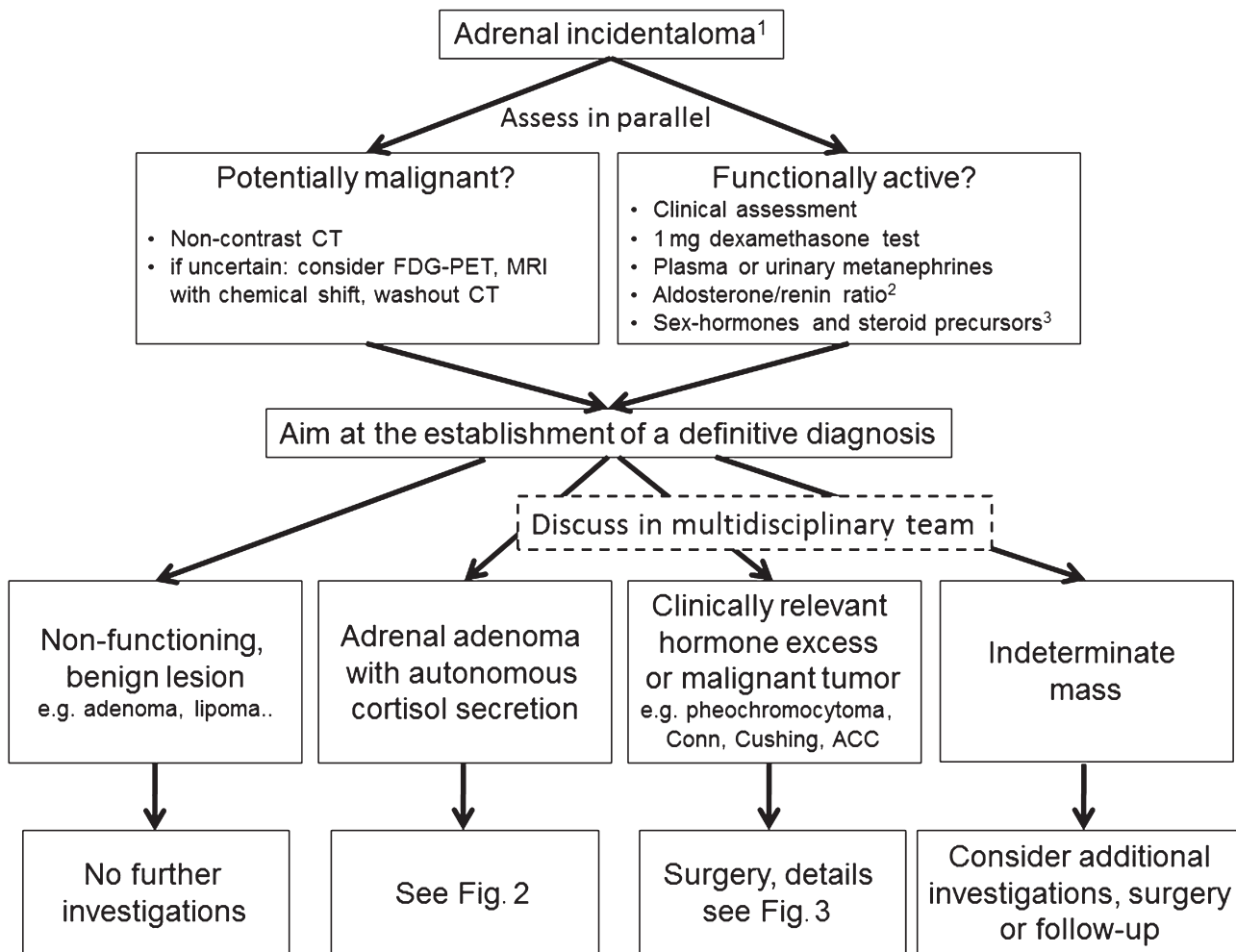
### 5.1. General remarks

The main part of this guideline addresses the management of patients who fulfill the definition of adrenal incidentaloma (Section 2.1) (Fig. 1). In addition, we discuss specific situations separately: bilateral adrenal

masses (5.6.1), patients who are young or elderly and frail (5.6.2) and adrenal masses detected during evaluation for extra-adrenal malignancy (5.6.3).

**R 1.1. We recommend that patients with adrenal incidentalomas are discussed in a multidisciplinary expert team meeting, if at least one of the following criteria is met:**

- Imaging is not consistent with a benign lesion.
- There is evidence of hormone excess (including ‘autonomous cortisol secretion’).
- Evidence of significant tumor growth during follow-up imaging.
- Adrenal surgery is considered.



<sup>1</sup>For patients with history of extra-adrenal malignancy, see special section 5.6.4.

<sup>2</sup>Only in patients with concomitant hypertension and/or hypokalemia.

<sup>3</sup>Only in patients with clinical or imaging features suggestive of adrenocortical carcinoma.

**Figure 1**

Flowchart on the management of patients with adrenal incidentalomas (overview).

Reasoning:

Although we believe that the ideal would be for all patients with adrenal incidentalomas to be managed by an expert multidisciplinary team, in many health care settings, this is an unrealistic aspiration. Despite lack of compelling evidence, we aimed at identifying subgroups of patients that would be most likely to benefit from multidisciplinary team discussion, and that these discussions occur quickly for patients that meet the criteria above. The core multidisciplinary team should consist of at least a radiologist, an endocrinologist and a surgeon, all with significant experience in adrenal tumors. Furthermore, this team should have access to anesthetists and an endocrine pathologist, who are experienced in adrenal tumors. Although it is beyond the scope of this guideline, the use of a standardized pathology report is highly recommended.

There is sufficient evidence that higher surgical volume correlates with better outcome; however, for the time being, no specific numbers of operations per year that result in this favorable outcome can be recommended (152, 169, 170, 171).

## 5.2. Assessment of the risk of malignancy

### **R 2.1. We recommend aiming to establish if an adrenal mass is benign or malignant at the time of initial detection.**

Reasoning:

It is critical to know if an adrenal mass is malignant or benign as clinical management is dependent on establishing this fact, regardless of whether the mass is functioning or not. Malignant lesions may need urgent surgical intervention and other therapies, and delay may cause harm.

**R 2.2. We recommend that all adrenal incidentalomas undergo an imaging procedure to determine if the mass is homogeneous and lipid-rich and therefore benign (⊕000). For this purpose, we primarily recommend the use of noncontrast CT (⊕000).**

**R 2.3. We suggest that if the noncontrast CT is consistent with a benign adrenal mass (Hounsfield units  $\leq 10$ ) that is homogeneous and smaller than 4 cm, no further imaging is required (⊕000).**

Reasoning:

In patients with no known extra-adrenal malignancy adrenal incidentalomas are likely to be benign. The noncontrast CT value is reflective of tissue density. Benign lesions including lipid-rich adenoma, myelolipoma,

fluid-filled homogenous cysts and other soft tissue tumors (ganglioneuromas, some schwannomas) have low CT density  $\leq 10$  HU. Based on the systematic review and meta-analysis (77), in patients presenting without known malignancy, a noncontrast CT with HU of  $\leq 10$  was only found in those with benign disease, whereas in patients with extra-adrenal malignancy, 7% of cases with noncontrast HU  $\leq 10$  turned out to be malignant.

Similar to CT, the results of MRI with chemical shift imaging are based on the lipid content of masses (172, 173). Unlike CT (or FDG-PET), MRI has the advantage of avoiding ionizing radiation and its attendant risks to the patient. However, the quantitative assessment of loss in signal intensity is not well standardized between the different studies and, therefore, evidence base for performance of MRI in the diagnosis of malignancy is insufficient to make strong recommendations. Moreover, the interpretation of the images might be more dependent on the experience of the radiologist than for CT assessment. In addition, the meta-analysis was not able to determine the diagnostic value of MRI due to the low number and quality of eligible studies.

In conclusion, the panel felt – despite the limited evidence – confident about the negative predictive value of noncontrast CT to recommend that additional imaging was not necessary when benign characteristics were found in an adrenal mass  $< 4$  cm, especially as additional imaging may also risk false-positive results and significant psychological and financial burden for patients and the health system respectively. We acknowledge that the cut-off of 4 cm is not based on good evidence from clinical studies, but the panel felt it is necessary to provide clear guidance based on clinical experience.

MRI with chemical shift has an even poorer evidence base with regard to its diagnostic value in excluding malignancy and, therefore, should be the first choice only where a CT is less desirable (e.g. pregnancy, children). However, if an MRI with chemical shift is already performed and the results are unambiguous, a multidisciplinary expert team might judge this as sufficient for an individual patient.

**R 2.4. If the adrenal mass is indeterminate on noncontrast CT and the results of the hormonal work-up do not indicate significant hormone excess, there are three options that should be considered by a multidisciplinary team acknowledging the patient's clinical**

**Table 4** Imaging criteria suggesting a benign adrenal mass<sup>a</sup>.

Method	Criteria
Noncontrast CT	≤10HU
MRI – chemical shift <sup>b</sup>	Loss of signal intensity on out-phase imaging consistent with lipid-rich adenoma
CT with delayed contrast media washout <sup>b,c</sup>	Absolute washout >60% Relative washout >40%
18F-FDG-PET <sup>b</sup>	Absence of FDG uptake or uptake less than the liver <sup>d</sup>

<sup>a</sup>These criteria apply only for masses with homogenous appearance or masses that have other clear characteristics consistent with benign disease, e.g. myelolipoma. A homogeneous mass is defined as a lesion with uniform density or signal intensity throughout. The measurements/region of interest (ROI) should include at least 75% of a lesion without contamination by tissues outside the adrenal lesion. Inhomogeneous lesions should not be subjected to MRI or washout CT for further characterization. <sup>b</sup>Evidence is weak for MRI, CT with contrast washout and FDG-PET and no comparative studies on “second line imaging” are available. Thus, in this guideline, we clearly recommend noncontrast CT as imaging procedure of choice. <sup>c</sup>There is no clear evidence about the best time interval for delayed contrast media washout. We recommend 10 or 15 min. <sup>d</sup>Certain malignant lesions (e.g. metastasis from kidney cancer or low-grade lymphoma) may be FDG negative.

**context: immediate additional imaging with another modality, interval imaging in 6–12 months (noncontrast CT or MRI) or surgery without further delay.**

#### Reasoning:

Evidence of targeted evaluation for ‘second or third-line’ imaging in patients with indeterminate adrenal mass is very poor (see Section 4.1 and (77) for details). However, the panel considered it important to provide some guidance for daily clinical practice (Table 4), although consensus was not reached other than agreeing that such discussions needed to be individualized and should take place within a multidisciplinary team meeting.

The advantages and limitations of MRI with chemical shift are already discussed at **R 2.3**.

Contrast washout CT has very limited and low-quality evidence from studies (77). CT washout is widely available, but there is huge variability in the protocols applied and, therefore, poor comparability between studies and centers; in addition, the meta-analysis could only identify a single eligible study reporting CT washout study results, carried out in patients without a history of extra-adrenal malignancy.

FDG-PET/CT has the advantage that the risk of false-negative results (namely missing a malignant adrenal tumor) is quite low, and this refers mainly to a few subtypes

of extra-adrenal malignancies with low uptake (174, 175, 176, 177). This procedure is, however, more expensive, not always easily available, and has the disadvantage that several benign adrenal tumors (e.g. functional adenomas or benign pheochromocytoma) may be FDG-positive (178, 179).

While the panel was in favor of attempts to fully characterize the adrenal mass on imaging, due to the limitations summarized above, it considered that in patients with indeterminate results on noncontrast CT, further imaging by one of the modalities detailed above should be arranged. Due to the lack of evidence and studies reporting direct comparison, the panel was not able to clearly judge one method over another. Alternatively, in patients without a strong suspicion of malignancy and older patients, follow-up imaging 6–12 months after the initial scan could be undertaken. The rationale for a follow-up scan at 6–12 months is based on the principle that either primary adrenal malignancies or adrenal metastases are likely to increase in size over this time period; lack of growth may be taken as an indicator of benign disease in radiologically indeterminate lesions. The exact timing of this imaging should be individualized. However, especially in cases with a low likelihood of a malignant tumor, the panel favors a time interval of 12 months. There are no published size or volume cut-offs commonly agreed or with evidence base to support that they indicate growth suggestive of malignancy; the expert panel agreed that an increase in >20% of the largest tumor diameter together with an at least 5 mm increase in this diameter should be considered as suspicious.

**R 2.5. We recommend against the use of an adrenal biopsy in the diagnostic work-up of patients with adrenal masses unless there is a history of extra-adrenal malignancy (see R 6.3.5.).**

#### Reasoning:

Adrenal biopsy has a limited role in evaluation of adrenal masses – mainly in diagnosis of extra/adrenal malignancy, lymphoma, infiltrative or infectious process. Even in such situations, adrenal biopsy should only be performed by an experienced radiologist and when it is required to guide further care. We particularly recommend against an adrenal biopsy if an adrenal mass is likely to be an adrenocortical carcinoma, because a biopsy of such a tumor runs the risk of tumor dissemination precluding an R0 resection (although this risk seems to be low (180)). The only exception might be if a formal confirmation of



the diagnosis is needed in an inoperable tumor to inform oncological management or as part of a clinical trial.

### 5.3. Assessment for hormone excess

**R 3.1. We recommend that every patient with an adrenal incidentaloma should undergo careful assessment including clinical examination for symptoms and signs of adrenal hormone excess.**

Reasoning:

All patients should undergo a careful evaluation with detailed history and physical examination since a second round evaluation may detect clues of overt hormone excess that were overlooked initially. For the clinical assessment and subsequent diagnostic procedures for Cushing's syndrome, primary aldosteronism and pheochromocytoma, we refer to guidelines of other societies (71, 72, 181).

Rapidly developing hirsutism or virilization is a clinical indicator for an androgen-producing tumor, and should be addressed by measuring testosterone and androgen precursors, whereas recent onset of gynecomastia should trigger measurement of estradiol (182, 183, 184, 185) (see also R 3.10.).

**R 3.2. We recommend that all patients with adrenal incidentalomas undergo a 1 mg overnight dexamethasone suppression test to exclude cortisol excess (⊕⊕OO).**

**R 3.3. We suggest interpretation of the results of the 1 mg overnight dexamethasone test as a continuous rather than categorical (yes/no) variable (⊕OOO). However, we recommend using serum cortisol levels post dexamethasone  $\leq 50$  nmol/L ( $\leq 1.8$   $\mu$ g/dL) as a diagnostic criterion for the exclusion of autonomous cortisol secretion (⊕⊕OO).**

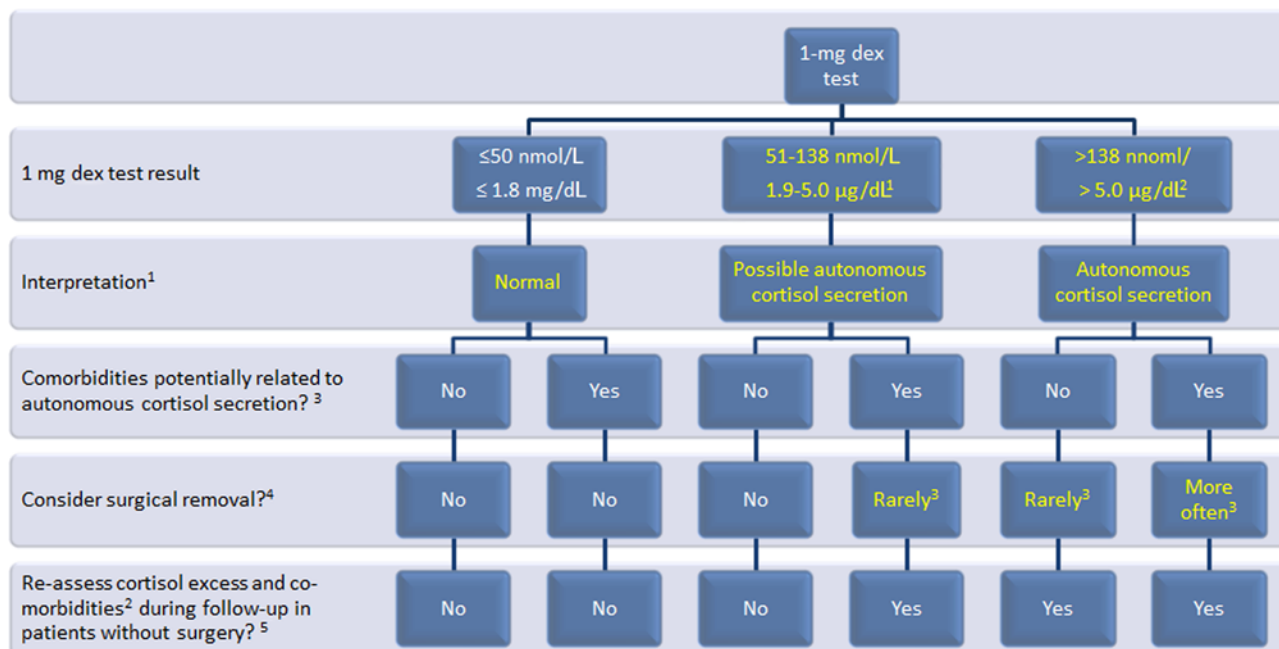
**R 3.4. We suggest that post-dexamethasone serum cortisol levels between 51 and 138 nmol/L (1.9–5.0  $\mu$ g/dL) should be considered as evidence of 'possible autonomous cortisol secretion' and cortisol levels post dexamethasone  $> 138$  nmol/L ( $> 5.0$   $\mu$ g/dL) should be taken as evidence of 'autonomous cortisol secretion'. Additional biochemical tests to confirm cortisol secretory autonomy and assess the degree of cortisol secretion might be required (Fig. 2). However, for the clinical management, the presence of potentially cortisol-related comorbidities (Table 2, Fig. 2) and age of the patient are of major importance.**

Reasoning:

A variety of diagnostic algorithms have been used to exclude cortisol excess or to define the so-called 'subclinical hypercortisolism', but in the literature, there are no head-to-head comparisons between tests to assess their diagnostic performance (see Section 4.2.1). However, the panel recommends the use of the 1 mg overnight dexamethasone test based on pathophysiological reasoning, simplicity and the fact that the test was incorporated in the diagnostic algorithms of most studies. It is important to consider drugs or conditions that interfere with this test (Appendix Table A IX). In published guidelines and reviews, variable thresholds have been recommended (5, 8, 9, 10). Several studies have used post-dexamethasone serum cortisol values between 50 and 138 nmol/L (1.8–5.0  $\mu$ g/dL) and/or required further tests to secure the diagnosis of 'autonomous cortisol secretion'. However, in none of these additional tests was the performance convincing enough to ultimately establish the diagnostic criteria.

The panel appreciated that this ongoing debate reflects a biological continuum with no clear separation between nonfunctioning adenomas and functioning adenomas associated with some degree of cortisol excess. However, a value of  $\leq 50$  nmol/L ( $\leq 1.8$   $\mu$ g/dL) may be regarded as normal, excluding cortisol excess. This cut-off is supported by studies demonstrating that patients with post-dexamethasone cortisol values  $> 50$  nmol/L ( $> 1.8$   $\mu$ g/dL) have an increased morbidity or mortality (144, 145). Since the probability of clinically relevant cortisol excess increases the higher the post-dexamethasone serum cortisol value and that the principle of dexamethasone testing is based on pharmacological suppression of ACTH secretion, we propose that the following terminology be used on biochemical grounds. For patients without overt Cushing's syndrome and a serum cortisol post dexamethasone between 51 and 138 nmol/L, we propose the term 'possible autonomous cortisol secretion', and for higher values, the term 'autonomous cortisol secretion'. However, for the clinical management, the presence of potentially related comorbidities (Table 2, Fig. 2) and age of the patient are of major relevance.

The majority of panel members (but not all) preferred additional biochemical tests to confirm cortisol secretory autonomy and assess the degree of cortisol secretion. However, we acknowledge that use of several tests may be associated with an increased likelihood of at least one being a false-positive result. Nevertheless, we suggest measurement of basal morning plasma ACTH and to



<sup>1</sup>The majority of, but not all, panel members preferred additional biochemical tests to better judge the degree of cortisol secretion. In patients with comorbidities, we suggest to measure plasma ACTH and to repeat the dexamethasone test in 3–12 months.

<sup>2</sup>We suggest additional biochemical tests to better judge the degree of cortisol secretion: plasma ACTH, 24-h urinary-free cortisol, (and/or late-night salivary cortisol) and repetition of the dexamethasone test in 3–12 months.

<sup>3</sup>See Table 2 for potentially cortisol-related comorbidities.

<sup>4</sup>Choice for surgery should always be individualized.

<sup>5</sup>Need of follow-up by an endocrinologist for 2–4 years.

**Figure 2**

Assessment and management of ‘autonomous cortisol secretion’ in patients with adrenal incidentalomas.

repeat the dexamethasone test after 3–12 months in all patients with ‘possible autonomous cortisol secretion’ and comorbidities. In patients with ‘autonomous cortisol secretion’, we suggest the additional measurement of 24-h urinary-free cortisol and/or late-night salivary cortisol (although few studies suggest a poor performance of this parameter in patients with incidentaloma). Following the concept that cortisol secretion in patients with ‘autonomous cortisol secretion’ is independent of ACTH, a higher dose of dexamethasone (e.g. 3 mg, 2 × 2 mg or 8 mg) might also be reasonable as additional test. However, the published literature is too limited and controversial to make a clear statement on these tests.

**R 3.5. We recommend against considering ‘autonomous cortisol secretion’ as a condition with a high risk for the development of overt Cushing’s syndrome (⊕⊕OO).**

Reasoning:

Studies reporting on follow-up of patients with adrenal incidentalomas have uniformly found a very low

percentage (<1%) of patients with ‘autonomous cortisol secretion’ progressing to overt Cushing’s syndrome (1, 2, 3, 20, 21, 22, 23, 24, 25).

**R 3.6. We recommend screening patients with ‘possible autonomous cortisol secretion’ or ‘autonomous cortisol secretion’ for hypertension and type 2 diabetes mellitus (⊕OOO) and suggest offering appropriate treatment of these conditions.**

Reasoning:

Studies from different research groups have consistently demonstrated an association between cortisol excess and hypertension and hyperglycemia (23, 31, 32, 33, 34, 35, 36, 37, 38, 39). The association with dyslipidemia is less proven, although biologically plausible. There is also evidence that patients with cortisol excess are at increased risk of cardiovascular events and excess mortality (144, 145).

Therefore, the panel recommended screening for these conditions, which are well-known independent

cardiovascular risk factors and which may be driven by cortisol excess, and to treat them according to current guidelines.

**R 3.7. We suggest screening patients with ‘autonomous cortisol secretion’ for asymptomatic vertebral fractures (⊕000) and to consider appropriate treatment of these conditions (⊕000).**

Reasoning:

Several studies, although mainly from a single research group, have demonstrated an association between autonomous cortisol secretion and an increased risk of vertebral fractures (41, 42, 43, 44, 45, 46). Although most of the fractures are asymptomatic, the panel suggests screening patients with ‘autonomous cortisol secretion’ for vertebral fractures at least once at the time of diagnosis. This may be done by re-evaluating the available images (if a CT was performed) or by plain X-ray. The panel did not reach consensus on recommending assessment of bone mineral density by dual-energy x-ray absorptiometry (DXA). If osteoporosis is present, active treatment should be considered. If there is no other likely explanation for the osteoporosis, removal of the adrenal adenoma might be considered (see R 3.8.).

**R 3.8. We suggest an individualized approach in patients with ‘autonomous cortisol secretion’ due to a benign adrenal adenoma and comorbidities potentially related to cortisol excess for adrenal surgery (⊕000). Age, degree of cortisol excess, general health, comorbidities and patient’s preference should be taken into account. In all patients considered for surgery, ACTH-independency of cortisol excess should be confirmed.**

Reasoning:

Due to the limitations of current literature, especially the lack of high-quality randomized trials, the panel could not reach consensus on the exact indication for surgery for ‘autonomous cortisol secretion’. The panel appreciated that there is some evidence of improvement of hypertension, hyperglycemia and dyslipidemia with surgery, but this is based on low-quality data. However, no data are available on clinically relevant endpoints (e.g. mortality or major cardiovascular events). Thus, the decision to undertake surgery should be individualized taking into account

factors that are linked to surgical outcome, such as patient’s age, duration and evolution of comorbidities and their degree of control, and presence and extent of end organ damage. Because it is not possible to be sure that surgical intervention will normalize or improve the clinical phenotype of an individual patient, there was no complete agreement within the panel with regard to the optimal management of these patients. Approaches varied between two ends of the spectrum. Overall, the group agreed that there is an indication of surgery in a patient with post-dexamethasone cortisol >138 nmol/L (>5 µg/dL) and the presence of at least two comorbidities potentially related to cortisol excess (e.g. type 2 diabetes, hypertension, obesity, osteoporosis), of which at least one is poorly controlled by medical measures. Conversely, there is no reason for surgery, when serum cortisol post dexamethasone is <138 nmol/L (<5 µg/dL) and no comorbidities are present. However, some panel members favor a more proactive approach, for example, considering surgical intervention, especially in younger patients with ‘possible autonomous cortisol’ secretion and less comorbidities potentially related to cortisol excess, even if controlled by medical therapy.

However, there was consensus that when surgery is considered due to ‘autonomous cortisol secretion’, ACTH-independency has to be proven by a suppressed or low basal morning plasma ACTH. If not, other reasons of cortisol excess have to be considered.

**R 3.9. We recommend excluding pheochromocytoma by measurement of plasma-free metanephrines or urinary fractionated metanephrines.**

Reasoning:

For details, we refer to the most recent guidelines of other societies (e.g. (72)). Of note, there are clinically silent pheochromocytomas (186, 187, 188) that might lead to hemodynamic instability during surgical excision (189). Thus, metanephrines should be measured in normotensive patients, and the diagnosis of pheochromocytoma should be considered in patients with borderline values of metanephrines and indeterminate imaging features on CT.

In adrenal lesions with imaging criteria of an adenoma, the likelihood of a pheochromocytoma is extremely low (190, 191). Thus, it seems to be reasonable to avoid measuring metanephrines in patients with clear evidence of an adrenal adenoma, but definitive data in this area are lacking.

**R 3.10. In patients with concomitant hypertension or unexplained hypokalemia, we recommend the use of the aldosterone/renin ratio to exclude primary aldosteronism.**

Reasoning:

For details, we refer to the most recent guidelines of other societies (e.g. (181)).

**R 3.11. We suggest measurement of sex hormones and steroid precursors in patients with imaging or clinical features suggestive of adrenocortical carcinoma.**

Reasoning:

Adrenocortical carcinoma is associated in more than half of cases with elevated sex hormones and steroid precursors (184, 185, 192, 193, 194). The panel does not recommend measurement of these hormones in patients with adrenal incidentalomas on a routine basis, but in cases with indeterminate adrenal mass by imaging or clinical signs for androgen excess, significantly increased sex hormones or precursors might clearly point toward adrenocortical carcinoma. Thus, measurement of serum DHEA-S, androstenedione, 17-hydroxyprogesterone as well as testosterone in women and estradiol in men and postmenopausal women can prove the adrenocortical nature of the adrenal mass. However, the panel acknowledges that the published evidence for this suggestion is very low (184, 193). A very promising new tool to discriminate benign from malignant adrenocortical tumors appears the analysis of a comprehensive urinary steroid profile measured by GC-MS or LC-MS (194, 195).

#### 5.4. Surgical treatment (Fig. 3)

**R 4.1. We recommend adrenalectomy as the standard of care for unilateral adrenal tumors with clinically significant hormone excess.**

Reasoning:

As covered by several other guidelines, there is consensus that adrenal tumors leading to clinically significant hormone excess (e.g. primary aldosteronism, Cushing syndrome or pheochromocytoma) should be surgically removed (30, 72, 181). The guideline group is convinced that for these tumors, the same rules regarding the surgical approach should apply as for endocrine-inactive tumors (see below). There are no substantiated reasons why the surgical approach for

hormone-producing tumors should differ from that in endocrine-inactive tumors (R 4.3.–R 4.5.).

**R 4.2. We recommend against performing surgery in patients with an asymptomatic, nonfunctioning unilateral adrenal mass and obvious benign features on imaging studies (⊕000).**

Reasoning:

Most adrenal incidentalomas are nonfunctioning benign lesions (e.g. adenomas, myelolipomas) that do not cause harm. Therefore, there is broad consensus that the majority of these adrenal masses do not require surgery. The guideline group defined two criteria that need to be fulfilled to allow characterization of a unilateral adrenal lesion as not harmful: (i) imaging criteria indicating a benign lesion (see Section 5.2, Table 4); (ii) no relevant endocrine activity (see Section 5.3).

There was considerable discussion by the group if a certain cut-off of size should be a factor to consider surgery. There was consensus that a tumor with a diameter of  $\leq 4$  cm with benign imaging features does not require surgery, accepting that this size cut-off is arbitrary. However, due to the paucity of follow-up data on the natural history of large apparently benign adrenal incidentalomas, the panel was divided on the approach to the management of patients with larger lesions. One approach is to rely on imaging criteria only to determine if a lesion is benign irrespective of size. Alternatively, because of clinician or patient uncertainty about the increasing incidence of malignancy the larger the mass, surgery may be considered in larger lesions (e.g.  $>4$  cm) even if imaging characteristics suggest a benign nature of the mass, allowing for an individualized approach. We voted against a certain cut-off, which indicates that surgery has to be performed. However, we acknowledge that with a larger tumor size, patients and clinicians might feel increasingly uncomfortable, but again an individualized approach was deemed most appropriate.

**R 4.3. We suggest performing laparoscopic adrenalectomy in patients with unilateral adrenal masses with radiological findings suspicious of malignancy and a diameter  $\leq 6$  cm, but without evidence of local invasion (⊕000).**

**R 4.4. We recommend performing open adrenalectomy for unilateral adrenal masses with radiological findings suspicious of malignancy and signs of local invasion (⊕000).**

**R 4.5. We suggest an individualized approach in patients that do not fall in one of the above-mentioned categories (⊕000).**

**Reasoning:**

The main threat of a unilateral adrenal mass, which is suspected to be malignant, is adrenocortical carcinoma. For adrenocortical carcinoma without metastases, surgery is the most important single therapeutic measure. Thus, the high expertise of the surgeon is of major importance. Although we cannot provide a specific number of required operations per year, we have no doubts that surgical volume correlates with better outcome. As summarized above (Section 4.3), there are nine cohort studies on surgery for localized adrenocortical carcinoma comparing laparoscopic vs open adrenalectomy, each with more than ten patients per group (151, 152, 153, 154, 155, 156, 157, 158, 159), but these studies are, however, hampered by methodological flaws, and importantly, none was randomized. Nevertheless, based on these data and the clinical experience of the guideline group members, it was judged that laparoscopic adrenalectomy may be justified for tumors with radiological signs of malignancy, but only where there was no evidence of local invasion. For this approach, the group arbitrarily chose a cut-off size for the adrenal tumor of  $\leq 6$  cm (Fig. 3); because for this size, it is believed that laparoscopic adrenalectomy is feasible without rupture of tumor capsule (a major risk factor for recurrence) and is beneficial for the patient (e.g. less pain, shorter hospital stay). However, with increasing tumor size, risk of tumor capsule rupture

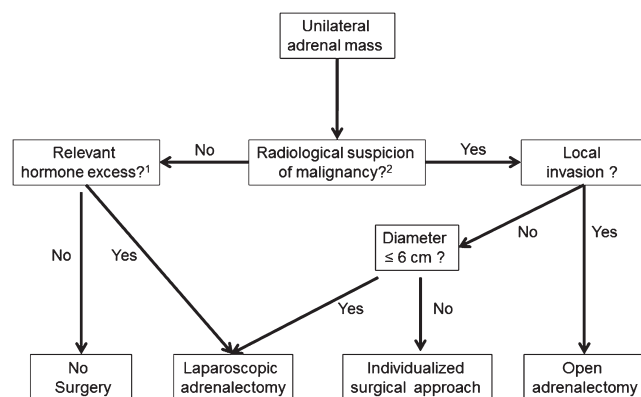
may increase. If during surgery there is a risk of tumor capsule rupture, conversion to open procedure should be performed. We acknowledge that the cut-off of 6 cm for laparoscopic vs open adrenalectomy is not based on good evidence from clinical studies, but we recognize that laparoscopic adrenalectomy for tumors  $< 6$  cm is common practice in most centers. However, this cut-off by no means indicates that every tumor smaller than 6 cm has to undergo laparoscopic adrenalectomy and every tumor larger than 6 cm has to undergo open adrenalectomy. We are convinced that in many cases, an individualized decision process is required to find the best surgical approach for a given patient. This is also true for all patients that do not fall in one of the categories described in R 4.2.–4.4.

There are no sufficiently powered studies published on the approach to patients with stage III adrenocortical carcinoma (local invasion, lymph nodes metastases or tumor thrombus in the renal vein or vena cava). However, the guideline group unanimously voted for open adrenalectomy as standard procedure for this stage of disease.

**R 4.6. We recommend perioperative glucocorticoid treatment at major surgical stress doses, as recommended by guidelines, in all patients undergoing surgery for an adrenal tumor, where there is evidence of ‘possible autonomous cortisol secretion’ or ‘autonomous cortisol secretion’.**

**Reasoning:**

Autonomous cortisol secretion may lead to adrenal insufficiency after removal of the adrenal source of cortisol (even in patients with incompletely suppressed ACTH (196)). Therefore, the group unanimously recommends intra- and postoperative glucocorticoid replacement, preferably by hydrocortisone in patients with an adrenal tumor and evidence for ‘(possible) autonomous cortisol secretion’ (post-dexamethasone cortisol  $> 50$  nmol/L ( $> 1.8$   $\mu$ g/dL)) even if there are no clinical sign of cortisol excess. This should follow the suggestions for major stress dose replacement as per a recent international guideline (197). Postoperatively, the glucocorticoid dose should be tapered individually by a physician experienced in this clinical scenario.



<sup>1</sup>'Autonomous cortisol secretion' is not automatically judged as clinically relevant (see Section 5.3 for details).

<sup>2</sup>In tumors with benign radiological features and a tumor size  $> 4$  cm, surgery might also be individually considered (see text).

**Figure 3**

Flowchart on the management of adrenal masses considered for surgery.

**5.5. Follow-up of patients not undergoing adrenal surgery after initial assessment**

**R 5.1. We suggest against further imaging during follow-up in patients with an adrenal**

**mass <4 cm with clear benign features on imaging studies (⊕000).**Reasoning:

Among more than 2300 patients included in published follow-up studies (3, 9), there is no report of occurrence of adrenal malignancy in adrenal incidentalomas displaying typical features of adrenocortical adenomas at initial imaging studies. Therefore, the panel does not support repeating imaging investigations if the initial work-up is unequivocally consistent with a benign lesion. However, many patients with adrenal incidentalomas >4 cm in diameter have undergone adrenalectomy in the past, and the literature on follow-up of nonoperated large adrenal incidentalomas is scarce. Thus, and similar to the discussion on the surgical treatment (R 4.2.), some panel members argued that one follow-up imaging (noncontrast CT or MRI) after 6–12 months might be considered in lesions >4 cm.

**R 5.2. In patients with an indeterminate adrenal mass (by imaging), opting not to undergo adrenalectomy following initial assessment, we suggest a repeat noncontrast CT or MRI after 6–12 months to exclude significant growth (⊕000). We suggest surgical resection if the lesion enlarges by more than 20% (in addition to at least a 5 mm increase in maximum diameter) during this period. If there is growth of the lesion below this threshold, additional imaging again after 6–12 months might be performed.**

Reasoning:

Contrary to benign adrenal tumors that may exhibit a slow growth tendency with time, malignant adrenal lesions (mostly adrenocortical carcinoma and metastases) are almost invariably characterized by a rapid growth within months (185, 192, 193). Consequently, the panel recommends performing follow-up imaging studies in adrenal incidentaloma, in which the benign nature cannot be established with certainty at initial evaluation, in order to recognize early a rapidly growing mass. Many clinicians would opt for surgical removal if the mass is of larger size and cannot be determined as benign with certainty.

Lack of growth of an adrenal mass over a period of 6–12 months makes a malignant mass highly unlikely, while surgery is recommended if significant rapid growth is observed. There is no generally accepted definition of significant growth of an adrenal tumor. However, the panel proposes an adaptation of the RECIST 1.1 criteria

(198). These criteria, which are used in most oncological trials, define progress by an increase of 20% of the largest diameter. Although RECIST 1.1 criteria are not validated for the differentiation between benign and malignant adrenal tumors, the 20% cut-off together with an absolute increase of at least 5 mm in diameter may serve as warning for significant growth and reconsideration then given for surgical excision.

The panel is aware that there are exceptional cases of malignant adrenal tumor without significant growth for several years (199, 200). However, this can be considered a very rare exception and does not justify following all patients with an adrenal mass with repeated imaging over years. However, in case there is some measurable growth (10–20%) that does not qualify for the above-mentioned criteria, additional follow-up imaging should be considered.

**R 5.3. We suggest against repeated hormonal work-up in patients with a normal hormonal work-up at initial evaluation unless new clinical signs of endocrine activity appear or there is worsening of comorbidities (e.g. hypertension and type 2 diabetes) (⊕000).**

Reasoning:

The pooled risk of developing clinically relevant hormonal excess (e.g. primary aldosteronism, Cushing's syndrome and pheochromocytoma) is below 0.3% in patients with initial hormonal work-up consistent with a nonfunctioning lesion (3, 9).

Development of 'autonomous cortisol secretion' without signs of overt Cushing's syndrome is the most frequently reported event during the follow-up and may occur in 0–11% of patients with nonfunctioning adrenal incidentalomas. The risk of clinically overt Cushing's syndrome however is extremely low. Owing to the risk of false-positive results (201), the panel does not recommend systematic follow-up hormonal investigations in patients with nonfunctioning adrenal incidentalomas at initial evaluation (i.e. cortisol ≤50 nmol/L (≤1.8 µg/dL) post 1 mg overnight dexamethasone test).

**R 5.4. In patients with 'autonomous cortisol secretion' without signs of overt Cushing's syndrome (Fig. 2), we suggest annual clinical reassessment for cortisol excess and comorbidities potentially related to cortisol excess (⊕000). Based on the outcome of this evaluation, the potential benefit of surgery should be considered.**

Reasoning:

As discussed above, it is extremely rare that patients will develop overt Cushing's syndrome during follow-up. However, as elaborated in Section 5.3, the panel considers 'autonomous cortisol secretion' as a condition associated with several comorbidities (Table 2). Therefore, the panel recommends annual clinical follow-up in patients with 'autonomous cortisol secretion' and in patients with both 'possible autonomous cortisol secretion' and potentially associated comorbidities, in whom an initial decision against surgery was made (Fig. 2). Clinical follow-up should include evaluation of potentially cortisol excess-related comorbidities. The presence or worsening of these conditions should prompt hormonal re-evaluation at any time during follow-up. Appropriate symptomatic treatment and reconsideration of surgical removal of the adrenal mass is recommended, in line with the observed changes in the clinical and hormonal status of the patient.

In the absence of published evidence, we suggest that follow-up by an endocrinologist beyond 2–4 years is not needed in patients with no relevant change during this time.

## 5.6. Special circumstances

### 5.6.1. Patients with bilateral adrenal incidentalomas

**R 6.1.1. We recommend that for patients with bilateral adrenal masses, each adrenal lesion is assessed at the time of initial detection according to the same imaging protocol as for unilateral adrenal masses to establish if either or both lesions are benign or malignant.**

Reasoning:

In most cases, bilateral adrenal masses represent benign bilateral adrenocortical disease: bilateral adenomas, macronodular hyperplasia or distinct bilateral nodules with normal or atrophic cortex intervening. The possibility of metastases (especially in patients with known malignancy), adrenal lymphoma or bilateral pheochromocytomas should also be considered. Moreover, bilateral adrenal masses may represent co-occurrence of different entities, such as adenoma, pheochromocytoma, cyst, myelolipoma and adrenocortical carcinoma. Therefore, the best approach is to separately characterize each lesion following the recommendations in R 2.2.–R 2.4.

**R 6.1.2. We recommend that all patients with bilateral adrenal incidentalomas should undergo**

**clinical and hormonal assessment identical to that in patients with unilateral adrenal incidentaloma (see Section 5.3). The same applies for the assessment of comorbidities that might be related to 'autonomous cortisol secretion' (Table 2). In addition, serum 17-hydroxyprogesterone should be measured to exclude congenital adrenal hyperplasia, and testing for adrenal insufficiency should be considered if suspected on clinical grounds or if imaging suggests bilateral infiltrative disease or hemorrhages.**

Reasoning:

Hormonal excess in patients with bilateral adrenal masses may originate either from one of the lesions or bilaterally. Cushing's syndrome, primary aldosteronism, and pheochromocytoma(s) may all be encountered. For the clinical assessment of these entities, we refer to guidelines of other societies (71, 72, 181). As for unilateral lesions, subtle autonomous cortisol secretion is the most common secretory abnormality and, therefore, requires a full assessment of related comorbidities. Occasionally, bilateral adrenal enlargement is due to congenital adrenal hyperplasia and, therefore, the additional measurement of 17-hydroxyprogesterone should be performed (202). However, the measurement of 17-hydroxyprogesterone to identify the most common cause of congenital adrenal hyperplasia, 21-hydroxylase deficiency, as the cause of bilateral adrenal hyperplasia should be interpreted with caution. In some cases, increased levels of 17-hydroxyprogesterone may represent increased secretion of steroid precursors from the lesion(s) (203) especially in malignant tumors or in bilateral macronodular adrenal hyperplasia. In these cases, low/suppressed ACTH levels may argue against congenital adrenal hyperplasia. Bilateral adrenal enlargement due to metastatic disease rarely causes adrenal insufficiency (for details, see R 6.3.6.).

**R 6.1.3. We suggest that for patients with bilateral incidentaloma, the same recommendations regarding the indication of surgery and follow-up are used as for patients with unilateral adrenal incidentalomas.**

Reasoning:

'Autonomous cortisol secretion' is more frequently encountered in patients with bilateral adrenal incidentalomas, compared with those with unilateral lesions, but there is no published evidence that they should be managed differently. However, in the few cases,

in whom bilateral surgery is potentially indicated (e.g. bilateral pheochromocytomas), one can consider adrenal-sparing surgery (204).

**R 6.1.4. We suggest that in patients with bilateral adrenal masses, bilateral adrenalectomy is not performed for ‘autonomous cortisol secretion’ without clinical signs of overt Cushing’s syndrome. In selected patients, a unilateral adrenalectomy of the dominant lesion might be considered using an individualized approach considering age, degree of cortisol excess, general condition, comorbidities and patient preference.**

Reasoning:

Surgery is a complex decision for patients with bilateral adrenal incidentalomas. This is because, in the absence of clinical signs of overt Cushing’s syndrome, the clinical situation may not be severe enough to prompt surgical management. Moreover, bilateral adrenalectomy is associated with higher morbidity compared with unilateral surgery; the patient is dependent lifelong on adrenal replacement therapy and at risk for life-threatening adrenal crisis. In addition, glucocorticoid replacement is frequently suboptimal and cannot mimic the diurnal profile of endogenous cortisol, and may result in persisting exposure to subtle cortisol excess. In bilateral macronodular adrenal hyperplasia, there is limited evidence of beneficial effects of unilateral adrenalectomy (205, 206). In most published studies, excision of the largest lesion was performed, based on observations that the size of the adrenal lesion correlates with the degree of cortisol excess (205). Adrenal venous sampling may aid in the lateralization of cortisol excess, but the data are very weak (207). Due to the limited available evidence, an individualized approach, considering age, degree of cortisol excess, general condition, comorbidity status and patient’s preference is suggested. However, when bilateral surgery is potentially indicated, cortical sparing adrenalectomy might be considered (208).

In cases of bilateral macronodular hyperplasia, especially in younger patients or those with relevant family history, family screening with 1 mg dexamethasone test can be considered.

A number of patients will have evidence of the presence of aberrant receptors. However, routine assessment by the complex testing (27, 209, 210, 211, 212, 213, 214, 215) needed to establish the presence of these receptors is hard to justify based on the fact that in the majority of patients, long-term management will not be based on knowledge of receptor activity, and,

therefore, we suggest that these tests should be confined to clinical studies.

*5.6.2. Adrenal incidentalomas in young or elderly patients*

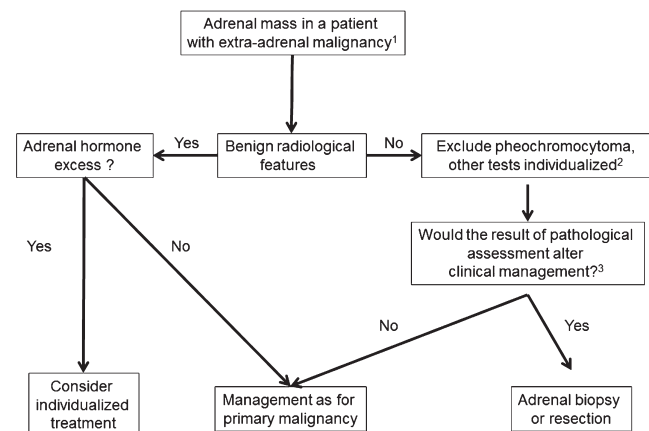
**R 6.2.1. We recommend urgent assessment of an adrenal mass in children, adolescents, pregnant women and adults <40 years of age because of a higher likelihood of malignancy.**

**R 6.2.2. We suggest the use of MRI rather than CT in children, adolescents, pregnant women and adults <40 years of age if dedicated adrenal imaging is required.**

**R 6.2.3. We recommend that the management of patients with poor general health and a high degree of frailty be kept in proportion to potential clinical gain.**

Reasoning:

The incidence of adrenal incidentaloma shows clear variation with age, with the majority of patients presenting in the 5th to 7th decade of life. Overall incidence of adrenal incidentaloma in a population undergoing routine imaging not related to suspected adrenal disease is reported as 1–4% (15, 74, 76, 216). While 10% or more of individuals older than 70 years harbor an adrenal mass detectable upon imaging or autopsy, adrenal nodules in individuals <40 years are much less prevalent and are a rarity in children and young adults. Consequently, work-up in young patients including pregnant women has



<sup>1</sup>Always take life expectancy in consideration.

<sup>2</sup>If there is hormone excess, treat individualized.

<sup>3</sup>FDG-PET-CT should be considered to exclude other metastatic deposits in patients with no other obvious metastatic lesions for whom surgical removal of the lesion is an option.

**Figure 4**

Evaluation of patients with adrenal mass and known extra-adrenal malignancy.



to be pursued with urgency, as the risk of malignancy in this cohort is much higher. Conversely, a smaller adrenal incidentaloma in an elderly patient can be assumed to have a very low pretest probability of malignancy. Thus, work-up in elderly patients only needs to be expedited if there are clear signs of suspicion of malignancy and the extent of imaging work-up should be kept in proportion to the clinical performance status of the individual and the expected clinical gain of further work-up in an affected patient.

As radiation safety is even more important in the young patient, we suggest MRI as the preferred imaging technique. However, the adapted low-dose unenhanced CT protocols can limit radiation exposure and can be considered as an alternative (especially if the availability of MRI is limited).

#### 5.6.3. Patients with a newly diagnosed adrenal mass and a history of extra-adrenal malignancy (Fig. 4)

General remarks:

In principle, for adrenal masses in patients with known extra-adrenal malignancy, the same recommendations apply as described above. However, in this situation, it is particularly important to consider the different pretest probabilities and the life expectancy of the patient.

In patients with underlying extra-adrenal malignancy and an indeterminate adrenal mass, studies revealed a high rate of malignancy, up to 70%. Although age-specific subgroup analysis is not available, it can be assumed that older patients have a higher likelihood of co-existent benign adenomas. Conversely, younger patients with an underlying malignancy are more likely to have a metastasis.

**R 6.3.1. We recommend measurement of plasma or urinary metanephrines to exclude pheochromocytoma in patients with extra-adrenal malignancy with an indeterminate mass, even if the adrenal mass is likely to be a metastasis. We suggest additional hormonal work-up based on an individualized approach.**

#### Reasoning:

Pheochromocytomas are almost impossible to distinguish from metastasis by conventional imaging (including FDG-PET/CT). Furthermore, pheochromocytomas can lead to life-threatening complications, especially in the context of medical interventions (surgery, biopsies etc.) (72, 217, 218). Additional hormonal work-up should depend on the stage of the extra-adrenal malignancy

and life expectancy. Evidence of adrenal hormone excess indicating that the mass is a primary adrenal lesion can influence management of the extra-adrenal malignancy.

**R 6.3.2. We suggest that in patients with a history of extra-adrenal malignancy, FDG-PET/CT, performed as part of investigations for the underlying malignancy, can replace other adrenal imaging techniques.**

#### Reasoning:

<sup>18</sup>FDG-PET-CT may add additional value in the assessment of an indeterminate adrenal mass; however, the evidence base is insufficient to make strong recommendations (77). Both qualitative and quantitative interpretations of <sup>18</sup>FDG-PET-CT imaging have been studied, but these vary considerably. An adrenal lesion/liver ratio of 1.53–1.8 were investigated in patients with history of extra-adrenal malignancy (2 studies (92, 93), 117 lesions) and found to have sensitivity of 82% (95% CI: 41–97%) and specificity of 96% (95% CI: 76–99%) to detect malignant disease.

**R 6.3.3. We recommend that in patients with a history of extra-adrenal malignancy, adrenal lesions characterized as benign by noncontrast CT require no further specific adrenal imaging follow-up.**

#### Reasoning:

See details **R 2.2.–R 2.4.** However, we acknowledge that the currently available data suggest a false-negative rate of 7% in this population.

**R 6.3.4. For indeterminate lesions in patients with a history of extra-adrenal malignancy, we recommend imaging follow-up assessing the potential growth of the lesion at the same interval as imaging for the primary malignancy. Alternatively, FDG-PET/CT, surgical resection or a biopsy (see also R 6.3.5.) can be considered.**

#### Reasoning:

In many patients with advanced extra-adrenal malignancy (e.g. with multiple metastases), the knowledge of the origin of the adrenal mass will not alter the clinical management of the patient. If, however, clinical management would be altered by the demonstration that the adrenal lesion is a metastasis, then every effort should be made to allow this discrimination. If the adrenal mass is potentially the only metastasis and if resection of this metastasis seems to be reasonable from an oncological point of view, then surgery should be considered. Regarding biopsy, we recommend applying the criteria provided in **R 6.3.5.**

**R 6.3.5.** We suggest performing a biopsy of an adrenal mass only if all of the following criteria are fulfilled: (i) the lesion is hormonally inactive (in particular, a pheochromocytoma has been excluded), (ii) the lesion has not been conclusively characterized as benign by imaging and (iii) management would be altered by knowledge of the histology.

Reasoning:

Adrenal biopsy may present with a significant nondiagnostic rate and a potential for complications (78). Biopsy is only recommended for masses not characterized as benign on cross-sectional imaging and where a biopsy result would affect clinical treatment decisions. In patients with no other obvious metastatic lesions and when surgical removal of the lesion is an option, FDG-PET/CT should be considered in order to exclude metastases outside the adrenal that were not visualized by CT or MRI. Adrenal biopsy presents with lower diagnostic performance for ACC and, therefore, is not recommended in this setting (78).

**R 6.3.6. We recommend assessment of residual adrenal function in patients with large bilateral metastases.**

Reasoning:

In rare cases, bilateral adrenal metastases can lead to adrenal insufficiency. Thus, in all patients with potentially bilateral metastases, adrenal insufficiency should be considered and clinically evaluated. If adrenal insufficiency seems to be possible, we recommend first to measure a morning serum cortisol and plasma ACTH. In case of adrenal insufficiency, plasma ACTH is clearly elevated in parallel to low cortisol. In uncertain cases, a synacthen test should be performed (197).

If only one adrenal metastasis is present, adrenal insufficiency is extremely unlikely and we recommend no specific assessment of adrenal reserve.

## 6. Future directions and recommended research

The NIH conference on the management of the clinically unapparent adrenal mass in 2002 formulated several research questions for future studies (5). Although some of these issues have been addressed, only few questions have been conclusively answered. From the current perspective, we see need for clinical trials in all four areas particularly addressed in the guideline (see Section 3.5). Given that most recommendations in this guideline are

based on weak evidence, there is clearly room for studies aiming to improve the evidence base of management of adrenal incidentalomas.

Among many important research questions, we selected five as particularly important. All of them can only be answered in a collaborative interdisciplinary manner.

1. Large, cohort study in patients with an adrenal mass >2 cm to investigate the most suitable imaging methods to determine if an adrenal mass is benign or not. It will be crucial to establish a definitive diagnosis either by histopathology or by long-term follow-up (>2 years).
2. Large, long-term study to define whether or not 'autonomous cortisol secretion' is associated with increased mortality and other hard clinical endpoints (e.g. myocardial infarction or stroke). Such a study will also provide evidence for a suitable biochemical definition of 'autonomous cortisol secretion'.
3. Randomized trial on the potential benefit of surgery in patients with 'autonomous cortisol secretion'. To make such a trial feasible, it is probably wise to define a surrogate endpoint (e.g. hypertension or type 2 diabetes) that can be well controlled (including standardized treatment regimens) throughout the study. A similar trial could evaluate the value of drugs targeting the cortisol excess.
4. Prospective study (laparoscopic vs open surgery) in patients with potentially malignant adrenal mass (<10 cm) without preoperative evidence of local invasion and metastases to learn which surgical approach is the most suitable one for this patient cohort.
5. We propose a long-term study with annual biochemical work-up of patients with adrenal incidentalomas to clarify if such a long-term hormonal assessment is justified. This study should also help to define the true incidence of relevant diseases like adrenocortical carcinoma and pheochromocytoma among incidentalomas.

Several other research questions deserve future research. Of particular importance seems to us the establishment of biomarkers to determine noninvasively the origin of the adrenal mass (adrenal cortex, medulla, extra-adrenal) and whether or not the mass is malignant. Currently, urine steroid metabolomics for noninvasive and radiation-free detection of a malignant 'steroid fingerprint' in adrenocortical carcinoma patients (194) and the combination of functional imaging methods (e.g. metomidate-based imaging and FDG-PET/CT) are the

most promising tools that should be further investigated. Similarly, for patients with 'autonomous cortisol secretion', new methods to stratify on an individual basis to intervention (or observation) are needed.

#### Appendix

This is linked to the online version of the paper at <http://dx.doi.org/10.1530/EJE-16-0467>.

#### Declaration of interest

The guideline group was supported by CBO – Dutch Institute for Health Care Improvement.

#### Funding

This guideline was sponsored by the European Society of Endocrinology with support by the European Network for the Study of Adrenal Tumors (via the European Science Foundation).

#### Acknowledgements

The authors of the guideline would like to thank and acknowledge André Lacroix, Radu Mihai and Paul Stewart for their expert review and additional 28 members of the European Society of Endocrinology, the European Network for the Study of Adrenal Tumors or representatives of national endocrine societies for valuable and critical comments. Furthermore, they thank two patient representatives who provided valuable feedback for the guideline. The comments of the reviewers as well as the authors' responses are available as [Appendix X](#).

#### References

- Barzon L, Scaroni C, Sonino N, Fallo F, Paoletta A & Boscaro M. Risk factors and long-term follow-up of adrenal incidentalomas. *Journal of Clinical Endocrinology and Metabolism* 1999 **84** 520–526. (doi:10.1210/jcem.84.2.5444)
- Barzon L, Sonino N, Fallo F, Palu G & Boscaro M. Prevalence and natural history of adrenal incidentalomas. *European Journal of Endocrinology* 2003 **149** 273–285. (doi:10.1530/eje.0.1490273)
- Cawood TJ, Hunt PJ, O'Shea D, Cole D & Soule S. Recommended evaluation of adrenal incidentalomas is costly, has high false-positive rates and confers a risk of fatal cancer that is similar to the risk of the adrenal lesion becoming malignant; time for a rethink? *European Journal of Endocrinology* 2009 **161** 513–527. (doi:10.1530/EJE-09-0234)
- Favia G, Lumachi F, Basso S & D'Amico DF. Management of incidentally discovered adrenal masses and risk of malignancy. *Surgery* 2000 **128** 918–924. (doi:10.1067/msy.2000.109965)
- Grumbach MM, Biller BM, Braunstein GD, Campbell KK, Carney JA, Godley PA, Harris EL, Lee JK, Oertel YC, Posner MC *et al.* Management of the clinically inapparent adrenal mass ("incidentaloma"). *Annals of Internal Medicine* 2003 **138** 424–429. (doi:10.7326/0003-4819-138-5-200303040-00013)
- Kloos RT, Gross MD, Francis IR, Korobkin M & Shapiro B. Incidentally discovered adrenal masses. *Endocrine Reviews* 1995 **16** 460–484. (doi:10.1210/edrv-16-4-460)
- Mansmann G, Lau J, Balk E, Rothberg M, Miyachi Y & Bornstein SR. The clinically inapparent adrenal mass: update in diagnosis and management. *Endocrine Reviews* 2004 **25** 309–340. (doi:10.1210/er.2002-0031)
- Tabarin A, Bardet S, Bertherat J, Dupas B, Chabre O, Hamoir E, Laurent F, Tenenbaum F, Cazalda M, Lefebvre H *et al.* Exploration and management of adrenal incidentalomas. French Society of Endocrinology Consensus. *Annales d'Endocrinologie* 2008 **69** 487–500. (doi:10.1016/j.ando.2008.09.003)
- Terzolo M, Stigliano A, Chiodini I, Loli P, Furlani L, Arnaldi G, Reimondo G, Pia A, Toscano V, Zini M *et al.* AME position statement on adrenal incidentaloma. *European Journal of Endocrinology* 2011 **164** 851–870. (doi:10.1530/EJE-10-1147)
- Young WF Jr. Clinical practice. The incidentally discovered adrenal mass. *New England Journal of Medicine* 2007 **356** 601–610. (doi:10.1056/NEJMcp065470)
- Zeiger MA, Thompson GB, Duh QY, Hamrahian AH, Angelos P, Elaraj D, Fishman E & Kharlip J. American Association of Clinical Endocrinologists and American Association of Endocrine Surgeons Medical Guidelines for the Management of Adrenal Incidentalomas: executive summary of recommendations. *Endocrine Practice* 2009 **15** 450–453. (doi:10.4158/EP.15.5.450)
- Zeiger MA, Thompson GB, Duh QY, Hamrahian AH, Angelos P, Elaraj D, Fishman E & Kharlip J. The American Association of Clinical Endocrinologists and American Association of Endocrine Surgeons medical guidelines for the management of adrenal incidentalomas. *Endocrine Practice* 2009 **15** (Supplement 1) 1–20. (doi:10.4158/EP.15.S1.1)
- Young WF Jr. Management approaches to adrenal incidentalomas. A view from Rochester, Minnesota. *Endocrinology and Metabolism Clinics of North America* 2000 **29** 159–185. (doi:10.1016/S0889-8529(05)70122-5)
- Mantero F, Terzolo M, Arnaldi G, Osella G, Masini AM, Ali A, Giovagnetti M, Opocher G & Angeli A. A survey on adrenal incidentaloma in Italy. Study Group on Adrenal Tumors of the Italian Society of Endocrinology. *Journal of Clinical Endocrinology and Metabolism* 2000 **85** 637–644. (doi:10.1210/jcem.85.2.6372)
- Bovio S, Cataldi A, Reimondo G, Sperone P, Novello S, Berruti A, Borasio P, Fava C, Dogliotti L, Scagliotti GV *et al.* Prevalence of adrenal incidentaloma in a contemporary computerized tomography series. *Journal of Endocrinological Investigation* 2006 **29** 298–302. (doi:10.1007/BF03344099)
- Benitah N, Yeh BM, Qayyum A, Williams G, Breiman RS & Coakley FV. Minor morphologic abnormalities of adrenal glands at CT: prognostic importance in patients with lung cancer. *Radiology* 2005 **235** 517–522. (doi:10.1148/radiol.2352031708)
- Bernini G, Moretti A, Argenio G & Salvetti A. Primary aldosteronism in normokalemic patients with adrenal incidentalomas. *European Journal of Endocrinology* 2002 **146** 523–529. (doi:10.1530/eje.0.1460523)
- Lam KY & Lo CY. Metastatic tumours of the adrenal glands: a 30-year experience in a teaching hospital. *Clinical Endocrinology* 2002 **56** 95–101. (doi:10.1046/j.0300-0664.2001.01435.x)
- Ross NS. Epidemiology of Cushing's syndrome and subclinical disease. *Endocrinology and Metabolism Clinics of North America* 1994 **23** 539–546.
- Bernini GP, Moretti A, Oriandini C, Bardini M, Taurino C & Salvetti A. Long-term morphological and hormonal follow-up in a single unit on 115 patients with adrenal incidentalomas. *British Journal of Cancer* 2005 **92** 1104–1109. (doi:10.1038/sj.bjc.6602459)
- Fagour C, Bardet S, Rohmer V, Arimone Y, Lecomte P, Valli N & Tabarin A. Usefulness of adrenal scintigraphy in the follow-up of adrenocortical incidentalomas: a prospective multicenter study. *European Journal of Endocrinology* 2009 **160** 257–264. (doi:10.1530/EJE-08-0299)
- Libe R, Dall'Asta C, Barbetta L, Baccarelli A, Beck-Peccoz P & Ambrosi B. Long-term follow-up study of patients with adrenal incidentalomas. *European Journal of Endocrinology* 2002 **147** 489–494. (doi:10.1530/eje.0.1470489)

- 23 Terzolo M, Bovio S, Reimondo G, Pia A, Osella G, Borretta G & Angeli A. Subclinical Cushing's syndrome in adrenal incidentalomas. *Endocrinology and Metabolism Clinics of North America* 2005 **34** 423–439. (doi:10.1016/j.ecl.2005.01.008)
- 24 Terzolo M, Osella G, Ali A, Borretta G, Cesario F, Paccotti P & Angeli A. Subclinical Cushing's syndrome in adrenal incidentaloma. *Clinical Endocrinology* 1998 **48** 89–97.
- 25 Nieman LK. Update on subclinical Cushing's syndrome. *Current Opinion in Endocrinology Diabetes and Obesity* 2015 **22** 180–184. (doi:10.1097/MED.0000000000000159)
- 26 Dekkers OM, Horvath-Puho E, Jorgensen JO, Cannegieter SC, Ehrenstein V, Vandenbroucke JP, Pereira AM & Sorensen HT. Multisystem morbidity and mortality in Cushing's syndrome: a cohort study. *Journal of Clinical Endocrinology and Metabolism* 2013 **98** 2277–2284. (doi:10.1210/jc.2012-3582)
- 27 Lacroix A, Feelders RA, Stratakis CA & Nieman LK. Cushing's syndrome. *Lancet* 2015 **386** 913–927. (doi:10.1016/S0140-6736(14)61375-1)
- 28 Neychev V, Steinberg SM, Yang L, Mehta A, Nilubol N, Keil MF, Nieman L, Stratakis CA & Kebebew E. Long-term outcome of bilateral laparoscopic adrenalectomy measured by disease-specific questionnaire in a unique group of patients with Cushing's syndrome. *Annals of Surgical Oncology* 2015 **22** 699–706. (doi:10.1245/s10434-015-4605-1)
- 29 Nieman LK. Cushing's syndrome: update on signs, symptoms and biochemical screening. *European Journal of Endocrinology* 2015 **173** M33–M38. (doi:10.1530/EJE-15-0464)
- 30 Nieman LK, Biller BM, Findling JW, Murad MH, Newell-Price J, Savage MO & Tabarin A. Treatment of Cushing's syndrome: an Endocrine Society Clinical Practice Guideline. *Journal of Clinical Endocrinology and Metabolism* 2015 **100** 2807–2831.
- 31 Terzolo M, Bovio S, Pia A, Conton PA, Reimondo G, Dall'Asta C, Bemporad D, Angeli A, Opocher G, Mannelli M *et al.* Midnight serum cortisol as a marker of increased cardiovascular risk in patients with a clinically inapparent adrenal adenoma. *European Journal of Endocrinology* 2005 **153** 307–315. (doi:10.1530/eje.1.01959)
- 32 Tauchmanova L, Rossi R, Biondi B, Pulcrano M, Nuzzo V, Palmieri EA, Fazio S & Lombardi G. Patients with subclinical Cushing's syndrome due to adrenal adenoma have increased cardiovascular risk. *Journal of Clinical Endocrinology and Metabolism* 2002 **87** 4872–4878. (doi:10.1210/jc.2001-011766)
- 33 Emral R, Uysal AR, Asik M, Gullu S, Corapcioglu D, Tonyukuk V & Erdogan G. Prevalence of subclinical Cushing's syndrome in 70 patients with adrenal incidentaloma: clinical, biochemical and surgical outcomes. *Endocrine Journal* 2003 **50** 399–408. (doi:10.1507/endocrj.50.399)
- 34 Bernini G, Moretti A, Iacconi P, Miccoli P, Nami R, Lucani B & Salvetti A. Anthropometric haemodynamic, humoral and hormonal evaluation in patients with incidental adrenocortical adenomas before and after surgery. *European Journal of Endocrinology* 2003 **148** 213–219. (doi:10.1530/eje.0.1480213)
- 35 Morelli V, Masserini B, Salcuni AS, Eller-Vainicher C, Savoca C, Viti R, Coletti F, Guglielmi G, Battista C, Iorio L *et al.* Subclinical hypercortisolism: correlation between biochemical diagnostic criteria and clinical aspects. *Clinical Endocrinology* 2010 **73** 161–166. (doi:10.1111/j.1365-2265.2010.03794.x)
- 36 Rossi R, Tauchmanova L, Luciano A, Di Martino M, Battista C, Del Viscovo L, Nuzzo V & Lombardi G. Subclinical Cushing's syndrome in patients with adrenal incidentaloma: clinical and biochemical features. *Journal of Clinical Endocrinology and Metabolism* 2000 **85** 1440–1448. (doi:10.1210/jcem.85.4.6515)
- 37 Reincke M, Fassnacht M, Vath S, Mora P & Allolio B. Adrenal incidentalomas: a manifestation of the metabolic syndrome? *Endocrine Research* 1996 **22** 757–761. (doi:10.1080/07435809609043773)
- 38 Di Dalmazi G, Vicennati V, Rinaldi E, Morselli-Labate AM, Giampalma E, Mosconi C, Pagotto U, Pasquali R, Di Dalmazi G, Vicennati V *et al.* Progressively increased patterns of subclinical cortisol hypersecretion in adrenal incidentalomas differently predict major metabolic and cardiovascular outcomes: a large cross-sectional study. *European Journal of Endocrinology* 2012 **166** 669–677. (doi:10.1530/EJE-11-1039)
- 39 Fernandez-Real JM, Engel WR, Simo R, Salinas I & Webb SM. Study of glucose tolerance in consecutive patients harbouring incidental adrenal tumours. Study Group of Incidental Adrenal Adenoma. *Clinical Endocrinology* 1998 **49** 53–61. (doi:10.1046/j.1365-2265.1998.00437.x)
- 40 Giordano R, Marinazzo E, Berardelli R, Picu A, Maccario M, Ghigo E & Arvat E. Long-term morphological, hormonal, and clinical follow-up in a single unit on 118 patients with adrenal incidentalomas. *European Journal of Endocrinology* 2010 **162** 779–785. (doi:10.1530/EJE-09-0957)
- 41 Hadjidakis D, Tsagarakis S, Roboti C, Sfakianakis M, Iconomidou V, Raptis SA & Thalassinou N. Does subclinical hypercortisolism adversely affect the bone mineral density of patients with adrenal incidentalomas? *Clinical Endocrinology* 2003 **58** 72–77. (doi:10.1046/j.1365-2265.2003.01676.x)
- 42 Chiadini I, Guglielmi G, Battista C, Carnevale V, Torlontano M, Cammisà M, Trischitta V & Scillitani A. Spinal volumetric bone mineral density and vertebral fractures in female patients with adrenal incidentalomas: the effects of subclinical hypercortisolism and gonadal status. *Journal of Clinical Endocrinology and Metabolism* 2004 **89** 2237–2241. (doi:10.1210/jc.2003-031413)
- 43 Chiadini I, Morelli V, Masserini B, Salcuni AS, Eller-Vainicher C, Viti R, Coletti F, Guglielmi G, Battista C, Carnevale V *et al.* Bone mineral density, prevalence of vertebral fractures, and bone quality in patients with adrenal incidentalomas with and without subclinical hypercortisolism: an Italian multicenter study. *Journal of Clinical Endocrinology and Metabolism* 2009 **94** 3207–3214. (doi:10.1210/jc.2009-0468)
- 44 Chiadini I, Morelli V, Salcuni AS, Eller-Vainicher C, Torlontano M, Coletti F, Iorio L, Cuttitta A, Ambrosio A, Vicentini L *et al.* Beneficial metabolic effects of prompt surgical treatment in patients with an adrenal incidentaloma causing biochemical hypercortisolism. *Journal of Clinical Endocrinology and Metabolism* 2010 **95** 2736–2745. (doi:10.1210/jc.2009-2387)
- 45 Eller-Vainicher C, Morelli V, Ulivieri FM, Palmieri S, Zhukouskaya VV, Cairoli E, Pino R, Naccarato A, Scillitani A, Beck-Peccoz P *et al.* Bone quality, as measured by trabecular bone score in patients with adrenal incidentalomas with and without subclinical hypercortisolism. *Journal of Bone & Mineral Research* 2012 **27** 2223–2230. (doi:10.1002/jbmr.1648)
- 46 Morelli V, Eller-Vainicher C, Salcuni AS, Coletti F, Iorio L, Muscogiuri G, Della CS, Arosio M, Ambrosio B, Beck-Peccoz P *et al.* Risk of new vertebral fractures in patients with adrenal incidentaloma with and without subclinical hypercortisolism: a multicenter longitudinal study. *Journal of Bone & Mineral Research* 2011 **26** 1816–1821. (doi:10.1002/jbmr.398)
- 47 Peppercorn PD, Grossman AB & Reznick RH. Imaging of incidentally discovered adrenal masses. *Clinical Endocrinology* 1998 **48** 379–388. (doi:10.1046/j.1365-2265.1998.00475.x)
- 48 Caoili EM, Korobkin M, Francis IR, Cohan RH, Platt JF, Dunnick NR & Raghupathi KI. Adrenal masses: characterization with combined unenhanced and delayed enhanced CT. *Radiology* 2002 **222** 629–633. (doi:10.1148/radiol.2223010766)
- 49 Blake MA, Kalra MK, Sweeney AT, Lucey BC, Maher MM, Sahani DV, Halpern EF, Mueller PR, Hahn PF & Boland GW. Distinguishing benign from malignant adrenal masses: multi-detector row CT protocol with 10-minute delay. *Radiology* 2006 **238** 578–585. (doi:10.1148/radiol.2382041514)

- 50 Ilias I, Sahdev A, Reznick RH, Grossman AB & Pacak K. The optimal imaging of adrenal tumours: a comparison of different methods. *Endocrine-Related Cancer* 2007 **14** 587–599. (doi:10.1677/ERC-07-0045)
- 51 Mackie GC, Shulkin BL, Ribeiro RC, Worden FP, Gauger PG, Mody RJ, Connolly LP, Kunter G, Rodriguez-Galindo C, Wallis JW *et al.* Use of [18F]fluorodeoxyglucose positron emission tomography in evaluating locally recurrent and metastatic adrenocortical carcinoma. *Journal of Clinical Endocrinology and Metabolism* 2006 **91** 2665–2671. (doi:10.1210/jc.2005-2612)
- 52 Groussin L, Bonardel G, Silvera S, Tissier F, Coste J, Abiven G, Libe R, Bienvendu M, Alberini JL, Salenave S *et al.* 18F-Fluorodeoxyglucose positron emission tomography for the diagnosis of adrenocortical tumors: a prospective study in 77 operated patients. *Journal of Clinical Endocrinology and Metabolism* 2009 **94** 1713–1722. (doi:10.1210/jc.2008-2302)
- 53 Deandreis D, Leboulleux S, Caramella C, Schlumberger M & Baudin E. FDG PET in the management of patients with adrenal masses and adrenocortical carcinoma. *Hormones and Cancer* 2011 **2** 354–362. (doi:10.1007/s12672-011-0091-5)
- 54 Boland GW, Lee MJ, Gazelle GS, Halpern EF, McNicholas MM & Mueller PR. Characterization of adrenal masses using unenhanced CT: an analysis of the CT literature. *American Journal of Roentgenology* 1998 **171** 201–204. (doi:10.2214/ajr.171.1.9648789)
- 55 Caoili EM, Korobkin M, Francis IR, Cohan RH & Dunnick NR. Delayed enhanced CT of lipid-poor adrenal adenomas. *American Journal of Roentgenology* 2000 **175** 1411–1415.
- 56 Pena CS, Boland GW, Hahn PF, Lee MJ & Mueller PR. Characterization of indeterminate (lipid-poor) adrenal masses: use of washout characteristics at contrast-enhanced CT. *Radiology* 2000 **217** 798–802. (doi:10.1148/radiology.217.3.r00dc29798)
- 57 Zhang HM, Perrier ND, Grubbs EG, Sircar K, Ye ZX, Lee JE & Ng CS. CT features and quantification of the characteristics of adrenocortical carcinomas on unenhanced and contrast-enhanced studies. *Clinical Radiology* 2012 **67** 38–46. (doi:10.1016/j.crad.2011.03.023)
- 58 Dunnick NR & Korobkin M. Imaging of adrenal incidentalomas: current status. *American Journal of Roentgenology* 2002 **179** 559–568. (doi:10.2214/ajr.179.3.1790559)
- 59 Szolar DH & Kammerhuber FH. Adrenal adenomas and nonadenomas: assessment of washout at delayed contrast-enhanced CT. *Radiology* 1998 **207** 369–375. (doi:10.1148/radiology.207.2.9577483)
- 60 Young WF Jr. Conventional imaging in adrenocortical carcinoma: update and perspectives. *Hormones and Cancer* 2011 **2** 341–347. (doi:10.1007/s12672-011-0089-z)
- 61 McNicholas MM, Lee MJ, Mayo-Smith WW, Hahn PF, Boland GW & Mueller PR. An imaging algorithm for the differential diagnosis of adrenal adenomas and metastases. *American Journal of Roentgenology* 1995 **165** 1453–1459.
- 62 Sahdev A & Reznick RH. Imaging evaluation of the non-functioning indeterminate adrenal mass. *Trends in Endocrinology and Metabolism* 2004 **15** 271–276. (doi:10.1016/j.tem.2004.06.012)
- 63 Korobkin M, Francis IR, Kloos RT & Dunnick NR. The incidental adrenal mass. *Radiologic Clinics of North America* 1996 **34** 1037–1054.
- 64 Korobkin M, Giordano TJ, Brodeur FJ, Francis IR, Siegelman ES, Quint LE, Dunnick NR, Heiken JP & Wang HH. Adrenal adenomas: relationship between histologic lipid and CT and MR findings. *Radiology* 1996 **200** 743–747. (doi:10.1148/radiology.200.3.8756925)
- 65 Haider MA, Ghai S, Jhaveri K & Lockwood G. Chemical shift MR imaging of hyperattenuating (>10 HU) adrenal masses: does it still have a role? *Radiology* 2004 **231** 711–716. (doi:10.1148/radiol.2313030676)
- 66 Bharwani N, Rockall AG, Sahdev A, Gueorguiev M, Drake W, Grossman AB & Reznick RH. Adrenocortical carcinoma: the range of appearances on CT and MRI. *American Journal of Roentgenology* 2011 **196** W706–W714.
- 67 Becherer A, Vierhapper H, Potzi C, Karanikas G, Kurtaran A, Schmaljohann J, Staudenherz A, Dudczak R & Kletter K. FDG-PET in adrenocortical carcinoma. *Cancer Biotherapy and Radiopharmaceuticals* 2001 **16** 289–295. (doi:10.1089/108497801753131363)
- 68 Vogel WV, Oyen WJ, Barentsz JO, Kaanders JH & Corstens FH. PET/CT: panacea, redundancy, or something in between? *Journal of Nuclear Medicine* 2004 **45** (Supplement 1) 15S–24S.
- 69 Burton TJ, Mackenzie IS, Balan K, Koo B, Bird N, Soloviev DV, Azizan EA, Aigbirhio F, Gurnell M & Brown MJ. Evaluation of the sensitivity and specificity of (11)C-metomidate positron emission tomography (PET)-CT for lateralizing aldosterone secretion by Conn's adenomas. *Journal of Clinical Endocrinology & Metabolism* 2012 **97** 100–109. (doi:10.1210/jc.2011-1537)
- 70 Hahner S, Kreissl MC, Fassnacht M, Haenscheid H, Bock S, Verburg FA, Knoedler P, Lang K, Reiners C, Buck AK *et al.* Functional characterization of adrenal lesions using [123I]IMTO-SPECT/CT. *Journal of Clinical Endocrinology & Metabolism* 2013 **98** 1508–1518. (doi:10.1210/jc.2012-3045)
- 71 Nieman LK, Biller BM, Findling JW, Newell-Price J, Savage MO, Stewart PM & Montori VM. The diagnosis of Cushing's syndrome: an Endocrine Society Clinical Practice Guideline. *Journal of Clinical Endocrinology and Metabolism* 2008 **93** 1526–1540. (doi:10.1210/jc.2008-0125)
- 72 Lenders JW, Duh QY, Eisenhofer G, Gimenez-Roqueplo AP, Grebe SK, Murad MH, Naruse M, Pacak K & Young WF Jr. Pheochromocytoma and paraganglioma: an endocrine society clinical practice guideline. *Journal of Clinical Endocrinology and Metabolism* 2014 **99** 1915–1942. (doi:10.1210/jc.2014-1498)
- 73 Bollerslev J, Rejnmark L, Marcocci C, Shoback DM, Sitges-Serra A, van Biesen W & Dekkers OM. European Society of Endocrinology Clinical guideline: treatment of chronic hypoparathyroidism in adults. *European Journal of Endocrinology* 2015 **173** G1–G20. (doi:10.1530/EJE-15-0628)
- 74 Hammarstedt L, Muth A, Wangberg B, Bjorneld L, Sigurjonsdottir HA, Gotheerstrom G, Almquist E, Widell H, Carlsson S, Ander S *et al.* Adrenal lesion frequency: a prospective, cross-sectional CT study in a defined region, including systematic re-evaluation. *Acta Radiologica* 2010 **51** 1149–1156.
- 75 Andrews JC, Schunemann HJ, Oxman AD, Pottie K, Meerpohl JJ, Coello PA, Rind D, Montori VM, Brito JP, Norris S *et al.* GRADE guidelines: 15. Going from evidence to recommendation—determinants of a recommendation's direction and strength. *Journal of Clinical Epidemiology* 2013 **66** 726–735. (doi:10.1016/j.jclinepi.2013.02.003)
- 76 Ferreira EV, Czepielewski MA, Faccin CS, Accordi MC & Furtado AP. [Prevalence of adrenal incidentaloma at computed tomography (chest and abdominal) in a general hospital in Brazil]. *Arquivos Brasileiros de Endocrinologia & Metabologia* 2005 **49** 769–775.
- 77 Dinnes J, Bancos I, Ferrante di Ruffano L, Chortis V, Davenport C, Bayliss S, Sahdev A, Guest P, Fassnacht M & Deeks JJ *et al.* Imaging for the diagnosis of malignancy in incidentally discovered adrenal masses – a systematic review and meta-analysis. *European Journal of Endocrinology* 2016. In press (doi:10.1530/EJE-16-0461)
- 78 Bancos I, Tamhane S, Shah M, Delivanis DA, Alahdad F, Arlt W, Fassnacht M & Murad MH. The diagnostic performance of adrenal biopsy: a systematic review and meta-analysis. *European Journal of Endocrinology* 2016. In Press. (doi:10.1530/EJE-16-0297)
- 79 Angelelli G, Mancini ME, Moschetta M, Pedote P, Pignataro P & Scardapane A. MDCT in the differentiation of adrenal masses: comparison between different scan delays for the evaluation of intralesional washout. *Scientific World Journal* 2013 **2013** 957680.
- 80 Marin D, Dale BM, Bashir MR, Ziemlewicz TJ, Ringe KI, Boll DT & Merkle EM. Effectiveness of a three-dimensional dual gradient echo two-point Dixon technique for the characterization of adrenal lesions at 3 Tesla. *European Radiology* 2012 **22** 259–268. (doi:10.1007/s00330-011-2244-x)

- 81 Maurea S, Caraco C, Klain M, Mainolfi C & Salvatore M. Imaging characterization of non-hypersecreting adrenal masses. Comparison between MR and radionuclide techniques. *Quarterly Journal of Nuclear Medicine and Molecular Imaging* 2004 **48** 188–197.
- 82 Nunes ML, Rault A, Teynie J, Valli N, Guyot M, Gaye D, Belleannee G & Tabarin A. 18F-FDG PET for the identification of adrenocortical carcinomas among indeterminate adrenal tumors at computed tomography scanning. *World Journal of Surgery* 2010 **34** 1506–1510. (doi:10.1007/s00268-010-0576-3)
- 83 Sandrasegaran K, Patel AA, Ramaswamy R, Samuel VP, Northcutt BG, Frank MS & Francis IR. Characterization of adrenal masses with diffusion-weighted imaging. *American Journal of Roentgenology* 2011 **197** 132–138. (doi:10.2214/AJR.10.4583)
- 84 Tessonnier L, Sebag F, Palazzo FF, Colavolpe C, De Micco C, Mancini J, Conte-Devolx B, Henry JF, Mundler O & Taieb D. Does 18F-FDG PET/CT add diagnostic accuracy in incidentally identified non-secreting adrenal tumours? *European Journal of Nuclear Medicine and Molecular Imaging* 2008 **35** 2018–2025. (doi:10.1007/s00259-008-0849-3)
- 85 Vilar L, Freitas Mda C, Canadas V, Albuquerque JL, Botelho CA, Egito CS, Arruda MJ, Moura e Silva L, Coelho CE, Casulari LA et al. Adrenal incidentalomas: diagnostic evaluation and long-term follow-up. *Endocrine Practice* 2008 **14** 269–278. (doi:10.4158/EP.14.3.269)
- 86 Burt M, Heelan RT, Coit D, McCormack PM, Bains MS, Martini N, Rusch V & Ginsberg RJ. Prospective evaluation of unilateral adrenal masses in patients with operable non-small-cell lung cancer. Impact of magnetic resonance imaging. *Journal of Thoracic and Cardiovascular Surgery* 1994 **107** 584–588.
- 87 Choi YA, Kim CK, Park BK & Kim B. Evaluation of adrenal metastases from renal cell carcinoma and hepatocellular carcinoma: use of delayed contrast-enhanced CT. *Radiology* 2013 **266** 514–520. (doi:10.1148/radiol.12120110)
- 88 Frilling A, Tecklenborg K, Weber F, Kuhl H, Muller S, Stamatis G & Broelsch C. Importance of adrenal incidentaloma in patients with a history of malignancy. *Surgery* 2004 **136** 1289–1296.
- 89 Lang BH, Cowling BJ, Li JY, Wong KP & Wan KY. High false positivity in positron emission tomography is a potential diagnostic pitfall in patients with suspected adrenal metastasis. *World Journal of Surgery* 2015 **39** 1902–1908.
- 90 Porte HL, Ernst OJ, Delebecq T, Metois D, Lemaitre LG & Wurtz AJ. Is computed tomography guided biopsy still necessary for the diagnosis of adrenal masses in patients with resectable non-small-cell lung cancer? *European Journal of Cardio-Thoracic Surgery* 1999 **15** 597–601. (doi:10.1016/S1010-7940(99)00047-0)
- 91 Ream JM, Gaing B, Mussi TC & Rosenkrantz AB. Characterization of adrenal lesions at chemical-shift MRI: a direct intraindividual comparison of in- and opposed-phase imaging at 1.5 T and 3 T. *American Journal of Roentgenology* 2015 **204** 536–541. (doi:10.2214/AJR.14.12941)
- 92 Schwartz LH, Panicek DM, Koutcher JA, Brown KT, Getrajdman GI, Heelan RT & Burt M. Adrenal masses in patients with malignancy: prospective comparison of echo-planar, fast spin-echo, and chemical shift MR imaging. *Radiology* 1995 **197** 421–425. (doi:10.1148/radiology.197.2.7480686)
- 93 Uemura S, Yasuda I, Kato T, Doi S, Kawaguchi J, Yamauchi T, Kaneko Y, Ohnishi R, Suzuki T, Yasuda S et al. Preoperative routine evaluation of bilateral adrenal glands by endoscopic ultrasound and fine-needle aspiration in patients with potentially resectable lung cancer. *Endoscopy* 2013 **45** 195–201. (doi:10.1055/s-00000012)
- 94 Kunikowska J, Matyskiel R, Toutouchi S, Grabowska-Derlatka L, Koperski L & Krollicki L. What parameters from 18F-FDG PET/CT are useful in evaluation of adrenal lesions? *European Journal of Nuclear Medicine and Molecular Imaging* 2014 **41** 2273–2280. (doi:10.1007/s00259-014-2844-1)
- 95 Villar Del Moral JM, Munoz Perez N, Rodriguez Fernandez A, Olmos Juarez E, Moreno Cortes C, Rodriguez Gonzalez R, Martin Cano FJ, Sanchez Sanchez R & Ferron Orihuela JA. [Diagnostic efficacy and discriminatory capacity of positron emission tomography combined with axial tomography of adrenal lesions]. *Cirugía Española* 2010 **88** 247–252.
- 96 Aksakal N, Sahbaz A, Ozcinar B, Ozemir A, Caglayan K, Agcaoglu O, Barbaros U, Salmaslioglu A & Erbil Y. Nonfunctional adrenal lesions without loss of signal intensity on MRI: whose problem is it? The patient's? The surgeon's? *International Journal of Surgery* 2013 **11** 169–172. (doi:10.1016/j.ijso.2012.12.014)
- 97 Bilbey JH, McLoughlin RF, Kurkjian PS, Wilkins GE, Chan NH, Schmidt N & Singer J. MR imaging of adrenal masses: value of chemical-shift imaging for distinguishing adenomas from other tumors. *American Journal of Roentgenology* 1995 **164** 637–642. (doi:10.2214/ajr.164.3.7863885)
- 98 Boraschi P, Braccini G, Gigoni R, Perri G, Campatelli A, Di Vito A & Bonadio AG. Diagnosis of adrenal adenoma: value of central spot of high-intensity hyperintense rim sign and homogeneous isointensity to liver on gadolinium-enhanced fat-suppressed spin-echo MR images. *Journal of Magnetic Resonance Imaging* 1999 **9** 304–310. (doi:10.1002/(ISSN)1522-2586)
- 99 Chung JJ, Semelka RC & Martin DR. Adrenal adenomas: characteristic postgadolinium capillary blush on dynamic MR imaging. *Journal of Magnetic Resonance Imaging* 2001 **13** 242–248. (doi:10.1002/1522-2586(200102)13:2<242::AID-JMRI1035>3.3.CO;2-R)
- 100 Gust L, Taieb D, Beliard A, Barlier A, Morange I, de Micco C, Henry JF & Sebag F. Preoperative 18F-FDG uptake is strongly correlated with malignancy, Weiss score, and molecular markers of aggressiveness in adrenal cortical tumors. *World Journal of Surgery* 2012 **36** 1406–1410. (doi:10.1007/s00268-011-1374-2)
- 101 Ichikawa T, Fujimoto H, Murakami K, Tauchi M, Mochizuki S, Ohtomo K & Uchiyama G. Adrenal tissue characterization with 0.5-T MR imaging: value of T2\*-weighted images. *Journal of Magnetic Resonance Imaging* 1993 **3** 742–745. (doi:10.1002/(ISSN)1522-2586)
- 102 Kamiyama T, Fukukura Y, Yoneyama T, Takumi K & Nakajo M. Distinguishing adrenal adenomas from nonadenomas: combined use of diagnostic parameters of unenhanced and short 5-minute dynamic enhanced CT protocol. *Radiology* 2009 **250** 474–481. (doi:10.1148/radiol.2502080302)
- 103 Kebapci M, Kaya T, Gurbuz E, Adapinar B, Kebapci N & Demirustu C. Differentiation of adrenal adenomas (lipid rich and lipid poor) from nonadenomas by use of washout characteristics on delayed enhanced CT. *Abdominal Imaging* 2003 **28** 709–715. (doi:10.1007/s00261-003-0015-0)
- 104 Launay N, Silvera S, Tenenbaum F, Groussin L, Tissier F, Audureau E, Vignaux O, Dousset B, Bertagna X & Legmann P. Value of 18-F-FDG PET/CT and CT in the diagnosis of indeterminate adrenal masses. *International Journal of Endocrinology* 2015 **2015** 213875.
- 105 Mayo-Smith WW, Lee MJ, McNicholas MM, Hahn PF, Boland GW & Saini S. Characterization of adrenal masses (<5 cm) by use of chemical shift MR imaging: observer performance versus quantitative measures. *American Journal of Roentgenology* 1995 **165** 91–95.
- 106 Nwariaku FE, Champine J, Kim LT, Burkey S, O'Keefe G & Snyder WH 3rd. Radiologic characterization of adrenal masses: the role of computed tomography – derived attenuation values. *Surgery* 2001 **130** 1068–1071. (doi:10.1067/msy.2001.119189)
- 107 Park SY, Park BK, Park JJ & Kim CK. CT sensitivities for large (>=3 cm) adrenal adenoma and cortical carcinoma. *Abdominal Imaging* 2015 **40** 310–317. (doi:10.1007/s00261-014-0202-1)
- 108 Park SH, Kim MJ, Kim JH, Lim JS & Kim KW. Differentiation of adrenal adenoma and nonadenoma in unenhanced CT: new optimal threshold value and the usefulness of size criteria for differentiation.

- Korean Journal of Radiology* 2007 **8** 328–335. (doi:10.3348/kjr.2007.8.4.328)
- 109 Petersenn S, Richter PA, Broemel T, Ritter CO, Deutschbein T, Beil FU, Allolio B & Fassnacht M. Computed tomography criteria for discrimination of adrenal adenomas and adrenocortical carcinomas: analysis of the German ACC registry. *European Journal of Endocrinology* 2015 **172** 415–422. (doi:10.1530/EJE-14-0916)
- 110 Remer EM, Motta-Ramirez GA, Shepardson LB, Hamrahian AH & Herts BR. CT histogram analysis in pathologically proven adrenal masses. *American Journal of Roentgenology* 2006 **187** 191–196. (doi:10.2214/AJR.05.0179)
- 111 Zetting G, Mitterhauser M, Wadsak W, Becherer A, Pirich C, Vierhapper H, Niederle B, Dudczak R & Kletter K. Positron emission tomography imaging of adrenal masses: (18)F-fluorodeoxyglucose and the 11beta-hydroxylase tracer (11)C-metomidate. *European Journal of Nuclear Medicine and Molecular Imaging* 2004 **31** 1224–1230.
- 112 Zielonko J, Studniarek M, Rzepko R, Babinska A & Siekierska-Hellmann M. Value of MRI in differentiating adrenal masses: quantitative analysis of tumor signal intensity. *Polish Journal of Radiology/Polish Medical Society of Radiology* 2008 **73** 7–12.
- 113 Deville WL, Buntinx F, Bouter LM, Montori VM, de Vet HC, van der Windt DA & Bezemer PD. Conducting systematic reviews of diagnostic studies: didactic guidelines. *BMC Medical Research Methodology* 2002 **2** 9. (doi:10.1186/1471-2288-2-9)
- 114 Macaskill P, Gatsonis C, Deeks JJ, Harbord RM & Takwoingi Y. Analysing and presenting results. In *Cochrane Handbook for Systematic Reviews of Diagnostic Test Accuracy. Version 10*, ch 10. Eds JJ Deeks, PM Bossuyt & C Gatsonis. The Cochrane Collaboration, 2010. Available from: <http://srdta.cochrane.org/>.
- 115 Moher D, Liberati A, Tetzlaff J & Altman DG. Preferred reporting items for systematic reviews and meta-analyses: the PRISMA statement. *Open Medicine* 2009 **3** e123–e130.
- 116 Silverman SG, Mueller PR, Pinkney LP, Koenker RM & Seltzer SE. Predictive value of image-guided adrenal biopsy: analysis of results of 101 biopsies. *Radiology* 1993 **187** 715–718. (doi:10.1148/radiology.187.3.8497619)
- 117 Puri R, Thandassery RB, Choudhary NS, Kotecha H, Misra SR, Bhagat S, Paliwal M, Madan K, Saraf N, Sarin H *et al*. Endoscopic ultrasound-guided fine-needle aspiration of the adrenal glands: analysis of 21 patients. *Clinical Endocrinology* 2015 **48** 165–170. (doi:10.5946/ce.2015.48.2.165)
- 118 Martinez M, LeBlanc J, Al-Haddad M, Sherman S & DeWitt J. Role of endoscopic ultrasound fine-needle aspiration evaluating adrenal gland enlargement or mass. *World Journal of Nephrology* 2014 **3** 92–100. (doi:10.5527/wjn.v3.i3.92)
- 119 Welch TJ, Sheedy PF 2nd, Stephens DH, Johnson CM & Swensen SJ. Percutaneous adrenal biopsy: review of a 10-year experience. *Radiology* 1994 **193** 341–344. (doi:10.1148/radiology.193.2.7972740)
- 120 Rana C, Krishnani N & Kumari N. Spectrum of adrenal lesions on fine needle aspiration cytology. *Indian Journal of Pathology & Microbiology* 2012 **55** 461–466.
- 121 Mody MK, Kazerooni EA & Korobkin M. Percutaneous CT-guided biopsy of adrenal masses: immediate and delayed complications. *Journal of Computer Assisted Tomography* 1995 **19** 434–439. (doi:10.1097/00004728-199505000-00017)
- 122 Hussain S. Gantry angulation in CT-guided percutaneous adrenal biopsy. *American Journal of Roentgenology* 1996 **166** 537–539. (doi:10.2214/ajr.166.3.8623623)
- 123 Wu HH, Cramer HM, Kho J & Elsheikh TM. Fine needle aspiration cytology of benign adrenal cortical nodules. A comparison of cytologic findings with those of primary and metastatic adrenal malignancies. *Acta Cytologica* 1998 **42** 1352–1358. (doi:10.1159/000332167)
- 124 Schwartz LH, Ginsberg MS, Burt ME, Brown KT, Getrajdman GI & Panicek DM. MRI as an alternative to CT-guided biopsy of adrenal masses in patients with lung cancer. *Annals of Thoracic Surgery* 1998 **65** 193–197. (doi:10.1016/S0003-4975(97)01038-2)
- 125 de Agustin P, Lopez-Rios F, Alberti N & Perez-Barrios A. Fine-needle aspiration biopsy of the adrenal glands: a ten-year experience. *Diagnostic Cytopathology* 1999 **21** 92–97. (doi:10.1002/(ISSN)1097-0339)
- 126 Lumachi F, Borsato S, Brandes AA, Boccagni P, Tregnaghi A, Angelini F & Favia G. Fine-needle aspiration cytology of adrenal masses in noncancer patients: clinicoradiologic and histologic correlations in functioning and nonfunctioning tumors. *Cancer* 2001 **93** 323–329. (doi:10.1002/cncr.9047)
- 127 Lumachi F, Borsato S, Tregnaghi A, Basso SM, Marchesi P, Ciarleglio F, Fassina A & Favia G. CT-scan, MRI and image-guided FNA cytology of incidental adrenal masses. *European Journal of Surgical Oncology* 2003 **29** 689–692.
- 128 Paulsen SD, Nghiem HV, Korobkin M, Caoili EM & Higgins EJ. Changing role of imaging-guided percutaneous biopsy of adrenal masses: evaluation of 50 adrenal biopsies. *American Journal of Roentgenology* 2004 **182** 1033–1037. (doi:10.2214/ajr.182.4.1821033)
- 129 Kocijancic K, Kocijancic I & Guna F. Role of sonographically guided fine-needle aspiration biopsy of adrenal masses in patients with lung cancer. *Journal of Clinical Ultrasound* 2004 **32** 12–16. (doi:10.1002/(ISSN)1097-0096)
- 130 Lucchi M, Dini P, Ambrogi MC, Berti P, Materazzi G, Miccoli P & Mussi A. Metachronous adrenal masses in resected non-small cell lung cancer patients: therapeutic implications of laparoscopic adrenalectomy. *European Journal of Cardio-Thoracic Surgery* 2005 **27** 753–756. (doi:10.1016/j.ejcts.2005.01.047)
- 131 Lumachi F, Borsato S, Tregnaghi A, Marino F, Fassina A, Zucchetta P, Marzola MC, Cecchin D, Bui F, Iacobone M *et al*. High risk of malignancy in patients with incidentally discovered adrenal masses: accuracy of adrenal imaging and image-guided fine-needle aspiration cytology. *Tumori* 2007 **93** 269–274.
- 132 Quayle FJ, Spittler JA, Pierce RA, Lairmore TC, Moley JF & Brunt LM. Needle biopsy of incidentally discovered adrenal masses is rarely informative and potentially hazardous. *Surgery* 2007 **142** 497–502. (doi:10.1016/j.surg.2007.07.013)
- 133 Tsitouridis I, Michaelides M, Stratilati S, Sidiropoulos D, Bintoudi A & Rodokalakos G. CT guided percutaneous adrenal biopsy for lesions with equivocal findings in chemical shift MR imaging. *Hippokratia* 2008 **12** 37–42.
- 134 Osman Y, El-Mekresh M, Gomha AM, Mohsen T, Taha N, Hussein N & Eraky I. Percutaneous adrenal biopsy for indeterminate adrenal lesion: complications and diagnostic accuracy. *Urologia Internationalis* 2010 **84** 315–318. (doi:10.1159/000288235)
- 135 Mazzaglia PJ & Monchik JM. Limited value of adrenal biopsy in the evaluation of adrenal neoplasm: a decade of experience. *Archives of Surgery* 2009 **144** 465–470. (doi:10.1001/archsurg.2009.59)
- 136 Bodtger U, Vilmann P, Clementsen P, Galvis E, Bach K & Skov BG. Clinical impact of endoscopic ultrasound-fine needle aspiration of left adrenal masses in established or suspected lung cancer. *Journal of Thoracic Oncology* 2009 **4** 1485–1489.
- 137 Eloubeidi MA, Black KR, Tamhane A, Eltoun IA, Bryant A & Cerfolio RJ. A large single-center experience of EUS-guided FNA of the left and right adrenal glands: diagnostic utility and impact on patient management. *Gastrointestinal Endoscopy* 2010 **71** 745–753. (doi:10.1016/j.gie.2009.10.022)
- 138 Schuurbiens OC, Tournoy KG, Schoppers HJ, Dijkman BG, Timmers HJ, de Geus-Oei LF, Grefte JM, Rabe KF, Dekhuijzen PN, van der Heijden HF *et al*. EUS-FNA for the detection of left adrenal metastasis in patients with lung cancer. *Lung Cancer* 2011 **73** 310–315. (doi:10.1016/j.lungcan.2010.12.019)
- 139 Tyng CJ, Bitencourt AG, Martins EB, Pinto PN & Chojniak R. Technical note: CT-guided paravertebral adrenal biopsy using hydrodissection – a safe and technically easy approach. *British Journal of Radiology* 2012 **85** e339–e342.

- 140 Tirabassi G, Kola B, Ferretti M, Papa R, Mancini T, Mantero F, Scarpelli M, Boscaro M & Arnaldi G. Fine-needle aspiration cytology of adrenal masses: a re-assessment with histological confirmation. *Journal of Endocrinological Investigation* 2012 **35** 590–594.
- 141 Androulakis II, Kaltsas GA, Kollias GE, Markou AC, Gouli AK, Thomas DA, Alexandraki KI, Papamichael CM, Hadjidakis DJ & Piaditis GP. Patients with apparently nonfunctioning adrenal incidentalomas may be at increased cardiovascular risk due to excessive cortisol secretion. *Journal of Clinical Endocrinology and Metabolism* 2014 **99** 2754–2762. (doi:10.1210/jc.2013-4064)
- 142 Olsen H, Nordenstrom E, Bergenfelz A, Nyman U, Valdemarsson S, Palmqvist E, Olsen H, Nordenstrom E, Bergenfelz A, Nyman U *et al.* Subclinical hypercortisolism and CT appearance in adrenal incidentalomas: a multicenter study from Southern Sweden. *Endocrine* 2012 **42** 164–173. (doi:10.1007/s12020-012-9622-2)
- 143 Vassilatou E, Vryonidou A, Ioannidis D, Paschou SA, Panagou M & Tzavara I. Bilateral adrenal incidentalomas differ from unilateral adrenal incidentalomas in subclinical cortisol hypersecretion but not in potential clinical implications. *European Journal of Endocrinology* 2014 **171** 37–45. (doi:10.1530/EJE-13-0848)
- 144 Debono M, Bradburn M, Bull M, Harrison B, Ross RJ & Newell-Price J. Cortisol as a marker for increased mortality in patients with incidental adrenocortical adenomas. *Journal of Clinical Endocrinology and Metabolism* 2014 **99** 4462–4470. (doi:10.1210/jc.2014-3007)
- 145 Di Dalmazi G, Vicennati V, Garelli S, Casadio E, Rinaldi E, Giampalma E, Mosconi C, Golfieri R, Paccapelo A, Pagotto U *et al.* Cardiovascular events and mortality in patients with adrenal incidentalomas that are either non-secreting or associated with intermediate phenotype or subclinical Cushing's syndrome: a 15-year retrospective study. *Lancet Diabetes & Endocrinology* 2014 **2** 396–405.
- 146 Morelli V, Reimondo G, Giordano R, Della CS, Policola C, Palmieri S, Salcuni AS, Dolci A, Mendola M, Arosio M *et al.* Long-term follow-up in adrenal incidentalomas: an Italian multicenter study. *Journal of Clinical Endocrinology and Metabolism* 2014 **99** 827–834. (doi:10.1210/jc.2013-3527)
- 147 Vassilatou E, Vryonidou A, Michalopoulou S, Manolis J, Caratzas J, Phenekos C & Tzavara I. Hormonal activity of adrenal incidentalomas: results from a long-term follow-up study. *Clinical Endocrinology* 2009 **70** 674–679. (doi:10.1111/cen.2009.70.issue-5)
- 148 Toniato A, Merante-Boschin I, Opocher G, Pelizzo MR, Schiavi F & Ballotta E. Surgical versus conservative management for subclinical Cushing syndrome in adrenal incidentalomas: a prospective randomized study. *Annals of Surgery* 2009 **249** 388–391. (doi:10.1097/SLA.0b013e31819a47d2)
- 149 Tsuiki M, Tanabe A, Takagi S, Naruse M & Takano K. Cardiovascular risks and their long-term clinical outcome in patients with subclinical Cushing's syndrome. *Endocrine Journal* 2008 **55** 737–745. (doi:10.1507/endocrj.K07E-177)
- 150 Iacobone M, Citton M, Viel G, Boetto R, Bonadio I, Mondì I, Tropea S, Nitti D & Favia G. Adrenalectomy may improve cardiovascular and metabolic impairment and ameliorate quality of life in patients with adrenal incidentalomas and subclinical Cushing's syndrome. *Surgery* 2012 **152** 991–997. (doi:10.1016/j.surg.2012.08.054)
- 151 Brix D, Allolio B, Fenske W, Agha A, Dralle H, Jurowich C, Langer P, Mussack T, Nies C, Riedmiller H *et al.* Laparoscopic versus open adrenalectomy for adrenocortical carcinoma: surgical and oncologic outcome in 152 patients. *European Urology* 2010 **58** 609–615. (doi:10.1016/j.eururo.2010.06.024)
- 152 Cooper AB, Habra MA, Grubbs EG, Bednarski BK, Ying AK, Perrier ND, Lee JE & Aloia TA. Does laparoscopic adrenalectomy jeopardize oncologic outcomes for patients with adrenocortical carcinoma? *Surgical Endoscopy* 2013 **27** 4026–4032. (doi:10.1007/s00464-013-3034-0)
- 153 Donatini G, Caiazzo R, Do CC, Aubert S, Zerrweck C, El-Kathib Z, Gauthier T, Leteurtre E, Wemeau JL, Vantyghem MC *et al.* Long-term survival after adrenalectomy for stage I/II adrenocortical carcinoma (ACC): a retrospective comparative cohort study of laparoscopic versus open approach. *Annals of Surgical Oncology* 2014 **21** 284–291. (doi:10.1245/s10434-013-3164-6)
- 154 Fossa A, Rosok BI, Kazaryan AM, Holte HJ, Brennhovd B, Westerheim O, Marangos IP & Edwin B. Laparoscopic versus open surgery in stage I-III adrenocortical carcinoma – a retrospective comparison of 32 patients. *Acta Oncologica* 2013 **52** 1771–1777. (doi:10.3109/0284186X.2013.765065)
- 155 Lombardi CP, Raffaelli M, De CC, Boniardi M, De TG, Marzano LA, Miccoli P, Minni F, Morino M, Pelizzo MR *et al.* Open versus endoscopic adrenalectomy in the treatment of localized (stage I/II) adrenocortical carcinoma: results of a multiinstitutional Italian survey. *Surgery* 2012 **152** 1158–1164.
- 156 Miller BS, Ammori JB, Gauger PG, Broome JT, Hammer GD & Doherty GM. Laparoscopic resection is inappropriate in patients with known or suspected adrenocortical carcinoma. *World Journal of Surgery* 2010 **34** 1380–1385.
- 157 Miller BS, Gauger PG, Hammer GD & Doherty GM. Resection of adrenocortical carcinoma is less complete and local recurrence occurs sooner and more often after laparoscopic adrenalectomy than after open adrenalectomy. *Surgery* 2012 **152** 1150–1157.
- 158 Mir MC, Klink JC, Guillotreau J, Long JA, Miocinovic R, Kaouk JH, Simmons MN, Klein E, Krishnamurthi V, Campbell SC *et al.* Comparative outcomes of laparoscopic and open adrenalectomy for adrenocortical carcinoma: single, high-volume center experience. *Annals of Surgical Oncology* 2013 **20** 1456–1461.
- 159 Porpiglia F, Fiori C, Daffara F, Zaggia B, Bollito E, Volante M, Berruti A & Terzolo M. Retrospective evaluation of the outcome of open versus laparoscopic adrenalectomy for stage I and II adrenocortical cancer. *European Urology* 2010 **57** 873–878. (doi:10.1016/j.eururo.2010.01.036)
- 160 Cho YY, Suh S, Joung JY, Jeong H, Je D, Yoo H, Park TK, Min YK, Kim KW & Kim JH. Clinical characteristics and follow-up of Korean patients with adrenal incidentalomas. *Korean Journal of Internal Medicine* 2013 **28** 557–564. (doi:10.3904/kjim.2013.28.5.557)
- 161 Comlekci A, Yener S, Ertilav S, Secil M, Akinci B, Demir T, Kebapcilar L, Bayraktar F, Yesil S & Eraslan S. Adrenal incidentaloma, clinical, metabolic, follow-up aspects: single centre experience. *Endocrine* 2010 **37** 40–46. (doi:10.1007/s12020-009-9260-5)
- 162 Debono M, Prema A, Hughes TJ, Bull M, Ross RJ & Newell-Price J. Visceral fat accumulation and postdexamethasone serum cortisol levels in patients with adrenal incidentaloma. *Journal of Clinical Endocrinology and Metabolism* 2013 **98** 2383–2391. (doi:10.1210/jc.2012-4276)
- 163 Kim HY, Kim SG, Lee KW, Seo JA, Kim NH, Choi KM, Baik SH & Choi DS. Clinical study of adrenal incidentaloma in Korea. *Korean Journal of Internal Medicine* 2005 **20** 303–309. (doi:10.3904/kjim.2005.20.4.303)
- 164 Muth A, Hammarstedt L, Hellstrom M, Sigurjonsdottir HA, Almqvist E, Wangberg B & Adrenal Study Group of Western Sweden. Cohort study of patients with adrenal lesions discovered incidentally. *British Journal of Surgery* 2011 **98** 1383–1391. (doi:10.1002/bjs.7566)
- 165 Muth A, Taft C, Hammarstedt L, Bjorneld L, Hellstrom M & Wangberg B. Patient-reported impacts of a conservative management programme for the clinically inapparent adrenal mass. *Endocrine* 2013 **44** 228–236. (doi:10.1007/s12020-012-9856-z)
- 166 Song JH, Chaudhry FS & Mayo-Smith WW. The incidental adrenal mass on CT: prevalence of adrenal disease in 1,049 consecutive adrenal masses in patients with no known malignancy. *American Journal of Roentgenology* 2008 **190** 1163–1168. (doi:10.2214/AJR.07.2799)



- 167 Yener S, Ertilav S, Secil M, Akinci B, Demir T, Comlekci A & Yesil S. Natural course of benign adrenal incidentalomas in subjects with extra-adrenal malignancy. *Endocrine* 2009 **36** 135–140. (doi:10.1007/s12020-009-9191-1)
- 168 Tsvetov G, Shimon I & Benbassat C. Adrenal incidentaloma: clinical characteristics and comparison between patients with and without extraadrenal malignancy. *Journal of Endocrinological Investigation* 2007 **30** 647–652. (doi:10.1007/BF03347444)
- 169 Park HS, Roman SA & Sosa JA. Outcomes from 3144 adrenalectomies in the United States: which matters more, surgeon volume or specialty? *Archives of Surgery* 2009 **144** 1060–1067. (doi:10.1001/archsurg.2009.191)
- 170 Kerkhofs TM, Verhoeven RH, Bonjer HJ, van Dijkum EJ, Vriens MR, De Vries J, Van Eijck CH, Bonsing BA, Van de Poll-Franse LV & Haak HR. Surgery for adrenocortical carcinoma in The Netherlands: analysis of the national cancer registry data. *European Journal of Endocrinology* 2013 **169** 83–89. (doi:10.1530/EJE-13-0142)
- 171 Lombardi CP, Raffaelli M, Boniardi M, De Toma G, Marzano LA, Miccoli P, Minni F, Morino M, Pelizzo MR, Pietrabissa A *et al.* Adrenocortical carcinoma: effect of hospital volume on patient outcome. *Langenbecks Archives of Surgery* 2012 **397** 201–207. (doi:10.1007/s00423-011-0866-8)
- 172 Rodacki K, Ramalho M, Dale BM, Battisti S, de Campos RO, Giardino A & Semelka RC. Combined chemical shift imaging with early dynamic serial gadolinium-enhanced MRI in the characterization of adrenal lesions. *American Journal of Roentgenology* 2014 **203** 99–106. (doi:10.2214/AJR.13.11731)
- 173 Seo JM, Park BK, Park SY & Kim CK. Characterization of lipid-poor adrenal adenoma: chemical-shift MRI and washout CT. *AJR. American Journal of Roentgenology* 2014 **202** 1043–1050.
- 174 Karam M, Novak L, Cyriac J, Ali A, Nazeer T & Nugent F. Role of fluorine-18 fluoro-deoxyglucose positron emission tomography scan in the evaluation and follow-up of patients with low-grade lymphomas. *Cancer* 2006 **107** 175–183. (doi:10.1002/(ISSN)1097-0142)
- 175 Tsukamoto N, Kojima M, Hasegawa M, Oriuchi N, Matsushima T, Yokohama A, Saitoh T, Handa H, Endo K & Murakami H. The usefulness of (18)F-fluorodeoxyglucose positron emission tomography ((18)F-FDG-PET) and a comparison of (18)F-FDG-pet with (67)gallium scintigraphy in the evaluation of lymphoma: relation to histologic subtypes based on the World Health Organization classification. *Cancer* 2007 **110** 652–659. (doi:10.1002/(ISSN)1097-0142)
- 176 Zukotynski K, Lewis A, O'Regan K, Jacene H, Sakellis C, Krajewski K & Israel D. PET/CT and renal pathology: a blind spot for radiologists? Part 1, primary pathology. *American Journal of Roentgenology* 2012 **199** W163–W167.
- 177 Ansquer C, Scigliano S, Mirallie E, Taieb D, Brunaud L, Sebag F, Leux C, Druil D, Dupas B, Renaudin K *et al.* 18F-FDG PET/CT in the characterization and surgical decision concerning adrenal masses: a prospective multicentre evaluation. *European Journal of Nuclear Medicine and Molecular Imaging* 2010 **37** 1669–1678. (doi:10.1007/s00259-010-1471-8)
- 178 Timmers HJ, Chen CC, Carrasquillo JA, Whatley M, Ling A, Havekes B, Eisenhofer G, Martiniova L, Adams KT & Pacak K. Comparison of 18F-fluoro-L-DOPA, 18F-fluoro-deoxyglucose, and 18F-fluorodopamine PET and 123I-MIBG scintigraphy in the localization of pheochromocytoma and paraganglioma. *Journal of Clinical Endocrinology and Metabolism* 2009 **94** 4757–4767. (doi:10.1210/jc.2009-1248)
- 179 Alencar GA, Fragoso MC, Yamaga LY, Lerario AM & Mendonca BB. (18)F-FDG-PET/CT imaging of ACTH-independent macronodular adrenocortical hyperplasia (AIMAH) demonstrating increased (18) F-FDG uptake. *Journal of Clinical Endocrinology and Metabolism* 2011 **96** 3300–3301. (doi:10.1210/jc.2011-1397)
- 180 Williams AR, Hammer GD & Else T. Transcutaneous biopsy of adrenocortical carcinoma is rarely helpful in diagnosis, potentially harmful, but does not affect patient outcome. *European Journal of Endocrinology* 2014 **170** 829–835. (doi:10.1530/EJE-13-1033)
- 181 Funder JW, Carey RM, Fardella C, Gomez-Sanchez CE, Mantero F, Stowasser M, Young WF Jr & Montori VM. Case detection, diagnosis, and treatment of patients with primary aldosteronism: an endocrine society clinical practice guideline. *Journal of Clinical Endocrinology and Metabolism* 2008 **93** 3266–3281. (doi:10.1210/jc.2008-0104)
- 182 Fassnacht M & Allolio B. Clinical management of adrenocortical carcinoma. *Best Practice & Research Clinical Endocrinology & Metabolism* 2009 **23** 273–289.
- 183 Fassnacht M, Kenn W & Allolio B. Adrenal tumors: how to establish malignancy? *Journal of Endocrinological Investigation* 2004 **27** 387–399. (doi:10.1007/BF03351068)
- 184 Libe R, Frattici A & Bertherat J. Adrenocortical cancer: pathophysiology and clinical management. *Endocrine-Related Cancer* 2007 **14** 13–28. (doi:10.1677/erc.1.01130)
- 185 Else T, Kim AC, Sabolch A, Raymond VM, Kandathil A, Caoili EM, Jolly S, Miller BS, Giordano TJ & Hammer GD. Adrenocortical carcinoma. *Endocrine Reviews* 2014 **35** 282–326. (doi:10.1210/er.2013-1029)
- 186 Haissaguerre M, Courel M, Caron P, Denost S, Dubessy C, Gosse P, Appavoupouille V, Belleanne G, Jullie ML, Montero-Hadjadje M *et al.* Normotensive incidentally discovered pheochromocytomas display specific biochemical, cellular, and molecular characteristics. *Journal of Clinical Endocrinology and Metabolism* 2013 **98** 4346–4354. (doi:10.1210/jc.2013-1844)
- 187 Erickson D, Kudva YC, Ebersold MJ, Thompson GB, Grant CS, van Heerden JA & Young WF Jr. Benign paragangliomas: clinical presentation and treatment outcomes in 236 patients. *Journal of Clinical Endocrinology and Metabolism* 2001 **86** 5210–5216. (doi:10.1210/jcem.86.11.8034)
- 188 Kopetschke R, Slisko M, Kilişli A, Tuschy U, Wallaschowski H, Fassnacht M, Venz M, Beuschlein F, Reincke M, Reisch N *et al.* Frequent incidental discovery of pheochromocytoma: data from a German cohort of 201 pheochromocytoma. *European Journal of Endocrinology* 2009 **161** 355–361. (doi:10.1530/EJE-09-0384)
- 189 Lafont M, Fagour C, Haissaguerre M, Darancette G, Wagner T, Corcuff JB & Tabarin A. Per-operative hemodynamic instability in normotensive patients with incidentally discovered pheochromocytomas. *Journal of Clinical Endocrinology and Metabolism* 2015 **100** 417–421. (doi:10.1210/jc.2014-2998)
- 190 Sane T, Schalin-Jantti C & Raade M. Is biochemical screening for pheochromocytoma in adrenal incidentalomas expressing low unenhanced attenuation on computed tomography necessary? *Journal of Clinical Endocrinology and Metabolism* 2012 **97** 2077–2083. (doi:10.1210/jc.2012-1061)
- 191 Schalin-Jantti C, Raade M, Hamalainen E & Sane T. A 5-year prospective follow-up study of lipid-rich adrenal incidentalomas: no tumor growth or development of hormonal hypersecretion. *Endocrinology and Metabolism* 2015 **30** 481–487. (doi:10.3803/EnM.2015.30.4.481)
- 192 Berruti A, Baudin E, Gelderblom H, Haak HR, Porpiglia F, Fassnacht M & Pentheroudakis G. Adrenal cancer: ESMO Clinical Practice Guidelines for diagnosis, treatment and follow-up. *Annals of Oncology* 2012 **23** (Supplement 7) vii131–vii138.
- 193 Fassnacht M, Kroiss M & Allolio B. Update in adrenocortical carcinoma. *Journal of Clinical Endocrinology and Metabolism* 2013 **98** 4551–4564. (doi:10.1210/jc.2013-3020)
- 194 Arlt W, Biehl M, Taylor AE, Hahner S, Libe R, Hughes BA, Schneider P, Smith DJ, Stiekema H, Krone N *et al.* Urine steroid metabolomics as a biomarker tool for detecting malignancy in adrenal tumors. *Journal of Clinical Endocrinology and Metabolism* 2011 **96** 3775–3784.

- 195 Kerkhofs TM, Kerstens MN, Kema IP, Willems TP & Haak HR. Diagnostic value of urinary steroid profiling in the evaluation of adrenal tumors. *Hormones and Cancer* 2015 **6** 168–175. (doi:10.1007/s12672-015-0224-3)
- 196 Eller-Vainicher C, Morelli V, Salcuni AS, Battista C, Torlontano M, Coletti F, Iorio L, Cairoli E, Beck-Peccoz P, Arosio M *et al.* Accuracy of several parameters of hypothalamic-pituitary-adrenal axis activity in predicting before surgery the metabolic effects of the removal of an adrenal incidentaloma. *European Journal of Endocrinology* 2010 **163** 925–935. (doi:10.1530/EJE-10-0602)
- 197 Bornstein SR, Allolio B, Arlt W, Barthel A, Don-Wauchope A, Hammer GD, Husebey ES, Merke DP, Murad MH, Stratakis CA *et al.* Management of primary adrenal insufficiency: an Endocrine Society Clinical Practice guideline. *Journal of Clinical Endocrinology and Metabolism* 2016 **101** 364–89. (doi:10.1210/jc.2015-1710)
- 198 Eisenhauer EA, Therasse P, Bogaerts J, Schwartz LH, Sargent D, Ford R, Dancey J, Arbuck S, Gwyther S, Mooney M *et al.* New response evaluation criteria in solid tumours: revised RECIST guideline (version 1.1). *European Journal of Cancer* 2009 **45** 228–247. (doi:10.1016/j.ejca.2008.10.026)
- 199 Nogueira TM, Lirov R, Cacioli EM, Lerario AM, Miller BS, Fragoso MC, Dunnick NR, Hammer GD & Else T. Radiographic characteristics of adrenal masses preceding the diagnosis of adrenocortical cancer. *Hormones and Cancer* 2015 **6** 176–181. (doi:10.1007/s12672-015-0225-2)
- 200 Ozsari L, Kutahyaloglu M, Elsayes KM, Vicens RA, Sircar K, Jazaerly T, Waguespack SG, Busaidy NL, Cabanillas ME, Dadu R *et al.* Preexisting adrenal masses in patients with adrenocortical carcinoma: clinical and radiological factors contributing to delayed diagnosis. *Endocrine* 2016 **51** 351–359. (doi:10.1007/s12020-015-0694-7)
- 201 Elamin MB, Murad MH, Mullan R, Erickson D, Harris K, Nadeem S, Ennis R, Erwin PJ & Montori VM. Accuracy of diagnostic tests for Cushing's syndrome: a systematic review and metaanalyses. *Journal of Clinical Endocrinology and Metabolism* 2008 **93** 1553–1562. (doi:10.1210/jc.2008-0139)
- 202 Jaresch S, Kornely E, Kley HK & Schlaghecke R. Adrenal incidentaloma and patients with homozygous or heterozygous congenital adrenal hyperplasia. *Journal of Clinical Endocrinology and Metabolism* 1992 **74** 685–689. (doi:10.1210/jcem.74.3.1311000)
- 203 Del Monte P, Bernasconi D, Bertolazzi L, Meozzi M, Badaracco B, Torre R & Marugo M. Increased 17 alpha-hydroxyprogesterone response to ACTH in silent adrenal adenoma: cause or effect? *Clinical Endocrinology* 1995 **42** 273–277. (doi:10.1111/j.1365-2265.1995.tb01875.x)
- 204 Castinetti F, Taieb D, Henry JF, Walz MK, Guerin C, Brue T, Conte-Devolx B, Neumann H & Sebag F. MANAGEMENT OF ENDOCRINE DISEASE: Outcome of adrenal sparing surgery in heritable pheochromocytoma. *European Journal of Endocrinology* 2016 **174** R9–R18. (doi:10.1530/EJE-15-0549)
- 205 Debillon E, Velayoudom-Cephise FL, Salenave S, Caron P, Chaffanjon P, Wagner T, Massoutier M, Lambert B, Benoit M, Young J *et al.* Unilateral Adrenalectomy as a first-line treatment of Cushing's syndrome in patients with Primary Bilateral Macronodular Adrenal Hyperplasia. *Journal of Clinical Endocrinology and Metabolism* 2015 **100** 4417–4424. (doi:10.1210/jc.2015-2662)
- 206 Perogamvros I, Vassiliadi DA, Karapanou O, Botoula E, Tzanela M & Tsagarakis S. Biochemical and clinical benefits of unilateral adrenalectomy in patients with subclinical hypercortisolism and bilateral adrenal incidentalomas. *European Journal of Endocrinology* 2015 **173** 719–725. (doi:10.1530/EJE-15-0566)
- 207 Young WF Jr, du Plessis H, Thompson GB, Grant CS, Farley DR, Richards ML, Erickson D, Vella A, Stanson AW, Carney JA *et al.* The clinical conundrum of corticotropin-independent autonomous cortisol secretion in patients with bilateral adrenal masses. *World Journal of Surgery* 2008 **32** 856–862. (doi:10.1007/s00268-007-9332-8)
- 208 Vassiliadi DA, Ntali G, Vicha E & Tsagarakis S. High prevalence of subclinical hypercortisolism in patients with bilateral adrenal incidentalomas: a challenge to management. *Clinical Endocrinology* 2011 **74** 438–444. (doi:10.1111/cen.2011.74.issue-4)
- 209 Vassiliadi DA, Ntali G, Stratigou T, Adali M & Tsagarakis S. Aberrant cortisol responses to physiological stimuli in patients presenting with bilateral adrenal incidentalomas. *Endocrine* 2011 **40** 437–444. (doi:10.1007/s12020-011-9490-1)
- 210 Bourdeau I, D'Amour P, Hamet P, Boutin JM & Lacroix A. Aberrant membrane hormone receptors in incidentally discovered bilateral macronodular adrenal hyperplasia with subclinical Cushing's syndrome. *Journal of Clinical Endocrinology and Metabolism* 2001 **86** 5534–5540. (doi:10.1210/jcem.86.11.8062)
- 211 Lacroix A. ACTH-independent macronodular adrenal hyperplasia. *Best Practice & Research Clinical Endocrinology & Metabolism* 2009 **23** 245–259.
- 212 Lacroix A, Baldacchino V, Bourdeau I, Hamet P & Tremblay J. Cushing's syndrome variants secondary to aberrant hormone receptors. *Trends in Endocrinology and Metabolism* 2004 **15** 375–382. (doi:10.1016/S1043-2760(04)00188-2)
- 213 Lacroix A, Bourdeau I, Lampron A, Mazzuco TL, Tremblay J & Hamet P. Aberrant G-protein coupled receptor expression in relation to adrenocortical overfunction. *Clinical Endocrinology* 2010 **73** 1–15. (doi:10.1111/j.1365-2265.2009.03689.x)
- 214 Lacroix A, Ndiaye N, Tremblay J & Hamet P. Ectopic and abnormal hormone receptors in adrenal Cushing's syndrome. *Endocrine Reviews* 2001 **22** 75–110. (doi:10.1210/edrv.22.1.0420)
- 215 Libe R, Coste J, Guignat L, Tissier F, Lefebvre H, Barrande G, Ajzenberg C, Tauveron I, Clauser E, Dousset B *et al.* Aberrant cortisol regulations in bilateral macronodular adrenal hyperplasia: a frequent finding in a prospective study of 32 patients with overt or subclinical Cushing's syndrome. *European Journal of Endocrinology* 2010 **163** 129–138. (doi:10.1530/EJE-10-0195)
- 216 Davenport C, Liew A, Doherty B, Win HH, Misran H, Hanna S, Kealy D, Al-Nooh F, Agha A, Thompson CJ *et al.* The prevalence of adrenal incidentaloma in routine clinical practice. *Endocrine* 2011 **40** 80–83. (doi:10.1007/s12020-011-9445-6)
- 217 Mannelli M, Dralle H & Lenders JW. Perioperative management of pheochromocytoma/paraganglioma: is there a state of the art? *Hormone and Metabolic Research* 2012 **44** 373–378. (doi:10.1055/s-0032-1306275)
- 218 Stolk RF, Bakx C, Mulder J, Timmers HJ & Lenders JW. Is the excess cardiovascular morbidity in pheochromocytoma related to blood pressure or to catecholamines? *Journal of Clinical Endocrinology and Metabolism* 2013 **98** 1100–1106. (doi:10.1210/jc.2012-3669)

---

Received 30 May 2016

Revised version received 30 May 2016

Accepted 2 June 2016