

An Expert Consensus Statement on Use of Adrenal Vein Sampling for the Subtyping of Primary Aldosteronism

Gian Paolo Rossi, Richard J. Auchus, Morris Brown, Jacques W.M. Lenders, Mitsuhide Naruse, Pierre Francois Plouin, Fumitoshi Satoh, William F. Young Jr

Abstract—Adrenal venous sampling is recommended by current guidelines to identify surgically curable causes of hyperaldosteronism but remains markedly underused. Key factors contributing to the poor use of adrenal venous sampling include the prevailing perceptions that it is a technically challenging procedure, difficult to interpret, and can be complicated by adrenal vein rupture. In addition, the lack of uniformly accepted standards for the performance of adrenal venous sampling contributes to its limited use. Hence, an international panel of experts working at major referral centers was assembled to provide updated advice on how to perform and interpret adrenal venous sampling. To this end, they were asked to use the PICO (Patient or Problem, Intervention, Control or comparison, Outcome) strategy to gather relevant information from the literature and to rely on their own experience. The level of evidence/recommendation was provided according to American Heart Association gradings whenever possible. A consensus was reached on several key issues, including the selection and preparation of the patients for adrenal venous sampling, the procedure for its optimal performance, and the interpretation of its results for diagnostic purposes even in the most challenging cases. (*Hypertension*. 2014;63:151-160.) • [Online Data Supplement](#)

Key Words: adrenal vein sampling ■ aldosterone ■ diagnosis ■ hyperaldosteronism ■ hypertension

Primary aldosteronism (PA) is highly prevalent among patients with drug-resistant hypertension¹ and may be diagnosed in >11% of the patients referred to specialized hypertension centers.² PA is also quite common, albeit usually unrecognized, in the unselected hypertensive patient population seen by general practitioners.³ Therefore, consensus exists that PA constitutes the most common endocrine form of hypertension. Compelling evidence indicates that PA carries an increased risk of damage to target organs of high blood pressure with ensuing cardiorenal complications.^{4,5} Accordingly, early identification of affected patients and early institution of specific treatment are keys for prevention of cardiovascular events and reversal of damage.^{5,6}

Most patients with PA have either bilateral idiopathic hyperplasia (idiopathic hyperaldosteronism [IHA]), optimally treated with lifelong mineralocorticoid receptor (MR) blockade (with spironolactone, canrenone, potassium canrenoate, or eplerenone), or a unilateral aldosterone-producing adenoma (APA), which may be treated with unilateral adrenalectomy.⁷ Hence, the distinction between the cases of PA attributable to IHA and those that are attributable to a unilateral

overproduction of aldosterone, largely represented by APA, is essential for selecting the most appropriate treatment.^{7,8} To this end, the current clinical practice guidelines advocate use of adrenal vein sampling (AVS) with measurement of plasma cortisol concentration (PCC) and plasma aldosterone concentration (PAC).^{7,9} However, even though AVS may appear as a straightforward diagnostic test,¹⁰⁻¹² it is used only in few centers worldwide. Even some major referral centers do not use AVS routinely as shown by a recent large survey, the Adrenal Vein Sampling International Study (AVIS).¹³ This underutilization is likely to be attributable to the misconception, largely based on anecdotal experiences and retrospective observational studies,¹² that AVS is technically challenging, invasive, risky, and not always necessary, despite abundant evidence to the contrary.¹³ Furthermore, the lack of accepted standards for the performance of AVS and of established criteria for interpretation of its results creates additional hesitancy for appropriate use in many patients with PA. Therefore, in spite of the guidelines recommendations,^{7,9} too many PA patients are denied curative adrenalectomy because of the lack of demonstration of lateralized aldosterone excess,¹³ or undergo adrenalectomy

Received July 28, 2013; first decision August 12, 2013; revision accepted September 25, 2013.

From the Department of Medicine–DIMED–Internal Medicine 4 University of Padova, Italy (G.P.R.); Division of Metabolism, Endocrinology, & Diabetes, Department of Internal Medicine, University of Michigan, Ann Arbor (R.J.A.); Clinical Pharmacology Unit, Department of Medicine, University of Cambridge, Cambridge, United Kingdom (M.B.); Department of Internal Medicine, Radboud University Nijmegen Medical Centre, Nijmegen, The Netherlands (J.W.M.L.); Department of Internal Medicine III, University Hospital Carl Gustav Carus, Dresden, Germany (J.W.M.L.); Department of Endocrinology, Metabolism, and Hypertension, National Hospital Organization Kyoto Medical Center, Kyoto, Japan (M.N.); Hypertension Unit, Hôpital Européen G. Pompidou, Paris, France (P.F.P.); Division of Nephrology, Endocrinology, and Vascular Medicine, Tohoku University Hospital, Sendai, Japan (F.S.); and Division of Endocrinology, Diabetes, Metabolism and Nutrition, Mayo Clinic, Mayo Clinic College of Medicine, Rochester, MN (W.F.Y.).

The online-only Data Supplement is available with this article at <http://hyper.ahajournals.org/lookup/suppl/doi:10.1161/HYPERTENSIONAHA.113.02097/-/DC1>.

Correspondence to Gian Paolo Rossi, Department of Medicine–DIMED–Internal Medicine 4, University Hospital, Via Giustiniani, 2, 35126 Padova, Italy. E-mail gianpaolo.rossi@unipd.it

© 2013 American Heart Association, Inc.

Hypertension is available at <http://hyper.ahajournals.org>

DOI: 10.1161/HYPERTENSIONAHA.113.02097

without such demonstration, which may result in removal of a functionally normal adrenal gland.^{7,14}

A panel of internationally recognized experts was therefore assembled with the aim of providing updated practical suggestions on how to select the patients for AVS, how to perform the procedure, and on how to interpret its results. They were asked to use the PICO (Patient or Problem, Intervention, Control or comparison, Outcome) strategy¹⁵ to gather relevant information from the literature using search terms (see Table S1 in the online-only Data Supplement) and to use the American Heart Association gradings of level of evidence/recommendation.¹⁶ Herein, we report the consensus that was reached on several issues concerning the performance and interpretation of AVS for the diagnosis of the surgically curable subtypes of PA.

Selection of Patients for AVS

AVS is an invasive and expensive test, and appropriate patient selection is essential. Because AVS is aimed at subtyping of PA and not at confirming this diagnosis, an unequivocal biochemical diagnosis of PA should be made before considering AVS. Multiple studies have shown that the accuracy of imaging tests, such as adrenal computed tomography (CT) and MRI, in localizing the source of aldosterone excess is poor because aldosterone-producing microadenomas and most bilateral lesions are CT- and MRI-undetectable.¹⁷ Therefore, in line with international experience that AVS helps to distinguish between unilateral and bilateral aldosterone excess, both the US Endocrine Society and the Japan Endocrine Society guidelines recommend that AVS be performed in all patients who have the diagnosis of PA and who want to pursue surgical management.^{7,9,17} As a prerequisite for adrenalectomy, AVS is not indicated where either the patient prefers lifelong medical treatment with an MR antagonist or the physician considers the risks of surgery to outweigh the benefits, for example, because of the patient's age. AVS is also not generally required if, in a patient with PA, surgery is already mandated by the size of the adenoma or other radiological features suspicious of adrenocortical carcinoma (Figure 1). On the premise that nonfunctioning adrenocortical adenoma (so-called incidentaloma) is infrequent in young people, another subgroup in which AVS might not be needed includes young patients (eg, <40

years of age) with marked PA of recent onset, as evidenced by spontaneous hypokalemia, and a clear-cut unilateral cortical adenoma on computed adrenal imaging.¹⁸ However, even for young patients, bilateral aldosterone secretion cannot be excluded without AVS. Moreover, young patients with a family history of hypertension and stroke before 50 years of age should undergo long polymerase chain reaction testing for familial hyperaldosteronism type I (FH-I, also known as glucocorticoid-remediable aldosteronism) before considering AVS. AVS is not indicated in those with proven FH-I or FH-III, the latter attributable to germline mutations in the KCNJ5 potassium channels.^{19,20} Moreover, unilateral aldosterone excess from a small CT-undetectable APA in the adrenal gland contralateral to a CT-detectable nonfunctioning adrenal mass cannot be reliably identified without AVS.

Several studies have documented preoperative characteristics associated with cure of hypertension following unilateral adrenalectomy. For example, surgical cure of hypertension has been associated with the following: young age,^{21,22} shorter duration of hypertension (eg, <5–10 years), fewer antihypertensive medications (eg, ≤2), higher preoperative blood pressure, preoperative normal renal function, body mass index ≤25 kg/m², female sex, lack of a family history of hypertension,^{23–26} and no evidence of vascular remodeling.²⁷ These preoperative characteristics serve to guide the clinician and the patient in discussing realistic expectations of surgical outcomes. Where health resources are limited, some selection policy may also be necessary to pre-empt the view that, if 5% of the hypertensive population has unilateral PA, the surgical approach is simply not feasible.^{28,29} Nearly all patients with unilateral PA benefit from the surgical approach as evidenced by improved hypertension control, even if hypertension is not cured,^{5,21–27} and by long-term regression of left ventricular hypertrophy.⁵ Realistically, in most public healthcare systems, priority will be given to (1) young patients, who are the most likely to become normotensive with adrenal surgery and gain the most in life-years off treatment and (2) the patients with resistant hypertension (or antihypertensive drug intolerance), whose absolute risk of cardiovascular complications is the highest. The latter patients are less likely to become normotensive with adrenal surgery, but nevertheless their blood pressure can become controlled and therefore their cardiovascular risk reduced.

Key Points

Patients with established PA should undergo AVS when adrenalectomy is considered. Exceptions are as follows:

- patients aged <40 years with marked PA and a clear unilateral adrenal adenoma and a normal contralateral adrenal gland on computed imaging;
- patients at unacceptable high risks of adrenal surgery (eg, multiple comorbidities in elderly patients);
- patients suspected of having an adrenocortical carcinoma;
- patients with proven FH-I or with FH-III.

Preparation of the Patient and Performance of AVS

Performing AVS requires standardized operational procedures used by an interdisciplinary team. Careful preparation of the

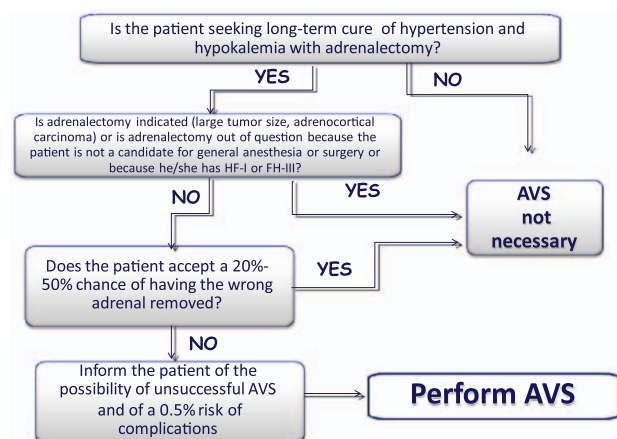


Figure 1. The flow chart shows the key questions to be asked before performing adrenal venous sampling (AVS).

patient for the procedure and standardization of the conditions for its performance are key steps to the success of AVS. Most of the recommendations to follow are based on (1) published analyses, more retrospective than prospective, of factors appearing to influence technical success and accuracy and (2) knowledge of factors that by influencing aldosterone secretion might confound interpretation. Recognition that PA has been historically underdiagnosed, and AVS underused, requires some pragmatic simplification of the requirements that have not been shown to be essential, to maximize the number of patients whom the specialized centers can serve.

If cosyntropin is not used, AVS is best performed in the morning so as to avoid false-negative results attributable to diurnal fluctuation in adrenocorticotrophic hormone, which has a more variable effect on many APAs than on the contralateral adrenal. Some centers conduct AVS as an outpatient procedure, in which case time should, if possible, allow for the patient to be kept in the supine position for 1 hour before AVS.^{11,12} Hypokalemia, if present, should be corrected with oral or intravenous potassium supplements before AVS because hypokalemia decreases aldosterone secretion and may potentially mask a unilateral APA.

Discontinuation of platelet aggregation inhibitors is not necessary. Careful adjustment of the antihypertensive agents before and during AVS is important. Peripheral α_1 -adrenergic receptor blockers (eg, doxazosin mesylate, prazosin hydrochloride, and terazosin hydrochloride) and the long-acting dihydropyridine or nondihydropyridine calcium-channel blockers (verapamil) are recommended because these agents negligibly affect renin secretion.³⁰ In stage 3, and drug-resistant hypertensive patients, multiple agents may be necessary for achieving blood pressure control before successful AVS can be achieved in these patients. Thus, in these patients, angiotensin I-converting enzyme inhibitors, angiotensin II type 1 receptors blockers, diuretics, and β -adrenergic blockers may be used as long as renin is suppressed. If the patient lateralizes, the result is usually valid regardless of medications or serum potassium status. However, if AVS does not lateralize in patients treated with these agents, the AVS results should be interpreted with

caution because there are no studies supporting the feasibility of using these agents during AVS. Of particular concern in terms of validity is the presence during the test of elevated renin or hypokalemia (class of evidence/recommendation IIB). Wherever possible, MR antagonists should be avoided because they have the potential to allow a rise in renin secretion, which can stimulate aldosterone secretion from the unaffected side, thus minimizing the lateralization.

Consensus exists that in patients previously on MR antagonists or amiloride, such agents should be withdrawn (for MR antagonists ≥ 4 weeks but better 6 weeks, probably less for amiloride) before AVS. This withdrawal entails a small clinical risk in patients with resistant hypertension who, however, are unlikely to benefit from subsequent adrenalectomy unless their blood pressure control is substantially lowered by MR blockade. Therefore, some centers use plasma renin measurement to decide whether to perform AVS without withdrawing, or downtitrating, the MR antagonists: they consider the finding of low renin (eg, a direct renin <25 mU/L or a plasma renin activity <0.60 ng/mL per hour) as evidence for unlikely stimulation of the contralateral adrenal cortex at a level sufficient to confuse interpretation of lateralization and use an independent measure of lateralization. In addition, one center has used the ^{11}C -metomidate positron emission tomography-CT to confirm the validity of AVS performed on limited MR blockade.³¹

Catheterization of the left adrenal vein is achieved in almost 100% of the cases if the catheter tip is positioned either at or distal to the orifice of the left inferior phrenic vein to avoid a major dilution effect; in contrast, that of the right adrenal vein is more difficult owing to its small size and its draining directly into the inferior vena cava (IVC) at various angles or directly into a small accessory hepatic vein.^{10,11} Hence, prior knowledge of the right adrenal vein anatomy can facilitate catheterization in difficult cases.³² Contrast-enhanced multidetector CT may be helpful before AVS not only for detecting adrenocortical nodules but also to identify the right adrenal vein and delineate its anatomy (in the venous phase), including its position and relationship to surrounding structures (Figure 2).

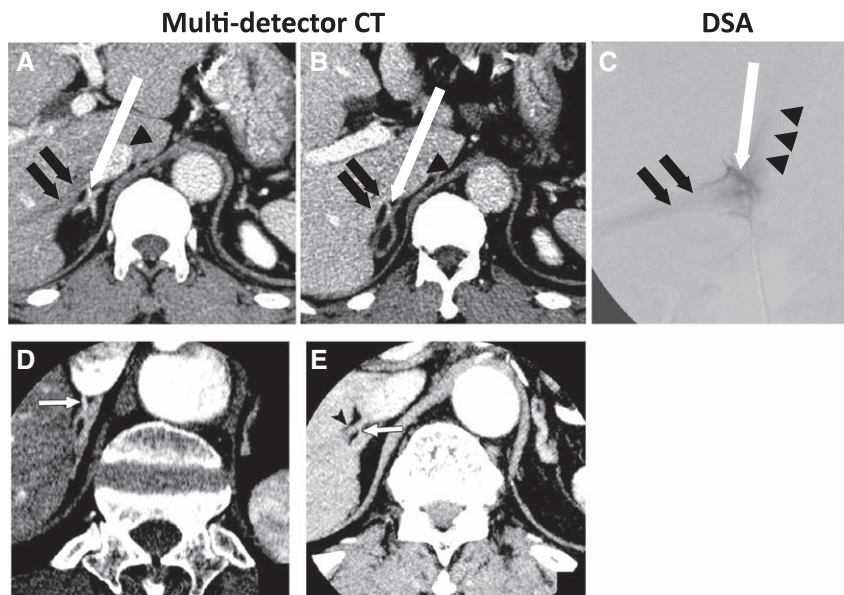


Figure 2. A and B, The contrast-enhanced multidetector computed tomography (CT) images show right adrenal vein (white arrow) that drains to accessory hepatic vein (black arrows) before entering inferior vena cava (arrowheads). C, Digital subtraction angiography (DSA) image confirms the anatomy of these veins before the super-selective adrenal venous sampling (white arrow) that meets accessory hepatic vein (black arrows). Black arrowheads indicate the position of inferior vena cava. D, The contrast-enhanced MDCT images show right adrenal vein (white arrow) that directly drains into inferior vena cava. E, The contrast-enhanced MDCT images show right adrenal vein (white arrow) that drains into accessory hepatic vein (black arrowhead).

In $\approx 10\%$ of the patients, the ascertainment of selectivity and thus the success rate of AVS can be affected by dilution from accessory vein blood flow. In the cases with prior identification on CT of the right adrenal vein draining into accessory hepatic vein, selective cannulation of the right adrenal vein by using appropriate catheters should be undertaken instead of sampling from the common trunk of accessory hepatic and right adrenal vein (Figure 2).^{32,33} In this way experienced radiologists can avoid cannulation of small independent accessory hepatic veins instead of the right adrenal vein.³³

Key Points

AVS should be performed

- by a multidisciplinary team in centers with extensive expertise;
- after an hour of supine rest if AVS is performed without cosyntropin stimulation;
- after correction of hypokalemia;
- after adjustment of antihypertensive medications.

Minimizing Stress During AVS

Emotional and pain-related stress, which activates the hypothalamic–pituitary–adrenal axis with ensuing adrenocorticotropin-induced cortisol release from both adrenal glands, can be a major confounder of AVS results because it might lower the PAC/PCC ratio and thus has the potential to obscure lateralization.

A recent study investigated the effect of stress on the selectivity index (SI, the ratio of PCC in an adrenal vein and in the infra-adrenal IVC). It showed that a stress reaction (1) occurs in most patients when starting AVS; (2) waned rapidly, usually in less than 15 minutes; (3) increases the SI on both sides at the beginning of the procedure; and (4) is likely to influence also the lateralization index (LI) values when using the sequential AVS.³⁴ Therefore, the authors concluded that simultaneous catheterization should be preferred, and precautions to minimize stress should be systematically exploited.³⁴ To the latter end, measures to be adopted both before and during AVS entail explanation of the procedure to the patient, reassurance by the doctor and nurses, and use of benzodiazepines and local anesthesia before venipuncture. Allowing the patient to rest quietly for ≥ 15 minutes before the blood sampling in a friendly environment with psychological assistance can also be useful during the procedure. At variance with this, the AVIS showed that only 1 of the 20 participating centers enlisted the systematic use of some of these measures.¹³ Additional measures aimed at either over-riding stress effects by maximally stimulating cortisol release from both adrenals or minimizing stress effects on the PAC/PCC ratio by simultaneously sampling from both adrenal veins are discussed later.

In summary, available evidence indicates that a stress reaction can affect both the SI and LI. If cosyntropin is not used, then when starting AVS, stress minimization measures should be taken with a level of evidence/recommendation class IIB.

Key Points

- Emotion- and pain-related stress affects cortisol and aldosterone secretion;

- therefore, stress can increase the SI, but it can lower the LI;
- when AVS is performed without cosyntropin stimulation, procedures should be implemented to prevent and treat emotion- and pain-related stress.

Performance of AVS: Bilaterally Simultaneous or Sequential Catheterization?

Given that secretion of aldosterone is pulsatile, there are chances of creating artificial gradients between the adrenal glands when the sequential blood sampling technique is used, particularly if the radiologist is not proficient or fast enough. Bilaterally simultaneous AVS can avoid this,³⁵ but may slightly increase, at least theoretically, the risk of adrenal vein thrombosis because it increases the time of catheter's obstructing the vessel lumen until the contralateral vein is successfully catheterized. This potential risk depends on the skill and experience of the radiologist who performs the procedure, in line with the finding that there is a significant inverse correlation between the number of procedures performed by each single radiologist and the rate of complications.¹³ Thus, a trained vascular radiologist should do all procedures in the majority of the centers where the limited number of AVS performed yearly renders this feasible.

The AVIS showed that almost two thirds of the centers use the sequential technique with cosyntropin (synthetic adrenocorticotrophic hormone 1–24) stimulation (see later), whereas the rest used the bilaterally simultaneous technique with no stimulation.¹³ This finding could be anticipated because when cortisol secretion is maximally stimulated during cosyntropin infusion, the time difference between blood sampling from one side and the other does not matter, at least as far as the assessment of selectivity is concerned. Conversely, if AVS is performed without cosyntropin stimulation, simultaneous blood sampling is likely to be crucial.

Key Points

- The pulsatile pattern of secretion of cortisol and aldosterone can generate time-related variability in hormone concentrations in the adrenal vein blood;
- cosyntropin stimulation and bilateral simultaneous sampling can minimize this time-related variability compared with sequential sampling without cosyntropin stimulation;
- outcome data supporting one approach over the other are not available.

Pharmacological Stimulation During AVS

Stimulation with a continuous cosyntropin infusion (50 $\mu\text{g}/\text{h}$ started 30 minutes before sampling) or a bolus (250 μg) during AVS is currently used at many centers.^{36–38} There are 3 reasons for using this stimulation: (1) enhancing the PCC gradient between the adrenal vein and the IVC and thus increasing the SI values and confidence of successful sampling; (2) reducing stress-induced fluctuations in cortisol and aldosterone secretion during sequential AVS; and (3) increasing aldosterone secretion from APA.^{36–38}

To assess the value of pharmacological stimulation during AVS, original articles that investigated patients with PA, before and after exposure to pharmacological agents,

alongside the experts' experience, were reviewed in terms of the SI, the LI (Table), and of the decision to perform adrenalectomy. Nine potentially relevant reports were identified, 8 using cosyntropin and 1 metoclopramide. These articles are discussed in the online-only Data supplement and summarized in Table S2.^{35,39–46}

In summary, in keeping with the theoretical premises, the bulk of the data indicate that cosyntropin increases the SI, thus facilitating the ascertainment of selective catheterization. Accordingly, in the AVIS, centers that systematically used cosyntropin were found to use higher cutoff values for the SI than centers that used baseline (unstimulated) values. Moreover, these major referral centers were almost equally split into those that use and those that do not use cosyntropin stimulation,¹³ probably because conclusive evidence for the superiority of either approach to determine lateralization of aldosterone excess is lacking. In fact, no randomized study has yet investigated whether use of cosyntropin stimulation is associated with improved or worsened outcome, defined as remission of hypertension and hypokalemia as end points. In the absence of definitive data, each center should use a consistent protocol and the following suggestions are provided: (1) if cosyntropin stimulation is not used, then bilateral simultaneous AVS should be performed; and (2) if cosyntropin stimulation is used, then higher SI and LI values are indicated.

Key Points

- Cosyntropin stimulation during AVS facilitates the assessment of selective adrenal vein catheterization;
- there is no conclusive evidence that cosyntropin stimulation leads to a better outcome than unstimulated AVS.

Assessment of Successful Catheterization

In the early years of AVS, retrograde injection of contrast medium in the adrenal vein to obtain a venogram was used to confirm the success of catheterization and to visualize the abnormal vascular tree that can be a feature of an APA. This procedure carried an increased risk of adrenal vein rupture, thus contributing substantively to the perceived risk of AVS.^{11,12} With the availability of CT and MRI, adrenal venography is no longer indicated. Nevertheless, injection of a small amount of dye with a gentle pressure is still used to visualize the adrenal vein and thus confirm the correct positioning of the catheter tip.

For left AVS, the tip of the catheter should be placed beyond the orifice of the left inferior phrenic vein but including all the left adrenal tributaries. For right AVS, the right adrenal vein should be distinguished from the accessory hepatic vein. In cases with the right adrenal vein draining into accessory hepatic vein, the tip of a suitable catheter should be confirmed as located in the right adrenal vein and not the hepatic venous tributaries. Confirmatory injection of very small amount of contrast should be performed just before and after blood extraction. The most popular technique to confirm the success of selective adrenal vein catheterization entails calculation of the ratio of concentrations of cortisol from an adrenal vein and the infra-adrenal IVC or a peripheral vein, defined as SI (Table),³⁵ based on the assumption that cortisol is exclusively secreted from the adrenal cortex and, with few exceptions (see later), is not generally overproduced in APA. Therefore, the finding of a concentration gradient between a blood sample in a vein supposedly draining the adrenal cortex and the IVC, or a peripheral vein, indicates the placement of the catheter's tip into the adrenal vein. Given its high rate of production and easy assay, the most widely used hormone is cortisol, although attempts to use epinephrine,⁴⁷ metanephrine, and also chromogranin A have been made.⁴⁸

Although the use of SI might seem straightforward, the AVIS showed that even though most major international referral centers used the SI to assess selectivity, some analyze their results using absolute hormonal values without prior assessment of the selectivity and correction for the degree of sample dilution; moreover, there was considerable variability in the SI cutoff values used.¹³ Some general considerations can, however, be made: the cutoffs were lower at centers that perform AVS without pharmacological stimulation (see later) than at those that use cosyntropin stimulation.

As a rule of thumb, the higher the cutoff chosen to establish selectivity, the lower the proportion of AVS studies that can be defined as bilaterally selective and vice versa. Thus, too restrictive criteria may lead to exclude a proportion of otherwise successful studies from diagnostic use, whereas conversely the use of too permissive SI cutoffs may compromise the diagnostic accuracy of AVS. Moreover, as the SI increases, the confidence of the interpretation increases. In some cases where unilateral aldosterone production is extremely high, a low SI will suffice and give the correct interpretation, but in cases when the production is modest, it may lead to the wrong conclusion. Although the need for

Table. Definitions and Features of the Selectivity Index, the Lateralization Index, and the Contralateral Suppression Index

Definition	Formula	Clinical Significance	Comment
Selectivity index	PCC_{side}/PCC_{IVC}	Values greater than the cutoff confirm that the blood sample was obtained from the adrenal vein.	Use of increasingly restrictive cutoffs markedly decreases the number of AVS studies that are bilaterally selective.
Lateralization index	$PAC_{Dom}/PCC_{Dom} : PAC_{Nondom}/PCC_{Nondom}$	Values greater than the cutoff evidence lateralized aldosterone excess.	Adoption of a high cutoff results in exclusion of a fairly large number of patients, who can be cured, from adrenalectomy.
Contralateral suppression index	$PAC_{Nondom}/PCC_{Nondom} : PAC_{IVC}/PCC_{IVC}$	Values lesser than the cutoff indicate ipsilateral suppression and suggest contralateral aldosterone overproduction.	On the right side, the adrenal vein commonly shares egress in the IVC with accessory hepatic veins which can generate artificial aldosterone suppression.

AVS indicates adrenal vein sampling; Dom, dominant side, for example, side with higher PAC; IVC, inferior vena cava; Nondom, nondominant side, for example, side with lower PAC; PAC, plasma aldosterone concentration; and PCC, plasma cortisol concentration.

a trade-off between too restrictive and too permissive cutoffs has been clearly shown,³⁵ and then repeatedly confirmed,^{39,48} this concept needs to be considered rather than adhering strictly to a specific value.

Based on the experience gained and the AVIS results, we suggest use of an SI ≥ 2.0 for AVS performed under unstimulated conditions and ≥ 3.0 for AVS performed during cosyntropin stimulation. One caveat is that some studies used AVS results to validate the diagnosis and to justify these cutoff values, rather than the biochemical response to surgery.^{47,49–51}

In summary, AVS studies that are not bilaterally successful should not be used to establish lateralization. Accordingly, prior verification of bilateral selectivity is a prerequisite to the use of the data for diagnostic purposes. Nonetheless, recognizing the fact that many studies are not bilaterally selective and yield equivocal results, a following section has been devoted to the clinical decision making in these difficult cases.

Key Points

- Successful AVS should be determined by calculating the SI;
- AVS studies that are not bilaterally successful should not be used to establish lateralization;
- the cutoff value for the SI should be ≥ 2.0 under unstimulated conditions;
- the cutoff value for the SI should be ≥ 3.0 during cosyntropin stimulation.

Intraprocedural PCC Assay

Given that the hormonal data are normally not available until well after AVS is completed, and therefore allow judgment of the selectivity achieved only retrospectively, some centers use contemporaneous PCC measurement during AVS. This gives the radiologist immediate feedback on whether selective blood sampling from each adrenal vein was achieved; if not, further attempts of selective catheterization can be undertaken before removing the catheters, avoiding the need for future catheterization.^{52,53} Although this approach can improve the success rate, particularly during the radiologist's learning curve, it is feasible only at centers where PCC can be measured rapidly, which implies a suitable logistic organization and a dedicated laboratory technician standing by.^{54,55}

Key Point

- Rapid intraprocedural cortisol measurement confers the advantage of drawing a repeat blood sample after catheter repositioning in case of unsuccessful initial catheterization.

Interpretation of AVS and Assessment of Lateralization

The operational diagnostic index for assessment of lateralization of aldosterone hypersecretion is the LI, calculated from the PAC and PCC in both adrenal veins and defined as the ratio of the higher (dominant) over the lower (nondominant) PAC/PCC ratio (Table).³⁵ PCC values from adrenal venous blood are used for correction of the adrenal aldosterone levels because of inevitable dilution of the samples by nonadrenal blood, even if every effort is made to avoid dilution effects

such as blood flow from the accessory hepatic vein and the inferior phrenic vein (see above).^{32,33}

According to the AVIS, the majority of the large referral centers perform AVS by sequential sampling with cosyntropin stimulation¹³ to minimize stress-mediated fluctuations in aldosterone secretion^{34,38} and to improve selectivity.³⁵ Because APAs are heterogeneous in terms of response to adrenocorticotrophic hormone,^{35,39,51} cosyntropin can exert a confounding effect on aldosterone secretion, thus increasing the risk of misclassification. In addition, different doses (very low,^{39,51} intermediate, and high dose) and protocols (bolus injection, continuous infusion, or a combination of both) of cosyntropin administration have been used. Although the very low dose was shown to be ineffective in releasing cortisol and aldosterone,³⁹ it is not clear yet which type of administration is optimal.

Some studies have demonstrated lowered diagnostic accuracy using cosyntropin stimulation,^{35,39,51} whereas others did not.^{56,57} Therefore, at present, there is no consensus on whether or not to use cosyntropin stimulation. Cosyntropin stimulation (bolus and continuous infusion) is a reasonable alternative in combination with the sequential technique, particularly if the simultaneous technique is not available with a level of evidence/recommendation class IIB.

Regarding the interpretation of AVS results, evidence for optimal diagnostic accuracy of LI cutoffs should come from prospective studies in patients undergoing unilateral adrenalectomy regardless of the AVS results and in which the different LI are thereafter linked to postsurgical cure of hyperaldosteronism rather than only high blood pressure, which is a composite phenotype. Unfortunately, no such prospective randomized controlled studies are available.⁷ The AVIS showed that most referral centers use LI cutoffs derived from observational studies with values that ranged between 2.0 and 4.0 depending on cosyntropin stimulation, higher cutoffs being selected after cosyntropin stimulation.¹³ Although data from the available observational studies show that outcome in terms of cure/improvement of blood pressure is similar for LIs varying between 2.0 and 5.0, we advise an LI cutoff of 4.0 during cosyntropin stimulation and of 2.0 for unstimulated AVS as the criteria to document lateralization of aldosterone excess.^{35–37,43,57–60} A recent study comparing 10 different LI criteria to determine lateralization⁶⁰ found no significant differences in clinical outcome for all criteria: the most accurate criterion for correctly identifying lateralization was 4.0 during cosyntropin stimulation; without cosyntropin an LI ≥ 2.0 in combination with an SI ≥ 2.0 performed best.

It is worth considering that the choice of more restrictive (higher) cutoffs, with and without stimulation, undoubtedly leads to selection of a population with a higher chance of being cured with adrenalectomy. The drawback of this approach may preclude the chances of cure to some potentially curable patients who have LI below these high cutoffs.

To allow use of AVS studies that were not bilaterally selective, and in which therefore the LI cannot be calculated, and assuming that theoretically the secretion of aldosterone should be suppressed from the side contralateral to an APA, some studies have made an attempt to use a contralateral aldosterone suppression (PAC/PCC ratio of the nondominant adrenal

vein less than the peripheral PAC/PCC ratio, Table) as an additional criterion to assess lateralization.

There are several caveats: not all studies have provided convincing evidence by the so-called 4 corners criteria of outcome after adrenalectomy to assess the accuracy of AVS criteria. Ideally, outcome should be assessed using postsurgical normalization of both aldosterone secretion, which consistently occurs after curative adrenalectomy,^{5,61} and blood pressure, which may not fall if the patient has concomitant essential hypertension and vascular remodeling.²⁷ Verification of these outcomes was obviously impossible in the patients who are not operated because they show no lateralization of aldosterone secretion at AVS.^{2,61} Both strength and quality of evidence are low (level of evidence/recommendation class IIB).

Key Points

- Lateralization of aldosterone secretion should be determined by the LI;
- for assessing lateralization, there is no compelling evidence for the use of cosyntropin stimulation in terms of outcome;
- in the AVIS, most centers used LI between 2.0 and 4.0 under unstimulated conditions and between 2.6 and 4.0 during cosyntropin stimulation; 100% of centers used baseline, unstimulated LI values ≥ 2.0 .

Clinical Decision Making Based on Equivocal AVS Results

In the AVIS, the most commonly used cutoff values for AVS performed with cosyntropin stimulation were SI of ≥ 3.0 to 5.0 for successful sampling and an LI of ≥ 4.0 for lateralization, with no centers using LI cutoff < 2.0 .¹³ For studies without cosyntropin, these cutoff values were generally lower by a factor of ≈ 2 , but the decision-making principles are the same. Consequently, AVS studies with cosyntropin are considered equivocal when the LI is 2.0 to 4.0. When 1 or both SI values are < 3.0 , the study is technically unsuccessful, but can information still be salvaged? Should all of these patients be managed medically?

AVS is particularly difficult to assess because the true result will often never be known. False negatives are rarely reinvestigated; aldosterone/renin ratio is likely to fall when any adrenal is removed, and moreover, persisting hypertension can be attributed to many factors. Thus, only persistent hypokalemia or documented unsuppressible PAC in the setting of low renin after adrenalectomy would be the definitive evidence of incorrect lateralization. Because APAs are mostly benign, and many patients can be controlled medically, false negatives are less serious than false positives, and it is appropriate that diagnostic thresholds are generally high. Ambiguous cases can often be resolved by repeating the investigation. Where medical control is poor, hence increasing the benefit/risks from surgery, it is open to the clinician to lower the threshold for recommending surgery.

When choosing among the several diagnostic options and therapeutic interventions, the critical parameters to estimate clinically the likelihood of an APA and how much the patient might benefit if adrenalectomy is performed. Predictors of APA include hypokalemia, higher serum and urinary

aldosterone, and age < 50 years at diagnosis. Cure of hypertension occurs in 30% to 60% of patients with PA,^{5,6,24–27,62} and predictive factors for persistent hypertension include age, number of antihypertensive medications, duration of hypertension, obesity, and vascular remodeling.^{24–27,62–65} In a young patient with hypokalemia and with difficulty to control hypertension of recent onset, the potential for significant impact of surgical cure of PA is high. In addition, unilateral adrenalectomy can be beneficial in some patients with bilateral aldosterone production,⁶⁶ which cautions against reliance on cross-sectional imaging with CT and MRI when AVS is equivocal. Conversely, medical management with spironolactone or eplerenone is an effective treatment of APA and its complications,^{5,6,65–67} so the choice of medical management is never an incorrect treatment strategy.

When the SI is < 3.0 with cosyntropin (< 2.0 unstimulated), the suboptimal sampling is usually on the right side. One caveat is that APA sometimes cosecrete cortisol,⁶⁸ particularly those > 3 cm in size, which suppresses cortisol production from the contralateral adrenal, lowers the SI, and inflates the PAC/PCC ratio on that side. In these cases with relatively large adrenal tumors, biochemical assessment for hypercortisolism such as dexamethasone suppression testing should be performed before AVS to avoid such quandaries, and if convincingly positive, the adrenal with the tumor should be removed without the guidance of AVS. In all other cases without large adrenal tumors, when AVS yields an SI of < 3.0 , our advice is not to use the data, and certainly not to use the data from the side with the SI < 3.0 . In some instances, however, incomplete data can provide sufficient information to guide clinical care. For example, when the PAC/PCC ratio in the adequately sampled adrenal vein specimen is convincingly lower than that of the IVC (contralateral suppression), the majority of aldosterone presumably derives, by exclusion, from the unsampled adrenal vein. Removal of the latter adrenal is justified,⁴⁰ although only if the likelihood of APA is high and that of persistent hypertension is low as suggested by young age, short duration of hypertension, a markedly elevated PAC and aldosterone/renin ratio, and normal renal function.

Secondary criteria for lateralization in these equivocal AVS cases are under study and not yet developed to the level of consensus, but the absolute value of the PAC/PCC ratio and measurement of additional steroids are promising approaches.

APA tends to produce the hybrid steroids, 18-hydroxycortisol and 18-oxocortisol.⁴⁰ Furthermore, the ratio of the precursor 18-hydroxycorticosterone (18OHB) to aldosterone tends to be 1.5 to 3 on the side of an APA and > 5 on the contralateral side.⁶⁹ The assays for all these steroids, however, are not routinely available, and the data are derived from small studies. Consequently, the use of these steroids to establish lateralization is based on anecdotal experience or limited data rather than large, replicated studies and thus carries a low level of evidence (class IIB). Concentrations of 18OHB and hybrid steroids in peripheral blood samples might provide a means to identify patients who are likely to have APA and therefore to lateralize on AVS. In 1 study, serum 18OHB, 18-hydroxycortisol, and 18-oxocortisol before and after saline infusion were all higher in patients with APA than those with IHA or essential hypertension⁷⁰; likewise, the serum levels

of parathyroid hormone and of autoantibodies for the type 1 angiotensin receptor were all higher in patients with APA than those with IHA or essential hypertension, with only small overlap between values for patients with APA and IHA.^{71,72} Consequently, peripheral blood values for these substances, in combination with clinical criteria such as hypokalemia or lack thereof,^{18,49} might be used to characterize which patients will benefit most from AVS when access to AVS and resources are limited.

Key Points

- When AVS results are equivocal, it is crucial to estimate using identified predictors the likelihood of an APA and the probability that the patient would benefit if adrenal-ectomy were performed;
- because APAs are mostly benign, and many patients can be controlled medically, false negatives are less serious than false positives, and it is appropriate that diagnostic thresholds are generally high.

Safety and Management of Complications

It is advised that AVS be performed in the specialized referral centers with sufficient throughput and expertise. However, the limited number of specialized centers for this technically demanding procedure may result in missed opportunities for optimal surgical management in many patients who have no access to AVS. Hence, it is also recommended that appropriate training programs and certification of proficiency in performing AVS for radiologists be implemented.

The major complication of AVS includes adrenal vein rupture, although dissection, infarction, thrombosis, and subsequent intraglandular and perirenal hematoma have also been reported.¹¹ These complications are only occasionally associated with complete and permanent adrenal insufficiency, but they can be curative if occurring in the adrenal gland harboring the APA. Clinically, adrenal vein rupture is characterized by a sequential appearance of persistent pain during or after catheterization, which increases in intensity and requires larger doses of analgesics for 24 to 48 hours.¹¹ If suggested by the clinical findings, confirmation of the diagnosis by CT and MRI and careful monitoring of vital signs should be applied. The complications usually resolve with conservative treatment and do not carry any sequelae, although they can render subsequent laparoscopic adrenalectomy more difficult attributable to extensive retroperitoneal adhesions.

Early studies suggested a wide range of AVS complication rates varying between <0.2% and 13%.^{11,36,37,73–75} Compared with the higher rate of complications reported in those previous studies, a recent global multicenter study involving major referral centers, the AVIS, demonstrated that the rate of adrenal vein rupture was 0.61%.¹³ This decrease is likely attributable, at least in part, to avoiding routine adrenal venography and minimizing the injection volume for anatomic confirmation of the adrenal vein catheterization. Complications are more common at the right than left adrenal vein, mainly because of the anatomic diversity and complexity. Although the complication rate does not seem to depend on the methods of catheterization, such as sequential or bilateral simultaneous, and

the use of cosyntropin stimulation,¹³ it was found to differ significantly among centers, even among major referral centers. Adrenal vein rupture was inversely related to the number of AVS performed by each radiologist and the number of AVS performed per center, thus clearly indicating that the complication rate depends on the expertise of the radiologist and the experience of each center.¹³

Key Points

- Appropriate training programs and certification of radiologists proficient in AVS should be implemented;
- in experienced hands, AVS is a safe procedure with a very low complication rate;
- adrenal vein rupture is one of the main complications;
- generally, there are no long-term sequelae of complications.

Conclusions

The high diagnostic accuracy and the very low rate of complications support the suggestion that AVS should serve as the gold standard diagnostic test for the subtyping of PA. With some exceptions, therefore, this procedure should be systematically used before referring a patient with unequivocal evidence of PA to the surgeon. Following the suggestions that are herein summarized will render AVS a rewarding diagnostic test both for the doctor and, more importantly, for the patient.

Perspectives

The development of techniques for a more accurate phenotypic characterization of the PA patients based on use of biomarkers as hybrid steroids, 18OHB, serum parathyroid hormone and autoantibodies to AT-1 (type 1 angiotensin 2) receptors, as well as of the ¹¹C-metomidate positron emission tomography–CT will provide tools to identify which patients will benefit most from AVS.

Disclosures

None.

References

1. Douma S, Petidis K, Doumas M, Papaefthimiou P, Triantafyllou A, Kartali N, Papadopoulos N, Vogiatzis K, Zamboulis C. Prevalence of primary hyperaldosteronism in resistant hypertension: a retrospective observational study. *Lancet*. 2008;371:1921–1926.
2. Rossi GP, Bernini G, Caliumi C, et al; PAPA Study Investigators. A prospective study of the prevalence of primary aldosteronism in 1,125 hypertensive patients. *J Am Coll Cardiol*. 2006;48:2293–2300.
3. Olivieri O, Ciaccarelli A, Signorelli D, Pizzolo F, Guarini P, Pavan C, Corgnati A, Falcone S, Corrocher R, Micchi A, Cressoni C, Blengio G. Aldosterone to renin ratio in a primary care setting: the Bussolengo study. *J Clin Endocrinol Metab*. 2004;89:4221–4226.
4. Savard S, Amar L, Plouin PF, Steichen O. Cardiovascular complications associated with primary aldosteronism: a controlled cross-sectional study. *Hypertension*. 2013;62:331–336.
5. Rossi GP, Cesari M, Cuspidi C, Maiolino G, Ciccalà MV, Bisogni V, Mantero F, Pessina AC. Long-term control of arterial hypertension and regression of left ventricular hypertrophy with treatment of primary aldosteronism. *Hypertension*. 2013;62:62–69.
6. Reincke M, Fischer E, Gerum S, et al; German Conn's Registry–Else Kröner-Fresenius-Hyperaldosteronism Registry. Observational study mortality in treated primary aldosteronism: the German Conn's registry. *Hypertension*. 2012;60:618–624.

7. Funder JW, Carey RM, Fardella C, Gomez-Sanchez CE, Mantero F, Stowasser M, Young WF Jr, Montori VM; Endocrine Society. Case detection, diagnosis, and treatment of patients with primary aldosteronism: an endocrine society clinical practice guideline. *J Clin Endocrinol Metab*. 2008;93:3266–3281.
8. Rossi GP. Diagnosis and treatment of primary aldosteronism. *Endocrinol Metab Clin North Am*. 2011;40:313–32, vii.
9. Nishikawa T, Omura M, Satoh F, Shibata H, Takahashi K, Tamura N, Tanabe A; Task Force Committee on Primary Aldosteronism, The Japan Endocrine Society. Guidelines for the diagnosis and treatment of primary aldosteronism—the Japan Endocrine Society 2009. *Endocr J*. 2011;58:711–721.
10. Davidson JK, Morley P, Hurley GD, Holford NG. Adrenal venography and ultrasound in the investigation of the adrenal gland: an analysis of 58 cases. *Br J Radiol*. 1975;48:435–450.
11. Daunt N. Adrenal vein sampling: how to make it quick, easy, and successful. *Radiographics*. 2005;25(suppl 1):S143–S158.
12. Rossi GP. New concepts in adrenal vein sampling for aldosterone in the diagnosis of primary aldosteronism. *Curr Hypertens Rep*. 2007;9:90–97.
13. Rossi GP, Barisa M, Allolio B, et al. The Adrenal Vein Sampling International Study (AVIS) for identifying the major subtypes of primary aldosteronism. *J Clin Endocrinol Metab*. 2012;97:1606–1614.
14. Magill SB, Raff H, Shaker JL, Brickner RC, Knechtges TE, Kehoe ME, Findling JW. Comparison of adrenal vein sampling and computed tomography in the differentiation of primary aldosteronism. *J Clin Endocrinol Metab*. 2001;86:1066–1071.
15. da Costa Santos CM, de Mattos Pimenta CA, Nobre MR. The PICO strategy for the research question construction and evidence search. *Rev Lat Am Enfermagem*. 2007;15:508–511.
16. Jacobs AK, Kushner FG, Ettinger SM, et al. ACCF/AHA clinical practice guideline methodology summit report: a report of the American College of Cardiology Foundation/American Heart Association Task Force on Practice Guidelines. *J Am Coll Cardiol*. 2013;61:213–265.
17. Kempers MJ, Lenders JW, van Outhousden L, van der Wilt GJ, Schultze Kool LJ, Hermus AR, Deinum J. Systematic review: diagnostic procedures to differentiate unilateral from bilateral adrenal abnormality in primary aldosteronism. *Ann Intern Med*. 2009;151:329–337.
18. Küpers EM, Amar L, Raynaud A, Plouin PF, Steichen O. A clinical prediction score to diagnose unilateral primary aldosteronism. *J Clin Endocrinol Metab*. 2012;97:3530–3537.
19. Choi M, Scholl UI, Yue P, et al. K⁺ channel mutations in adrenal aldosterone-producing adenomas and hereditary hypertension. *Science*. 2011;331:768–772.
20. Scholl UI, Nelson-Williams C, Yue P, Grekin R, Wyatt RJ, Dillon MJ, Couch R, Hammer LK, Harley FL, Farhi A, Wang WH, Lifton RP. Hypertension with or without adrenal hyperplasia due to different inherited mutations in the potassium channel KCNJ5. *Proc Natl Acad Sci U S A*. 2012;109:2533–2538.
21. Harris DA, Au-Yong I, Basnyat PS, Sadler GP, Wheeler MH. Review of surgical management of aldosterone secreting tumours of the adrenal cortex. *Eur J Surg Oncol*. 2003;29:467–474.
22. Pang TC, Bambach C, Monaghan JC, Sidhu SB, Bune A, Delbridge LW, Sywak MS. Outcomes of laparoscopic adrenalectomy for hyperaldosteronism. *ANZ J Surg*. 2007;77:768–773.
23. Wang JH, Wu HM, Sheu MH, Tseng HS, Chiang JH, Chang CY. High resolution MRI of adrenal glands in patients with primary aldosteronism. *Zhonghua Yi Xue Za Zhi (Taipei)*. 2000;63:475–481.
24. van der Linden P, Steichen O, Zinzindohoué F, Plouin PF. Blood pressure and medication changes following adrenalectomy for unilateral primary aldosteronism: a follow-up study. *J Hypertens*. 2012;30:761–769.
25. Waldmann J, Maurer L, Holler J, Kann PH, Ramaswamy A, Bartsch DK, Langer P. Outcome of surgery for primary hyperaldosteronism. *World J Surg*. 2011;35:2422–2427.
26. Sawka AM, Young WF, Thompson GB, Grant CS, Farley DR, Leibson C, van Heerden JA. Primary aldosteronism: factors associated with normalization of blood pressure after surgery. *Ann Intern Med*. 2001;135:258–261.
27. Rossi GP, Bolognesi M, Rizzoni D, Seccia TM, Piva A, Porteri E, Tiberio GA, Giulini SM, Agabiti-Rosei E, Pessina AC. Vascular remodeling and duration of hypertension predict outcome of adrenalectomy in primary aldosteronism patients. *Hypertension*. 2008;51:1366–1371.
28. Funder JW. Primary aldosteronism: clinical lateralization and costs. *J Clin Endocrinol Metab*. 2012;97:3450–3452.
29. Zarnegar R, Bloom AI, Lee J, Kerlan RK Jr, Wilson MW, Laberge JM, Gordon RL, Kebebew E, Clark OH, Duh QY. Is adrenal venous sampling necessary in all patients with hyperaldosteronism before adrenalectomy? *J Vasc Interv Radiol*. 2008;19:66–71.
30. Rossi GP. A comprehensive review of the clinical aspects of primary aldosteronism. *Nat Rev Endocrinol*. 2011;7:485–495.
31. Burton TJ, Mackenzie IS, Balan K, Koo B, Bird N, Soloviev DV, Azizan EA, Aigbirio F, Gurnell M, Brown MJ. Evaluation of the sensitivity and specificity of (11)C-metomidate positron emission tomography (PET)-CT for lateralizing aldosterone secretion by Conn's adenomas. *J Clin Endocrinol Metab*. 2012;97:100–109.
32. Miotto D, De Toni R, Pitter G, Seccia TM, Motta R, Vincenzi M, Feltrin G, Rossi GP. Impact of accessory hepatic veins on adrenal vein sampling for identification of surgically curable primary aldosteronism. *Hypertension*. 2009;54:885–889.
33. Matsuura T, Takase K, Ota H, Yamada T, Sato A, Satoh F, Takahashi S. Radiologic anatomy of the right adrenal vein: preliminary experience with MDCT. *AJR Am J Roentgenol*. 2008;191:402–408.
34. Seccia TM, Miotto D, Battistel M, Motta R, Barisa M, Maniero C, Pessina AC, Rossi GP. A stress reaction affects assessment of selectivity of adrenal venous sampling and of lateralization of aldosterone excess in primary aldosteronism. *Eur J Endocrinol*. 2012;166:869–875.
35. Rossi GP, Pitter G, Bernante P, Motta R, Feltrin G, Miotto D. Adrenal vein sampling for primary aldosteronism: the assessment of selectivity and lateralization of aldosterone excess baseline and after adrenocorticotrophic hormone (ACTH) stimulation. *J Hypertens*. 2008;26:989–997.
36. Weinberger MH, Grim CE, Hollifield JW, Kem DC, Ganguly A, Kramer NJ, Yune HY, Wellman H, Donohue JP. Primary aldosteronism: diagnosis, localization, and treatment. *Ann Intern Med*. 1979;90:386–395.
37. Young WF Jr, Stanson AW, Grant CS, Thompson GB, van Heerden JA. Primary aldosteronism: adrenal venous sampling. *Surgery*. 1996;120:913–919; discussion 919.
38. Young WF, Stanson AW, Thompson GB, Grant CS, Farley DR, van Heerden JA. Role for adrenal venous sampling in primary aldosteronism. *Surgery*. 2004;136:1227–1235.
39. Seccia TM, Miotto D, De Toni R, Pitter G, Mantero F, Pessina AC, Rossi GP. Adrenocorticotrophic hormone stimulation during adrenal vein sampling for identifying surgically curable subtypes of primary aldosteronism: comparison of 3 different protocols. *Hypertension*. 2009;53:761–766.
40. Nakamura Y, Satoh F, Morimoto R, Kudo M, Takase K, Gomez-Sanchez CE, Honma S, Okuyama M, Yamashita K, Rainey WE, Sasano H, Ito S. 18-oxocortisol measurement in adrenal vein sampling as a biomarker for subclassifying primary aldosteronism. *J Clin Endocrinol Metab*. 2011;96:E1272–E1278.
41. Satoh F, Abe T, Tanemoto M, Nakamura M, Abe M, Urano A, Morimoto R, Sato A, Takase K, Ishidoya S, Arai Y, Suzuki T, Sasano H, Ishibashi T, Ito S. Localization of aldosterone-producing adrenocortical adenomas: significance of adrenal venous sampling. *Hypertens Res*. 2007;30:1083–1095.
42. Harvey A, Kline G, Pasioka JL. Adrenal venous sampling in primary hyperaldosteronism: comparison of radiographic with biochemical success and the clinical decision-making with “less than ideal” testing. *Surgery*. 2006;140:847–853; discussion 853.
43. Mathur A, Kemp CD, Dutta U, et al. Consequences of adrenal venous sampling in primary hyperaldosteronism and predictors of unilateral adrenal disease. *J Am Coll Surg*. 2010;211:384–390.
44. Tanemoto M, Suzuki T, Abe M, Abe T, Ito S. Physiologic variance of corticotropin affects diagnosis in adrenal vein sampling. *Eur J Endocrinol*. 2009;160:459–463.
45. Carr CE, Cope C, Cohen DL, Fraker DL, Trerotola SO. Comparison of sequential versus simultaneous methods of adrenal venous sampling. *J Vasc Interv Radiol*. 2004;15:1245–1250.
46. Wu KD, Liao TS, Chen YM, Lai MK, Chen SJ, Su CT, Chu TS, Chang CC, Hsieh BS. Preoperative diagnosis and localization of aldosterone-producing adenoma by adrenal venous sampling after administration of metoclopramide. *J Formos Med Assoc*. 2001;100:598–603.
47. Freel EM, Stanson AW, Thompson GB, Grant CS, Farley DR, Richards ML, Young WF Jr. Adrenal venous sampling for catecholamines: a normal value study. *J Clin Endocrinol Metab*. 2010;95:1328–1332.
48. Seccia TM, Miotto D, De Toni R, Maniero C, Vincenzi M, Motta R, Pessina AC, Rossi GP. Chromogranin a measurement for assessing the selectivity of adrenal venous sampling in primary aldosteronism. *J Clin Endocrinol Metab*. 2011;96:E825–E829.
49. Mulatero P, Bertello C, Rossato D, Mengozzi G, Milan A, Garrone C, Giraudo G, Passarino G, Garaballo D, Verhovez A, Rabbia F, Veglio F. Roles of clinical criteria, computed tomography scan, and adrenal vein sampling in differential diagnosis of primary aldosteronism subtypes. *J Clin Endocrinol Metab*. 2008;93:1366–1371.
50. Rossi GP, Sacchetto A, Chiesura-Corona M, De Toni R, Gallina M, Feltrin GP, Pessina AC. Identification of the etiology of primary aldosteronism

- with adrenal vein sampling in patients with equivocal computed tomography and magnetic resonance findings: results in 104 consecutive cases. *J Clin Endocrinol Metab*. 2001;86:1083–1090.
51. Rossi GP, Ganzaroli C, Miotto D, De Toni R, Palumbo G, Feltrin GP, Mantero F, Pessina AC. Dynamic testing with high-dose adrenocorticotropic hormone does not improve lateralization of aldosterone oversecretion in primary aldosteronism patients. *J Hypertens*. 2006;24:371–379.
 52. Mengozzi G, Rossato D, Bertello C, Garrone C, Milan A, Pagni R, Veglio F, Mulatero P. Rapid cortisol assay during adrenal vein sampling in patients with primary aldosteronism. *Clin Chem*. 2007;53:1968–1971.
 53. Rossi E, Regolisti G, Perazzoli F, Negro A, Grasselli C, Santi R, Cavalieri S, Belloni L, Gemelli G, Della Valle E, Miotto D. Intraprocedural cortisol measurement increases adrenal vein sampling success rate in primary aldosteronism. *Am J Hypertens*. 2011;24:1280–1285.
 54. Auchus RJ, Michaelis C, Wians FH Jr, Dolmatch BL, Josephs SC, Trimmer CK, Anderson ME, Nwariaku FE. Rapid cortisol assays improve the success rate of adrenal vein sampling for primary aldosteronism. *Ann Surg*. 2009;249:318–321.
 55. Betz MJ, Degenhart C, Fischer E, Pallauf A, Brand V, Linsenmaier U, Beuschlein F, Bidlingmaier M, Reincke M. Adrenal vein sampling using rapid cortisol assays in primary aldosteronism is useful in centers with low success rates. *Eur J Endocrinol*. 2011;165:301–306.
 56. Young WF, Stanson AW. What are the keys to successful adrenal venous sampling (AVS) in patients with primary aldosteronism? *Clin Endocrinol (Oxf)*. 2009;70:14–17.
 57. Doppman JL, Gill JR Jr. Hyperaldosteronism: sampling the adrenal veins. *Radiology*. 1996;198:309–312.
 58. Monticone S, Satoh F, Giacchetti G, Viola A, Morimoto R, Kudo M, Iwakura Y, Ono Y, Turchi F, Paci E, Veglio F, Boscaro M, Rainey W, Ito S, Mulatero P. Effect of adrenocorticotropic hormone stimulation during adrenal vein sampling in primary aldosteronism. *Hypertension*. 2012;59:840–846.
 59. Ishidoya S, Kaiho Y, Ito A, Morimoto R, Satoh F, Ito S, Ishibashi T, Nakamura Y, Sasano H, Arai Y. Single-center outcome of laparoscopic unilateral adrenalectomy for patients with primary aldosteronism: lateralizing disease using results of adrenal venous sampling. *Urology*. 2011;78:68–73.
 60. Mulatero P, Bertello C, Sukor N, Gordon R, Rossato D, Daunt N, Leggett D, Mengozzi G, Veglio F, Stowasser M. Impact of different diagnostic criteria during adrenal vein sampling on reproducibility of subtype diagnosis in patients with primary aldosteronism. *Hypertension*. 2010;55:667–673.
 61. Nwariaku FE, Miller BS, Auchus R, Holt S, Watumull L, Dolmatch B, Nesbitt S, Vongpatanasin W, Victor R, Wians F, Livingston E, Snyder WH 3rd. Primary hyperaldosteronism: effect of adrenal vein sampling on surgical outcome. *Arch Surg*. 2006;141:497–502; discussion 502.
 62. Quillo AR, Grant CS, Thompson GB, Farley DR, Richards ML, Young WF. Primary aldosteronism: results of adrenalectomy for nonsingle adenoma. *J Am Coll Surg*. 2011;213:106–112; discussion 112.
 63. Graham UM, Ellis PK, Hunter SJ, Leslie H, Mullan KR, Atkinson AB. 100 cases of primary aldosteronism: careful choice of patients for surgery using adrenal venous sampling and CT imaging results in excellent blood pressure and potassium outcomes. *Clin Endocrinol (Oxf)*. 2012;76:26–32.
 64. Carter Y, Roy M, Sippel RS, Chen H. Persistent hypertension after adrenalectomy for an aldosterone-producing adenoma: weight as a critical prognostic factor for aldosterone's lasting effect on the cardiac and vascular systems. *J Surg Res*. 2012;177:241–247.
 65. Sukor N, Gordon RD, Ku YK, Jones M, Stowasser M. Role of unilateral adrenalectomy in bilateral primary aldosteronism: a 22-year single center experience. *J Clin Endocrinol Metab*. 2009;94:2437–2445.
 66. Catena C, Colussi G, Lapenna R, Nadalini E, Chiuch A, Gianfagna P, Sechi LA. Long-term cardiac effects of adrenalectomy or mineralocorticoid antagonists in patients with primary aldosteronism. *Hypertension*. 2007;50:911–918.
 67. Ghose RP, Hall PM, Bravo EL. Medical management of aldosterone-producing adenomas. *Ann Intern Med*. 1999;131:105–108.
 68. Späth M, Korovkin S, Antke C, Anlauf M, Willenberg HS. Aldosterone- and cortisol-co-secreting adrenal tumors: the lost subtype of primary aldosteronism. *Eur J Endocrinol*. 2011;164:447–455.
 69. Auchus RJ, Chandler DW, Singeetham S, Chokshi N, Nwariaku FE, Dolmatch BL, Holt SA, Wians FH Jr, Josephs SC, Trimmer CK, Lopera J, Vongpatanasin W, Nesbitt SD, Leonard D, Victor RG. Measurement of 18-hydroxycorticosterone during adrenal vein sampling for primary aldosteronism. *J Clin Endocrinol Metab*. 2007;92:2648–2651.
 70. Mulatero P, di Cella SM, Monticone S, Schiavone D, Manzo M, Mengozzi G, Rabbia F, Terzolo M, Gomez-Sanchez EP, Gomez-Sanchez CE, Veglio F. 18-hydroxycorticosterone, 18-hydroxycortisol, and 18-oxocortisol in the diagnosis of primary aldosteronism and its subtypes. *J Clin Endocrinol Metab*. 2012;97:881–889.
 71. Rossi GP, Ragazzo F, Seccia TM, Maniero C, Barisa M, Calò LA, Frigo AC, Fassina A, Pessina AC. Hyperparathyroidism can be useful in the identification of primary aldosteronism due to aldosterone-producing adenoma. *Hypertension*. 2012;60:431–436.
 72. Rossitto G, Regolisti G, Rossi E, Negro A, Nicoli D, Casali B, Toniato A, Caroccia B, Seccia TM, Walther T, Rossi GP. Elevation of angiotensin-II type-1-receptor autoantibodies titer in primary aldosteronism as a result of aldosterone-producing adenoma. *Hypertension*. 2013;61:526–533.
 73. Graham UM, Mullan KR, Hunter SJ, Atkinson AB. Stewart PM and Allolio B. Adrenal vein sampling for primary aldosteronism: time for a reality check Response. *Clin Endocrinol (Oxf)*. 2010;73:551–552.
 74. Vonend O, Ockenfels N, Gao X, et al; German Conn's Registry. Adrenal venous sampling: evaluation of the German Conn's registry. *Hypertension*. 2011;57:990–995.
 75. Kline GA, Harvey A, Jones C, Hill MH, So B, Scott-Douglas N, Pasiaka JL. Adrenal vein sampling may not be a gold-standard diagnostic test in primary aldosteronism: final diagnosis depends upon which interpretation rule is used. Variable interpretation of adrenal vein sampling. *Int Urol Nephrol*. 2008;40:1035–1043.

Novelty and Significance

What Is New?

- Primary aldosteronism is the most common endocrine form of hypertension and is attributable to unilateral causes, most commonly an aldosterone-producing adenoma or unilateral adrenocortical hyperplasia, in up to two thirds of all cases.
- The identification of such unilateral causes requires adrenal vein sampling (AVS) and can lead to surgical cure of hypertension.
- AVS is technically challenging, difficult to interpret, and perceived as an invasive and risky test. However, recent surveys have shown that it is safe. Moreover, procedures have been developed to achieve an accurate diagnosis.

What Is Relevant?

- Knowledge that was generated in the last decade is key for a more rational use of AVS in clinical practice.

Summary

This article provides updated information on how to perform and interpret AVS to achieve an accurate diagnosis of lateralized forms of primary aldosteronism.