




European Association of Urology



Guidelines

European Association of Urology Guidelines on Upper Urinary Tract Urothelial Carcinoma: 2017 Update

Morgan Rouprêt^{a,b,*}, Marko Babjuk^c, Eva Compérat^d, Richard Zigeuner^e, Richard J. Sylvester^f, Maximilian Burger^g, Nigel C. Cowan^h, Paolo Gonteroⁱ, Bas W.G. Van Rhijn^j, A. Hugh Mostafid^k, Joan Palou^l, Shahrokh F. Shariat^m

^a AP-HP, Hôpital La Pitié-Salpêtrière, Service d'Urologie, Paris, France; ^b UPMC University Paris 06, GRC5, ONCOTYPE-Uro, Institut Universitaire de Cancérologie, Paris, France; ^c Department of Urology, Hospital Motol, Second Faculty of Medicine, Charles University, Praha, Czech Republic; ^d Department of Pathology, Hôpital Tenon, Assistance Publique-Hôpitaux de Paris, UPMC Paris VI, Paris, France; ^e Department of Urology, Medical University of Graz, Graz, Austria; ^f European Association of Urology Guidelines Office, Brussels, Belgium; ^g Department of Urology, Caritas St. Josef Medical Centre, University of Regensburg, Regensburg, Germany; ^h Department of Radiology, Queen Alexandra Hospital, Portsmouth, UK; ⁱ Division of Urology, Department of Surgical Sciences, Molinette Hospital, University of Studies of Torino, Turin, Italy; ^j Department of Surgical Oncology (Urology), Netherlands Cancer Institute, Antoni van Leeuwenhoek Hospital, Amsterdam, The Netherlands; ^k Department of Urology, Royal Surrey County Hospital, Guildford, UK; ^l Department of Urology, Fundació Puigvert, Universidad Autònoma de Barcelona, Barcelona, Spain; ^m Department of Urology, Medical University of Vienna, Vienna General Hospital, Vienna, Austria

Article info

Article history:

Accepted July 26, 2017

Associate Editor:

James Catto

Keywords:

Urothelial carcinoma
Urinary tract cancer
Risk factors
Ureter
Renal pelvis
Cytology
Ureteroscopy
Nephroureterectomy
Survival
Guidelines

Abstract

Context: The European Association of Urology (EAU) Guidelines Panel on Upper Urinary Tract Urothelial Carcinoma (UTUC) has prepared updated guidelines to aid clinicians in the current evidence-based management of UTUC and to incorporate recommendations into clinical practice.

Objective: To provide an overview of the EAU guidelines on UTUC as an aid to clinicians.

Evidence acquisition: The recommendations provided in the current guidelines are based on a thorough review of available UTUC guidelines and articles identified following a systematic search of Medline. Data on urothelial malignancies and UTUC were searched using the following keywords: urinary tract cancer; urothelial carcinomas; upper urinary tract, carcinoma; renal pelvis; ureter; bladder cancer; chemotherapy; ureteroscopy; nephroureterectomy; adjuvant treatment; instillation; recurrence; risk factors; and survival. References were weighted by a panel of experts.

Evidence synthesis: Owing to the rarity of UTUC, there are insufficient data to provide strong recommendations (ie, grade A). However, the results of recent multicentre studies are now available, and there is a growing number of retrospective articles in UTUC. The 2017 tumour, node, metastasis (TNM) classification is recommended. Recommendations are given for diagnosis and risk stratification, as well as for radical and conservative treatment; prognostic factors are also discussed. A single postoperative dose of intravesical mitomycin after radical nephroureterectomy reduces the risk of bladder tumour recurrence. Kidney-sparing management should be offered as a primary treatment option to patients with low-risk tumours and two functional kidneys.

Conclusions: These guidelines contain information on the management of individual patients according to a current standardised approach. Urologists should take into account the specific clinical characteristics of each patient when determining the optimal treatment regimen, based on the proposed risk stratification of these tumours.

Patient summary: Urothelial carcinoma of the upper urinary tract is rare, but because 60% of these tumours are invasive at diagnosis; appropriate diagnosis and management is most important. We present recommendations based on current evidence for optimal management.

© 2017 European Association of Urology. Published by Elsevier B.V. All rights reserved.

* Corresponding author. Department of Urology, Hospital Pitié-Salpêtrière, AP-HP Université Paris 6, France. Tel. +33 144 495 336; Fax: +33 142 177 354.
E-mail address: mroupret@gmail.com (M. Rouprêt).

1. Introduction

The previous European Association of Urology (EAU) guidelines on upper urinary tract carcinoma (UTUC) were published in 2015 [1]. The EAU Guidelines Panel has prepared updated guidelines to provide evidence-based information on the management to guide and facilitate clinical decision-making.

2. Evidence acquisition

2.1. Methodology

2.1.1. Data identification

A Medline search was performed using combinations of the following terms: urinary tract cancer; urothelial carcinomas (UCs); upper urinary tract, carcinoma; renal pelvis; ureter; bladder cancer (BCa); chemotherapy; ureteroscopy; nephroureterectomy; adjuvant treatment; instillation; recurrence; risk factors; and survival. The publications identified were mainly retrospective including some large multicentre studies. Owing to the scarcity of randomised data, articles were selected based on the following criteria: evolution of concepts, intermediate- and long-term clinical outcomes, study quality, and relevance. Older studies were only included if they were historically relevant. To facilitate evaluation of the quality of information provided, levels of evidence (LEs) and grades of recommendation were included according to the general principles of evidence-based medicine [2].

3. Evidence synthesis

3.1. Epidemiology, aetiology, and pathology

3.1.1. Epidemiology

Urothelial carcinomas are the fourth most common tumours [1]. They can be located in the lower (bladder and urethra) or the upper (pyelocaliceal cavities and ureter) urinary tract. Bladder tumours account for 90–95% of UCs and are the most common urinary tract malignancy [3]. UTUCs are uncommon and account for only 5–10% of UCs [1,4] with an estimated annual incidence in Western countries of almost two cases per 100 000 inhabitants. Pyelocaliceal tumours are approximately twice as common as ureteral tumours. In 17% of cases, concurrent BCa is present [5]. Recurrence in the bladder occurs in 22–47% of UTUC patients [1,6] compared with 2–6% in the contralateral upper tract [1,7].

Overall, 60% of UTUCs are invasive at diagnosis compared with 15–25% of bladder tumours [1,8]. UTUCs have a peak incidence in individuals aged 70–90 yr and are three times more common in men [1,9].

Familial/hereditary UTUCs are linked to hereditary nonpolyposis colorectal carcinoma [10], and these patients can be screened during a short interview (Fig. 1) [11]. Patients identified at high risk for HNPCC syndrome should undergo DNA sequencing for patient and family counselling [10,12].

3.1.2. Risk factors

Many environmental factors contribute to the development of UTUC [1,13]. Tobacco exposure increases the relative risk from 2.5 to 7 [1,13].

Historically, UTUC “amino tumours” were related to occupational exposure to carcinogenic aromatic amines including benzidine and β -naphthalene, both of which have been banned since the 1960s in most industrialised countries.

The average duration of exposure needed to develop UTUC is 7 yr, with a latency of up to 20 yr following termination of exposure.

Several studies have demonstrated the carcinogenic potential of aristolochic acid contained in *Aristolochia fangchi* and *clematis* plants. The aristolochic acid-derivative d-aristolactam is associated with a specific mutation in the *p53* gene at codon 139 that occurs mainly in patients with nephropathy due to Chinese herbs or Balkan endemic nephropathy who present with UTUC [1,13,14]. Although the incidence of Balkan endemic nephropathy is also declining, aristolochic acid plays a key role in the pathophysiology of this nephropathy.

There is a high incidence of UTUC in Taiwan, especially on the southwest coast, which represents 20–25% of UCs in the region [1,13]. There is a possible association between UTUC, blackfoot disease, and arsenic exposure in drinking water in this population [1] as well as aristolochic acid in Chinese herbs [13].

Differences in the ability to counteract carcinogens may contribute to host susceptibility to UTUC. Some genetic polymorphisms are associated with an increased risk of cancer or faster disease progression that introduces variability in the interindividual susceptibility to the risk factors previously mentioned. UTUC may share some risk factors and molecular pathways with bladder UC. So far, two UTUC-specific polymorphisms have been reported [1,15].

3.1.3. Histology and classification

3.1.3.1. Histological types. UTUC with pure nonurothelial histology is rare [1], but variants are present in approximately 25% of cases [16,17]. These variants correspond to high-grade tumours with worse prognosis compared with pure UC. Squamous cell carcinoma of the upper urinary tract represents <10% of pyelocaliceal tumours and is even rarer within the ureter. Squamous cell carcinoma of the urinary tract is assumed to be associated with chronic inflammatory diseases and infections arising from urolithiasis [1]. Other variants include: micropapillary and sarcomatoid carcinomas, and lymphoepithelioma. Collecting duct carcinoma can have similar characteristics to UTUC due to its common embryological origin [1]. They are, however, considered as kidney cancers and not UTUC.

3.2. Staging and classification systems

3.2.1. Classification

The classification and morphology of UTUC and bladder carcinoma are similar [1]. It is possible to distinguish between noninvasive papillary tumours (papillary urothelial

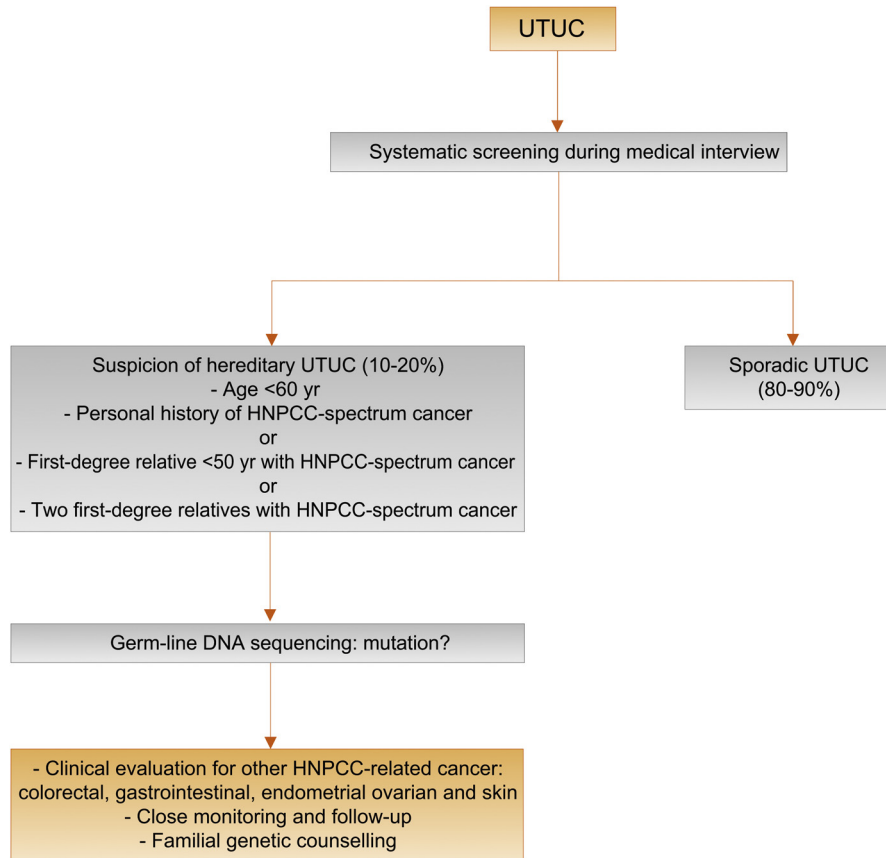


Fig. 1 – Selection of patients with UTUC for hereditary screening during the first medical interview.
HNPCC = hereditary nonpolyposis colorectal carcinoma; UTUC = upper urinary tract urothelial carcinoma.

tumours of low malignant potential and low- and high-grade papillary UC), flat lesions (carcinoma *in situ* [CIS]), and invasive carcinoma. As in bladder tumours, nonurothelial differentiation (i.e., histologic variants) confers an adverse risk factor.

3.2.2. Tumour node metastasis staging

The tumour, node, metastasis (TNM) classification is shown in Table 1 [18]. The regional lymph nodes are the hilar and retroperitoneal nodes, and for the mid and distal ureter, the intrapelvic nodes. Laterality does not affect N classification.

Renal pelvic pT3 subclassification may discriminate between microscopic infiltration of the renal parenchyma (pT3a) and macroscopic infiltration or invasion of peripelvic adipose tissue (pT3b) [16,19,20]. pT3b UTUC has a higher risk of disease recurrence after RNU [16,19].

3.2.3. Tumour grade

Until 2004, the 1973 World Health Organisation (WHO) classification was used for tumour grading and distinguished grades G1–G3 [1,21]. The 2004 WHO classification considers histological data to distinguish between noninvasive tumours: papillary urothelial neoplasia of low malignant potential, and low- and high-grade carcinomas (low grade versus high grade). The current guidelines are based on the 2004 WHO classifications [22].

3.3. Diagnosis

3.3.1. Symptoms

The diagnosis of UTUC may be incidental or related to the evaluation of symptoms that are generally limited [1]. The

Table 1 – TNM classification 2017 for upper tract urothelial carcinoma [18]

<i>T—primary tumour</i>	
TX	Primary tumour cannot be assessed
T0	No evidence of primary tumour
Ta	Noninvasive papillary carcinoma
Tis	Carcinoma <i>in situ</i>
T1	Tumour invades subepithelial connective tissue
T2	Tumour invades muscularis
T3	Tumour invades beyond muscularis into peripelvic fat or renal parenchyma (renal pelvis)
	Tumour invades beyond muscularis into periureteric fat (ureter)
T4	Tumour invades adjacent organs or through the kidney into perinephric fat
<i>N—regional lymph nodes</i>	
NX	Regional lymph nodes cannot be assessed
N0	No regional lymph node metastasis
N1	Metastasis in a single lymph node ≤2 cm in the greatest dimension
N2	Metastasis in a single lymph node >2 cm, or multiple lymph nodes
<i>M—distant metastasis</i>	
M0	No distant metastasis
M1	Distant metastasis
TNM = tumour, node, metastasis (classification).	

most common symptom is visible or nonvisible haematuria (70–80%) [1]. Flank pain occurs in approximately 20% of cases, and a lumbar mass is present in approximately 10% [1]. Systemic symptoms (including anorexia, weight loss, malaise, fatigue, fever, night sweats, or cough) associated with UTUC should prompt more rigorous metastatic evaluation; they confer a worse prognosis [1].

3.3.2. Diagnosis

3.3.2.1. Imaging

3.3.2.1.1. Computed tomography urography. Computed tomography (CT) urography has the highest diagnostic accuracy of the available imaging techniques [1]. The sensitivity of CT urography for UTUC is 0.67–1.0 and specificity is 0.93–0.99 [1,23].

Rapid acquisition of thin sections allows high-resolution isotropic images that can be viewed in multiple planes to assist with diagnosis without loss of resolution [1]. Epithelial “flat lesions” without mass effect or urothelial thickening are generally not visible with CT [1].

The secondary sign of hydronephrosis is associated with advanced disease and poor oncological outcome [1,24,25]. The presence of enlarged lymph nodes is highly predictive of metastases in UTUC [1].

3.3.2.1.2. Magnetic resonance urography. Magnetic resonance (MR) urography is indicated in patients who cannot undergo CT urography, usually when radiation or iodinated contrast media are contraindicated [1]. The sensitivity of MR urography is 0.75 after contrast injection for tumours <2 cm [1]. The use of MR urography with gadolinium-based contrast media should be limited in patients with severe renal impairment (<30 ml/min creatinine clearance), due to the risk of nephrogenic systemic fibrosis.

CT urography is generally preferred to MR urography for diagnosing and staging UTUC.

3.3.2.2. Cystoscopy and urinary cytology. Positive urine cytology is suggestive of UTUC when bladder cystoscopy is normal, provided no CIS in the bladder or prostatic urethra has been detected [1]. Cytology is less sensitive for UTUC than bladder tumours and should be performed *in situ* in the renal cavities [26]. Retrograde ureteropyelography remains an option to detect UTUCs [1,23]. Urinary cytology of the renal cavities and ureteral lumina is preferred before application of a contrast agent for retrograde ureteropyelography because it may cause deterioration of cytological specimens [1,26].

The sensitivity of fluorescence *in situ* hybridisation (FISH) for molecular abnormalities characteristic of UTUCs parallels its performance in BCa. However, its use may be limited by the preponderance of low-grade recurrent disease in the population undergoing surveillance and kidney-sparing therapy for UTUCs [1]. Therefore, FISH has limited value in the surveillance of UTUCs [1].

3.3.2.3. Diagnostic ureteroscopy. Flexible ureteroscopy is used to visualise the ureter, renal pelvis, and collecting system and biopsy suspicious lesions. Ureteroscopic biopsies can determine tumour grade in 90% of cases with a low

Table 2 – Summary of evidence and guidelines for the diagnosis of upper tract urothelial carcinoma

Summary of evidence	LE
The diagnosis of upper tract urothelial carcinoma depends on computed tomography urography and ureteroscopy.	2
Selective urinary cytology has high sensitivity in high-grade tumours including carcinoma <i>in situ</i> .	3
Recommendations	GR
Perform urinary cytology as part of a standard diagnostic workup.	A
Perform a cystoscopy to rule out concomitant bladder tumour.	A
Perform a computed tomography urography for upper tract evaluation and for staging.	A
Use diagnostic ureteroscopy and biopsy in cases where additional information will impact treatment decisions.	C
GR = grade of recommendation; LE = level of evidence.	

false-negative rate, regardless of sample size [27]. Undergrading may occur following diagnostic biopsy, making intensive follow-up necessary if kidney-sparing treatment is chosen [1]. Ureteroscopy also facilitates selective ureteral sampling for cytology *in situ* [1,28]. Stage assessment using ureteroscopic biopsy is notoriously difficult.

Flexible ureteroscopy is particularly useful in diagnostic uncertainty, if kidney-sparing treatment is considered, or in patients with a solitary kidney. Additional information can be provided by ureteroscopy with or without biopsy. Combining ureteroscopic biopsy grade, imaging findings such as hydronephrosis, and urinary cytology may help in the decision-making process between radical nephroureterectomy (RNU) and kidney-sparing therapy [1,28].

Technical developments in flexible ureteroscopes and the use of novel imaging techniques improve visualisation and diagnosis of flat lesions. Narrow-band imaging is a promising technique, but results are preliminary [1]. Recommendations are listed in Table 2.

3.4. Prognosis

3.4.1. Prognostic factors

UTUCs that invade the muscle wall usually have a very poor prognosis. The 5 yr specific survival is <50% for pT2/pT3 and <10% for pT4 [1,29]. The main prognostic factors are briefly listed here. Figure 2 shows an exhaustive list.

3.4.1.1. Preoperative factors

3.4.1.1.1. Age and sex. Gender is no longer considered an independent prognostic factor influencing UTUC mortality [1,9,29]. Older age at the time of RNU is independently associated with decreased cancer-specific survival [1,20] (LE: 3). Many elderly patients can be cured with RNU [1], suggesting that age alone is an inadequate indicator of outcome [1]. Despite its association with survival, age alone should not prevent a potentially curable approach.

3.4.1.1.2. Ethnicity. One multicentre study did not show any difference in outcome between races [1], but population-based studies have indicated that African-American patients have worse outcomes than other ethnicities [1] (LE: 3).

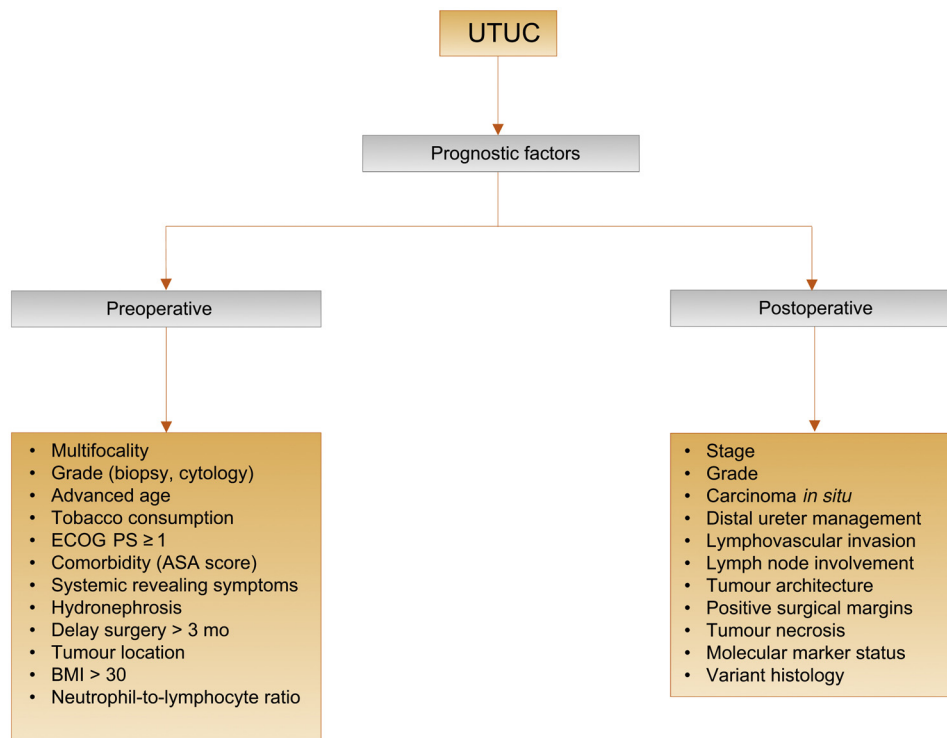


Fig. 2 – Upper urinary tract urothelial carcinoma: prognostic factors. ASA = American Society of Anesthesiologists; BMI = body mass index; ECOG PS = Eastern Cooperative Oncology Group performance status; UTUC = upper urinary tract urothelial carcinoma.

3.4.1.1.3. Tobacco consumption. Being a smoker at diagnosis increases the risk for disease recurrence and mortality after RNU [1,30] and recurrence within the bladder [31] (LE: 3). There is a close relationship between tobacco consumption and prognosis; smoking cessation improves cancer control.

3.4.1.1.4. Tumour location. Initial location of the UTUC is a prognostic factor in some studies [1,32,33] (LE: 3). After adjustment for the effect of tumour stage, patients with ureteral and/or multifocal tumours seem to have a worse prognosis than renal pelvic tumours [29,32–35].

3.4.1.1.5. Surgical delay. A delay between diagnosis of an invasive tumour and its removal may increase the risk of disease progression. Once a decision regarding RNU has been made, the procedure should be carried out within 12 wk when possible [1,36–38] (LE: 3).

3.4.1.1.6. Other. The American Society of Anesthesiologists score also significantly correlates with cancer-specific survival after RNU [39] (LE: 3), but the Eastern Cooperative Oncology Group performance status correlates only with overall survival (OS) [40]. Obesity and higher body mass index adversely affect cancer-specific outcomes in UTUCs [41] (LE: 3). The pretreatment-derived neutrophil–lymphocyte ratio also correlates with higher cancer-specific mortality [42].

3.4.1.2. Postoperative factors

3.4.1.2.1. Tumour stage and grade. The primary recognised prognostic factors are tumour stage and grade [1,28,29].

3.4.1.2.2. Lymph node involvement. Lymph node metastases and extranodal extension are powerful predictors of survival outcomes in UTUC [1]. Lymph node dissection (LND) performed at the time of RNU allows for optimal tumour staging [1,43] (LE: 3). Its curative role remains debated.

3.4.1.2.3. Lymphovascular invasion. Lymphovascular invasion is present in approximately 20% of UTUCs and is an independent predictor of survival [1]. Lymphovascular invasion status should be specifically reported in the pathological reports of all UTUC specimens [1] (LE: 3).

3.4.1.2.4. Surgical margins. Positive soft tissue surgical margin after RNU is a significant factor for developing disease recurrence. Pathologists should look for and report positive margins at the level of ureteral transection, bladder cuff, and around the tumour if T > 2 [44] (LE: 3).

3.4.1.2.5. Pathological factors. Extensive tumour necrosis (>10% of the tumour area) is an independent prognostic predictor in patients who undergo RNU [1] (LE: 3). The architecture of UTUC is also a strong prognosticator with sessile growth pattern being associated with worse outcome [1] (LE: 3). Concomitant CIS in organ-confined UTUC and a history of bladder CIS are associated with a higher risk of recurrence and cancer-specific mortality [1,45,46] (LE: 3).

3.4.2. Molecular markers

Several studies have investigated the prognostic impact of markers related to cell adhesion (E-cadherin and CD24), cell differentiation (Snail and epidermal growth factor receptor),

angiogenesis (hypoxia inducible factor 1 α and metalloproteinases), cell proliferation (Ki-67), epithelial-mesenchymal transition (Snail), mitosis (Aurora A), apoptosis (Bcl-2 and survivin), vascular invasion (RON), and c-met protein (MET) [1,29,47]. Microsatellite instability (MSI) is an independent molecular prognostic marker [48]. MSI can help detect germline mutations and hereditary cancers [10]. Because of the rarity of UTUC, the main limitations of the above studies are their retrospective design and small sample size. None of the markers have fulfilled the criteria necessary to support their introduction in daily clinical decision making.

3.4.3. Predictive tools

Accurate predictive tools are rare for UTUC. There are two models in the preoperative setting: one for predicting LND of locally advanced cancer that could guide the decision to perform, or not, an LND as well as the extent of LND at the time of RNU [1], and one for the selection of non-organ-confined UTUC that is likely to benefit from RNU [49]. Four nomograms are available predicting survival rates postoperatively, based on standard pathological features [1,50,51].

3.4.4. Bladder recurrence

A recent meta-analysis of available data has identified significant predictors of bladder recurrence after RNU [52] (LE: 3). Three categories of predictors of increased risk for bladder recurrence were identified:

1. Patient-specific factors such as male gender, previous BCa, smoking and preoperative chronic kidney disease
2. Tumour-specific factors such as positive preoperative urinary cytology, ureteral location, multifocality, invasive pT stage, and necrosis
3. Treatment-specific factors such as laparoscopic approach, extravesical bladder cuff removal, and positive surgical margins [52]

In addition, the use of diagnostic ureteroscopy has been associated with a higher risk of developing bladder recurrence after RNU [53] (LE: 3).

Table 3 – Summary of evidence and guidelines for prognosis

Summary of evidence	LE	GR
Age, sex, and ethnicity are no longer considered as independent prognostic factors.	3	
Primary recognised postoperative prognostic factors are tumour stage and grade, extranodal extension, and lymphovascular invasion.	3	
Recommendations	LE	GR
Use microsatellite instability as an independent molecular prognostic marker to help detect germline mutations and hereditary cancers.	3	C
Use the American Society of Anesthesiologists score to assess cancer-specific survival following surgery.	3	C
GR = grade of recommendations; LE = level of evidence.		

3.4.5. Risk stratification

As tumour stage is difficult to assert clinically in UTUC, it is useful to “risk stratify” UTUC between low- and high-risk tumours to identify those who are more suitable for kidney-sparing treatment rather than radical extirpative surgery [1] (Fig. 3).

3.5. Disease management

3.5.1. Localised disease

3.5.1.1. Kidney-sparing surgery. Kidney-sparing surgery (KSS) for low-risk UTUC allows sparing the morbidity associated with radical surgery, without compromising oncological outcomes and kidney function (Table 3) [1]. In low-risk cancers, it is the preferred approach with survival being similar after KSS versus RNU [54]. This option should therefore be discussed in all low-risk cases, irrespective of the status of the contralateral kidney. In addition, it can also be considered in select patients with serious renal insufficiency or solitary kidney (LE: 3). Recommendations for kidney-sparing management of UTUC are listed in Table 4.

3.5.1.1.1. Ureteroscopy. Endoscopic ablation can be considered in patients with clinically low-risk cancer in the following situations [1,55]:

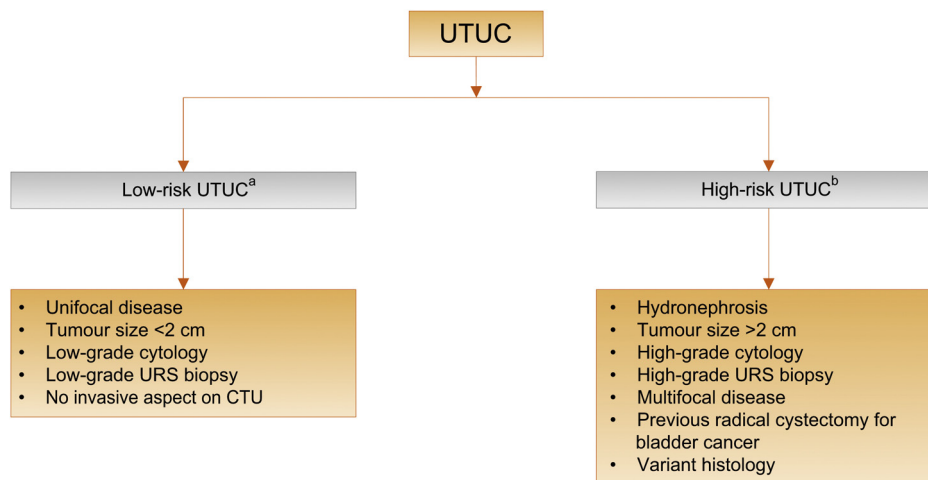


Fig. 3 – Risk stratification of upper urinary tract urothelial carcinoma. CTU = computed tomography urography; URS = ureteroscopy; UTUC = upper urinary tract urothelial carcinoma. ^a All these factors need to be present. ^b Any of these factors need to be present.

Table 4 – Guidelines for kidney-sparing management of upper tract urothelial carcinoma

Recommendations	GR
Offer kidney-sparing management as primary treatment option to patients with low-risk tumours and two functional kidneys.	C
Offer kidney-sparing management in patients with solitary kidney and/or impaired renal function, provided that it will not compromise the oncological outcome. This decision will have to be made on a case-by-case basis, engaging the patient in a shared decision-making process.	C
Offer a kidney-sparing approach in high-risk cancers for distal ureteral tumours and in imperative cases (solitary kidney and/or impaired renal function).	C
Use a laser for endoscopic treatment of upper tract urothelial carcinoma.	C
GR = grade of recommendation.	

1. Laser generator [1] and pliers available for biopsies [1,55] (LE: 3)
2. In case a flexible (rather than a rigid) ureteroscope is available
3. The patient is informed of the need for early (second look) [56], closer, more stringent, surveillance
4. Complete tumour resection or destruction can be achieved

Nevertheless, a risk of understaging and undergrading remains with endoscopic management.

3.5.1.1.2. Percutaneous access. Percutaneous management can be considered for low-risk UTUC in the renal pelvis [1,55] (LE: 3). This may be offered for low-risk tumours in the lower caliceal system that are inaccessible or difficult to manage by flexible ureteroscopy. However, this approach is being used less due to the availability of improved endoscopic tools such as distal-tip deflection of recent ureteroscopes [1,55]. A risk of tumour seeding remains with a percutaneous access.

3.5.1.1.3. Segmental ureteral resection. Segmental ureteral resection with wide margins provides adequate pathological specimens for staging and grading while preserving the ipsilateral kidney. Lymphadenectomy can also be performed during segmental ureteral resection [54].

Complete distal ureterectomy with neocystostomy are indicated for low-risk tumours in the distal ureter that cannot be removed completely endoscopically and for high-risk tumours when KSS for renal function preservation is necessary [1,57,58] (LE: 3).

Segmental resection of the iliac and lumbar ureter is associated with higher failure rates than for the distal pelvic ureter [21] (LE: 3).

Partial pyelectomy or partial nephrectomy is extremely rarely indicated. Open resection of tumours of the renal pelvis or calices has almost disappeared.

3.5.1.1.4. Adjuvant topical agents. The antegrade instillation of bacillus Calmette-Guérin (BCG) vaccine or mitomycin C in the upper urinary tract by percutaneous nephrostomy via a three-valve system open at 20 cm (after complete tumour eradication) is feasible after kidney-sparing management or for treatment of CIS [46,59] (LE: 3). Retrograde instillation through a ureteric stent is also used, but it can be dangerous due to possible ureteric obstruction and consecutive

pyelovenous influx during instillation/perfusion. The reflux obtained from a double-J stent has been used [1] but is not advisable since it often does not reach the renal pelvis.

3.5.1.2. Radical nephroureterectomy. Open RNU with bladder cuff excision is the standard for high-risk UTUC, regardless of tumour location [8] (LE: 3; Table 4). RNU must comply with oncological principles, that is, preventing tumour seeding by avoidance of entry into the urinary tract during resection [8]. Table 5 lists the recommendations for RNU.

Resection of the distal ureter and its orifice is performed because there is a considerable risk of tumour recurrence in this area [52]. After removal of the proximal ureter, it is difficult to image or approach it by endoscopy. Removal of the distal ureter and bladder cuff is beneficial after RNU [1].

Several techniques have been considered to simplify distal ureter resection, including pluck technique, stripping, transurethral resection of the intramural ureter, and intussusception. Except for ureteral stripping, none of these techniques is inferior to bladder cuff excision [1,76,61] (LE: 3).

3.5.1.2.1. Laparoscopic RNU. Retroperitoneal metastatic dissemination and metastasis along the trocar pathway following

Table 5 – Summary of evidence and recommendations for radical nephroureterectomy

Summary of evidence	LE
Radical nephroureterectomy is the standard in high-risk upper tract urothelial carcinoma, regardless of tumour location.	2
Open and laparoscopic approaches have equivalent efficacy and safety in T1–2/N0 upper tract urothelial carcinoma.	2
Recommendations	GR
Perform radical nephroureterectomy in the following situations:	B
1. Suspicion of infiltrating upper tract urothelial carcinoma on imaging	
2. High-grade tumour (urinary cytology)	
3. Multifocality (with two functional kidneys)	
4. Noninvasive but large (>2 cm) upper tract urothelial carcinoma	
Technical steps of radical nephroureterectomy	
Remove the bladder cuff.	A
Perform a lymphadenectomy in invasive upper tract urothelial carcinoma.	C
Offer postoperative bladder instillation to lower the bladder recurrence rate.	B
GR = grade of recommendation; LE = level of evidence.	

manipulation of large tumours in a pneumoperitoneal environment have been reported in few cases [1].

Several precautions may lower the risk of tumour spillage:

1. Avoid entering the urinary tract.
2. Avoid direct contact between instruments and the tumour.
3. Laparoscopic RNU must take place in a closed system. Avoid morcellation of the tumour and use an endobag for tumour extraction.
4. The kidney and ureter must be removed *en bloc* with the bladder cuff.
5. Invasive or large (T3/T4 and/or N+/M+) tumours are contraindications for laparoscopic RNU until proved otherwise.

Laparoscopic RNU is safe in experienced hands when adhering to strict oncological principles. There is a tendency towards equivalent oncological outcomes after laparoscopic or open RNU [1,62,63] (LE: 3). Only one prospective randomised study has shown that laparoscopic RNU is not inferior to open RNU for noninvasive UTUC [1] (LE: 2). Oncological outcomes after RNU have not changed significantly over the past 3 decades despite staging and surgical refinements [64] (LE: 3). A robot-assisted laparoscopic approach can be considered, but solid data are still lacking [65,66]

3.5.1.2.2. Lymph node dissection. The anatomic sites of lymph node drainage have not yet been clearly defined. The use of an LND template is likely to have a greater impact on patient survival than the number of removed lymph nodes [1].

LND appears to be unnecessary in cases of TaT1 UTUC because lymph node retrieval is reported in only 2.2% of T1 versus 16% of pT2–4 tumours [1,67]. An increase in the probability of lymph node–positive disease is related to pT classification [1]. However, it is likely that the true rate of node-positive disease has been under-reported because these data are retrospective.

Despite available studies evaluating templates to date, it is not possible to standardise indication or extent of LND. LND can be achieved following lymphatic drainage as follows: LND on the side of the affected ureter, retroperitoneal LND for higher ureteral tumour, and/or tumour of the renal pelvis (ie, right side: border vena cava or right side of the aorta; and left side: border aorta) [1,43].

3.5.1.2.3. Adjuvant bladder instillation. The rate of bladder recurrence after RNU for UTUC is 22–47%. Two prospective randomised trials have demonstrated that a single postoperative dose of intravesical chemotherapy (mitomycin C, pirarubicin) soon after surgery (<72 h) reduces the risk of bladder tumour recurrence within the 1st year post-RNU [68,69] (LE: 2) and in a meta-analysis [70]. Management is outlined in Figures 4 and 5.

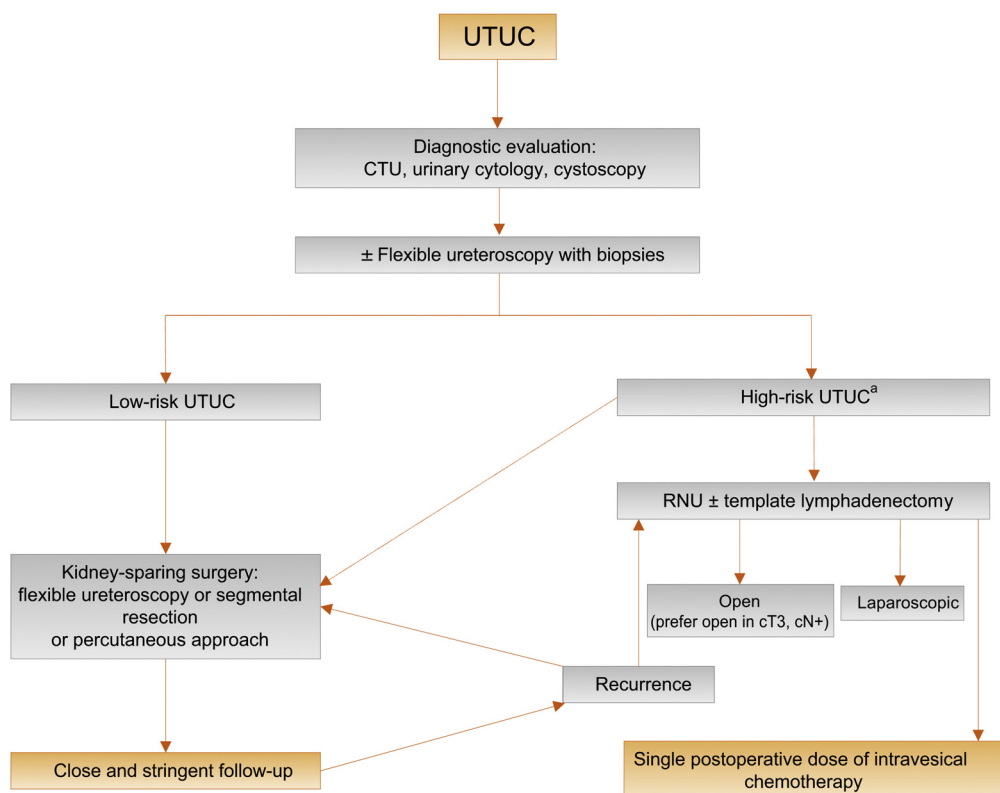


Fig. 4 – Proposed flowchart for the management of upper urinary tract urothelial cell carcinoma. CTU = computed tomography urography; RNU = radical nephroureterectomy; UTUC = upper urinary tract urothelial carcinoma. ^a In patients with solitary kidney, consider a more conservative approach.

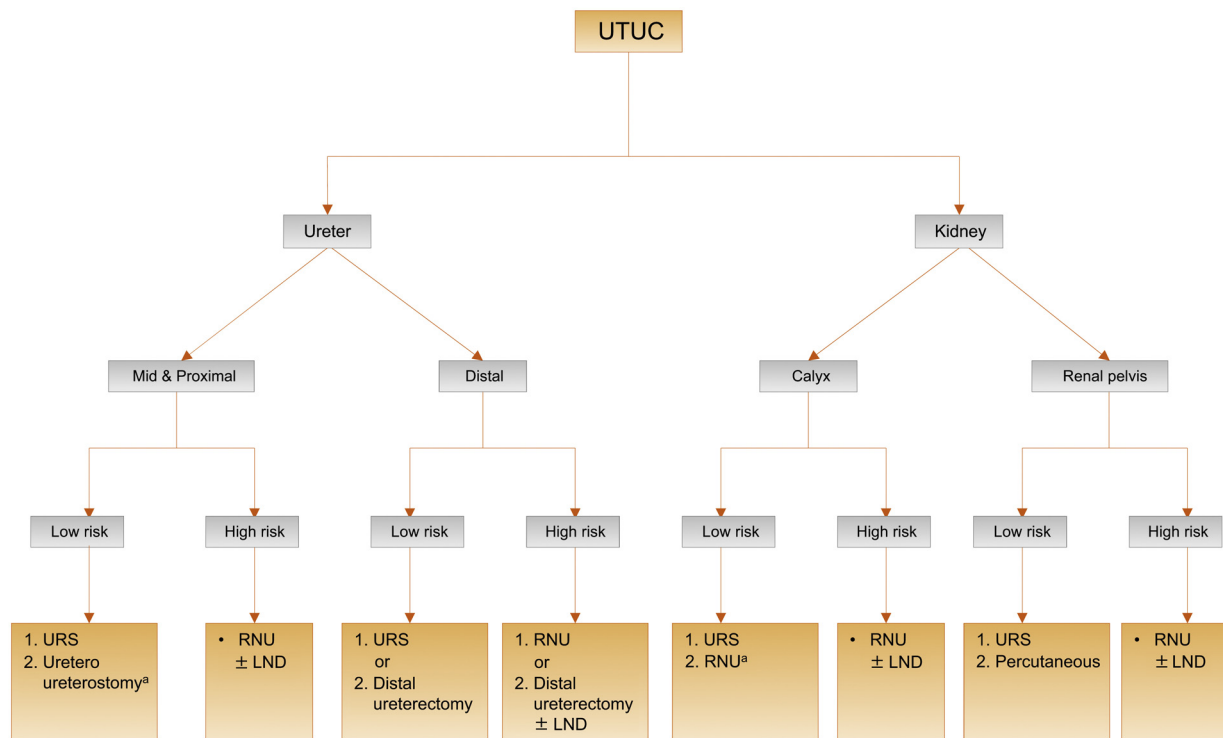


Fig. 5 – Surgical treatment according to location and risk status. 1 = first treatment option; 2 = secondary treatment option. LND = lymph node dissection; RNU = radical nephroureterectomy; URS = ureteroscopy; UTUC = upper urinary tract urothelial carcinoma. ^a In case not amenable to endoscopic management.

3.5.2. Advanced disease

3.5.2.1. Radical nephroureterectomy. There is no oncological benefit for RNU alone in patients with metastatic UTUC except for palliative considerations [1,8] (LE: 3).

3.5.2.2. Systemic chemotherapy. Extrapolating from the BCa literature and small, single-centre UTUC studies, platinum-based combination chemotherapy is expected to be efficacious in UTUC. However, there are currently insufficient data upon which to base recommendations.

There are several platinum-based regimens [1], but not all patients can receive adjuvant chemotherapy because of comorbidities and impaired renal function after radical surgery. Chemotherapy-related toxicity, particularly nephrotoxicity due to platinum derivatives, may significantly reduce survival in patients with postoperative renal dysfunction [1].

There were no adverse effects of neoadjuvant chemotherapy for UTUC [71], although survival data need to mature and longer follow-up is awaited. In a select cohort of patients fit to receive systemic chemotherapy for metastatic UTUC, there was an OS benefit to combine chemotherapy and RNU versus chemotherapy alone [72].

After a recent comprehensive search of studies examining the role of perioperative chemotherapy for UTUC, there appears to be an OS and disease-free survival benefit for cisplatin-based adjuvant chemotherapy [73] (LE: 3).

A recent study has assessed a clear OS benefit in patients who received adjuvant chemotherapy versus observation after RNU for pT3/T4 and/or pN+ UTUC [74] (LE: 3).

3.5.2.3. Radiotherapy. Radiotherapy is no longer relevant, either alone or as an adjunct to chemotherapy [1] (LE: 3).

3.5.3. Follow-up

The risk of recurrence and death evolves during the follow-up period after surgery [75]. Stringent follow-up (Table 5) is mandatory to detect metachronous bladder tumours (probability increases over time [76]), local recurrence,

Table 6 – Summary of evidence and follow-up of UTUC

Summary of evidence	LE
Follow-up is more frequent and stricter in patients who have undergone kidney-sparing treatment compared to radical nephroureterectomy.	3
Recommendations	GR
After radical nephroureterectomy, >5 yr	
<i>Noninvasive tumour</i>	
Perform cystoscopy/urinary cytology at 3 mo, and then annually.	C
Perform computed tomography urography every year.	C
<i>Invasive tumour</i>	
Perform cystoscopy/urinary cytology at 3 mo, and then annually.	C
Perform computed tomography urography every 6 mo for 2 yr, and then annually.	C
After kidney-sparing management, >5 yr	
Perform urinary cytology and computed tomography urography at 3 and 6 mo, and then annually.	C
Perform cystoscopy, ureteroscopy, and cytology <i>in situ</i> at 3 and 6 mo, and then every 6 mo for 2 yr, and then annually.	C
GR = grade of recommendation; LE = level of evidence; UTUC = upper urinary tract urothelial carcinoma.	

and distant metastases. Table 6 lists the summary of evidence and recommendations for follow-up of UTUC.

Surveillance regimens are based on cystoscopy and urinary cytology for >5 yr [1,6]. Bladder recurrence is not a distant recurrence. When KSS is performed, the ipsilateral upper urinary tract requires careful follow-up due to the high risk of disease recurrence [1]. Despite endourological improvements, follow-up after kidney-sparing management is difficult, and frequent, repeated endoscopic procedures are necessary. As done in BCa, a second look has been proposed after KSS but is not yet routine practice [56].

4. Conclusions

The EAU guidelines contain information on the management of individual patients according to a current standardised approach. Urologists should take into account the specific clinical characteristics of each patient when determining the optimal treatment regimen, based on the proposed risk stratification of these tumours.

Author contributions: Morgan Rouprêt had full access to all the data in the study and takes responsibility for the integrity of the data and the accuracy of the data analysis.

Study concept and design: Rouprêt.

Acquisition of data: Rouprêt, Babjuk, Cowan, Compérat, Zigeuner.

Analysis and interpretation of data: Rouprêt, Babjuk, Compérat, Zigeuner.

Drafting of the manuscript: Rouprêt.

Critical revision of the manuscript for important intellectual content: Rouprêt, Babjuk, Cowan, Compérat, Zigeuner, Sylvester, Burger, Gontero, Van Rhijn, Mostafid, Palou, Shariat.

Statistical analysis: None.

Obtaining funding: None.

Administrative, technical, or material support: None.

Supervision: Rouprêt.

Other: None.

Financial disclosures: Morgan Rouprêt certifies that all conflicts of interest, including specific financial interests and relationships and affiliations relevant to the subject matter or materials discussed in the manuscript (eg, employment/affiliation, grants or funding, consultancies, honoraria, stock ownership or options, expert testimony, royalties, or patents filed, received, or pending), are the following: Morgan Rouprêt is a company consultant for Lilly, Ipsen, Astellas, Takeda, and Sanofi Pasteur; and participates in trials for GSK. Marko Babjuk is a company consultant for Bayer and Ipsen; receives company speaker honoraria from Ferring and GSK; and participates in trials for Sotio. Richard Zigeuner receives company speaker honoraria from Roche and Novartis; receives fellowships and travel grants from Bayer Healthcare, Pfizer, Amgen, Novartis, and GSK; receives company grants and research support from Bayer Healthcare, company speaker honoraria from GSK and Amgen, fellowships and travel grants from Astellas and Takeda; and is a company consultant for Pfizer. Maximilian Burger is a company consultant for Photocure ASA, Astellas, and Ipsen Pharma; receives company speaker honoraria from Astellas, Springer, and Novartis; and participates in trials for Photocure SA and Ipsen Pharma. Paolo Gontero is a company consultant for Janssen and Cepheid; and receives company speaker honoraria from Ipsen. Bas van Rhijn is a company consultant for Astellas. A. Hugh Mostafid is a company consultant for Kyowa Hakko UK, participates in trials for MSD, and receives speaker honorarium from Prostrakan. Joan Palou is a company consultant for Olympus and

participates in trials for General Electric. Shahrokh Shariat owns or co-owns the following patents: Shariat S, Slawin K. Methods to determine prognosis after therapy for prostate cancer. US patent 60/266,976. May 31, 2001. Shariat S, Lerner S, Slawin K. Methods to determine prognosis after therapy for bladder cancer. US patent 675.003US1. June 1, 2001. Shariat S, Slawin K, Kattan M, Scardino P. Pre- and post-treatment nomograms for predicting recurrence in patients with clinically localised prostate cancer that includes the blood markers interleukin-6 soluble receptor and transforming growth. 2002. Slawin K, Kattan M, Shariat S, Stephenson A, Scardino P. Nomogram for predicting outcome of salvage radiotherapy for suspected local recurrence of prostate cancer after radical prostatectomy. 2003. Shariat S. Soluble fas: a promising novel urinary marker for the detection of bladder transitional cell carcinoma (UTSD: 1666). US patent in process. He is a company consultant for Astellas, Olympus, Wolff, Ipsen, and Cepheid; receives company speaker honoraria from Lilly, Astellas, Ipsen, Olympus, Wolff, and Janssen; and participates in trials on NMP22 for Alere Inc. Eva Compérat, Nigel Cowan and Richard J. Sylvester have nothing to disclose.

Funding/Support and role of the sponsor: None.

References

- [1] Roupert M, Babjuk M, Comperat E, et al. European Association of Urology guidelines on upper urinary tract urothelial cell carcinoma: 2015 update. *Eur Urol* 2015;68:868–79.
- [2] Bob Phillips CB, Sackett D, Badenoch D, Straus S, Haynes B, Dawes M. Since November 1998. Updated by Jeremy Howick March 2009. Oxford Centre for Evidence-based Medicine Levels of Evidence (May 2009). <http://www.ccbm.net/index.aspx?o=1025>.
- [3] Babjuk M, Böhle A, Burger M, et al. EAU guidelines on non-muscle-invasive urothelial carcinoma of the bladder: update 2016. *Eur Urol* 2017;71:447–61.
- [4] Siegel RL, Miller KD, Jemal A. Cancer Statistics, 2017. *CA Cancer J Clin* 2017;67:7–30.
- [5] Cosentino M, Palou J, Gaya JM, Breda A, Rodriguez-Faba O, Villavicencio-Mavrich H. Upper urinary tract urothelial cell carcinoma: location as a predictive factor for concomitant bladder carcinoma. *World J Urol* 2013;31:141–5.
- [6] Xylinas E, Rink M, Margulis V, Karakiewicz P, Novara G, Shariat SF. Multifocal carcinoma in situ of the upper tract is associated with high risk of bladder cancer recurrence. *Eur Urol* 2012;61:1069–70.
- [7] Li WM, Shen J, Li CC, et al. Oncologic outcomes following three different approaches to the distal ureter and bladder cuff in nephroureterectomy for primary upper urinary tract urothelial carcinoma. *Eur Urol* 2010;57:963–9.
- [8] Margulis V, Shariat SF, Matin SF, et al. Outcomes of radical nephroureterectomy: a series from the Upper Tract Urothelial Carcinoma Collaboration. *Cancer* 2009;115:1224–33.
- [9] Shariat SF, Favaretto RL, Gupta A, et al. Gender differences in radical nephroureterectomy for upper tract urothelial carcinoma. *World J Urol* 2011;29:481–6.
- [10] Roupert M, Yates DR, Comperat E, Cussenot O. Upper urinary tract urothelial cell carcinomas and other urological malignancies involved in the hereditary nonpolyposis colorectal cancer (lynch syndrome) tumor spectrum. *Eur Urol* 2008;54:1226–36.
- [11] Audenet F, Colin P, Yates DR, et al. A proportion of hereditary upper urinary tract urothelial carcinomas are misclassified as sporadic according to a multi-institutional database analysis: proposal of patient-specific risk identification tool. *BJU Int* 2012;110(11 Pt B): E583–9.
- [12] Acher P, Kiela G, Thomas K, O'Brien T. Towards a rational strategy for the surveillance of patients with Lynch syndrome (hereditary non-polyposis colon cancer) for upper tract transitional cell carcinoma. *BJU Int* 2010;106:300–2.

- [13] Colin P, Koenig P, Ouzzane A, et al. Environmental factors involved in carcinogenesis of urothelial cell carcinomas of the upper urinary tract. *BJU Int* 2009;104:1436–40.
- [14] Grollman AP, Shibutani S, Moriya M, et al. Aristolochic acid and the etiology of endemic (Balkan) nephropathy. *Proc Natl Acad Sci U S A* 2007;104:12129–34.
- [15] Roupert M, Drouin SJ, Cancel-Tassin G, Comperat E, Larre S, Cussenot O. Genetic variability in 8q24 confers susceptibility to urothelial carcinoma of the upper urinary tract and is linked with patterns of disease aggressiveness at diagnosis. *J Urol* 2012;187:424–8.
- [16] Rink M, Robinson BD, Green DA, et al. Impact of histological variants on clinical outcomes of patients with upper urinary tract urothelial carcinoma. *J Urol* 2012;188:398–404.
- [17] Masson-Lecomte A, Colin P, Bozzini G, et al. Impact of micropapillary histological variant on survival after radical nephroureterectomy for upper tract urothelial carcinoma. *World J Urol* 2014;32:531–7.
- [18] Brierley JD, Gospodarowicz MK, Wittekind C. *TNM classification of malignant tumours*. ed. 8 Wiley; 2016.
- [19] Roscigno M, Cha EK, Rink M, et al. International validation of the prognostic value of subclassification for AJCC stage pT3 upper tract urothelial carcinoma of the renal pelvis. *BJU Int* 2012;110:674–81.
- [20] Park J, Habuchi T, Arai Y, et al. Reassessment of prognostic heterogeneity of pT3 renal pelvic urothelial carcinoma: analysis in terms of proposed pT3 subclassification systems. *J Urol* 2014;192:1064–71.
- [21] Lopez-Beltran A, Gasser T, Hartmann A, et al. Tumors of the urinary system. In: *World Health Organisation classifications of tumors: pathology and genetics of tumours of the urinary system and male genital organs*. IARC Press; 2004.
- [22] Soukup V, Capoun O, Cohen D, et al. Prognostic performance and reproducibility of the 1973 and 2004/2016 World Health Organization grading classification systems in non-muscle-invasive bladder cancer: a European Association of Urology Non-muscle Invasive Bladder Cancer Guidelines Panel systematic review. *Eur Urol* 2017;72:801–13.
- [23] Cowan NC, Turney BW, Taylor NJ, McCarthy CL, Crew JP. Multi-detector computed tomography urography for diagnosing upper urinary tract urothelial tumour. *BJU Int* 2007;99:1363–70.
- [24] Messer JC, Terrell JD, Herman MP, et al. Multi-institutional validation of the ability of preoperative hydronephrosis to predict advanced pathologic tumor stage in upper-tract urothelial carcinoma. *Urol Oncol* 2013;31:904–8.
- [25] Hurel S, Roupert M, Seisen T, et al. Influence of preoperative factors on the oncologic outcome for upper urinary tract urothelial carcinoma after radical nephroureterectomy. *World J Urol* 2015;33:335–41.
- [26] Messer J, Shariat SF, Brien JC, et al. Urinary cytology has a poor performance for predicting invasive or high-grade upper-tract urothelial carcinoma. *BJU Int* 2011;108:701–5.
- [27] Rojas CP, Castle SM, Llanos CA, et al. Low biopsy volume in ureteroscopy does not affect tumor biopsy grading in upper tract urothelial carcinoma. *Urol Oncol* 2013;31:1696–700.
- [28] Clements T, Messer JC, Terrell JD, et al. High-grade ureteroscopic biopsy is associated with advanced pathology of upper-tract urothelial carcinoma tumors at definitive surgical resection. *J Endourol* 2012;26:398–402.
- [29] Lughezzani G, Burger M, Margulis V, et al. Prognostic factors in upper urinary tract urothelial carcinomas: a comprehensive review of the current literature. *Eur Urol* 2012;62:100–14.
- [30] Rink M, Xylinas E, Margulis V, et al. Impact of smoking on oncologic outcomes of upper tract urothelial carcinoma after radical nephroureterectomy. *Eur Urol* 2013;63:1082–90.
- [31] Xylinas E, Kluth LA, Rieken M, et al. Impact of smoking status and cumulative exposure on intravesical recurrence of upper tract urothelial carcinoma after radical nephroureterectomy. *BJU Int* 2014;114:56–61.
- [32] Yafi FA, Novara G, Shariat SF, et al. Impact of tumour location versus multifocality in patients with upper tract urothelial carcinoma treated with nephroureterectomy and bladder cuff excision: a homogeneous series without perioperative chemotherapy. *BJU Int* 2012;110(2 Pt 2):E7–13.
- [33] Ouzzane A, Colin P, Xylinas E, et al. Ureteral and multifocal tumours have worse prognosis than renal pelvic tumours in urothelial carcinoma of the upper urinary tract treated by nephroureterectomy. *Eur Urol* 2011;60:1258–65.
- [34] Chromecki TF, Cha EK, Fajkovic H, et al. The impact of tumor multifocality on outcomes in patients treated with radical nephroureterectomy. *Eur Urol* 2012;61:245–53.
- [35] Williams AK, Kassouf W, Chin J, et al. Multifocality rather than tumor location is a prognostic factor in upper tract urothelial carcinoma. *Urol Oncol* 2013;31:1161–5.
- [36] Sundi D, Svatek RS, Margulis V, et al. Upper tract urothelial carcinoma: impact of time to surgery. *Urol Oncol* 2012;30:266–72.
- [37] Gadzinski AJ, Roberts WW, Faerber GJ, Wolf Jr JS. Long-term outcomes of immediate versus delayed nephroureterectomy for upper tract urothelial carcinoma. *J Endourol* 2012;26:566–73.
- [38] Lee JN, Kwon SY, Choi GS, et al. Impact of surgical wait time on oncologic outcomes in upper urinary tract urothelial carcinoma. *J Surg Oncol* 2014;110:468–75.
- [39] Berod AA, Colin P, Yates DR, et al. The role of American Society of Anesthesiologists scores in predicting urothelial carcinoma of the upper urinary tract outcome after radical nephroureterectomy: results from a national multi-institutional collaborative study. *BJU Int* 2012;110(11 Pt C):E1035–40.
- [40] Martinez-Salamanca JI, Shariat SF, Rodriguez JC, et al. Prognostic role of ECOG performance status in patients with urothelial carcinoma of the upper urinary tract: an international study. *BJU Int* 2012;109:1155–61.
- [41] Ehdaie B, Chromecki TF, Lee RK, et al. Obesity adversely impacts disease specific outcomes in patients with upper tract urothelial carcinoma. *J Urol* 2011;186:66–72.
- [42] Dalpiaz O, Pichler M, Mannweiler S, et al. Validation of the pre-treatment derived neutrophil-lymphocyte ratio as a prognostic factor in a European cohort of patients with upper tract urothelial carcinoma. *Br J Cancer* 2014;110:2531–6.
- [43] Roscigno M, Brausi M, Heidenreich A, et al. Lymphadenectomy at the time of nephroureterectomy for upper tract urothelial cancer. *Eur Urol* 2011;60:776–83.
- [44] Colin P, Ouzzane A, Yates DR, et al. Influence of positive surgical margin status after radical nephroureterectomy on upper urinary tract urothelial carcinoma survival. *Ann Surg Oncol* 2012;19:3613–20.
- [45] Wheat JC, Weizer AZ, Wolf Jr JS, et al. Concomitant carcinoma in situ is a feature of aggressive disease in patients with organ confined urothelial carcinoma following radical nephroureterectomy. *Urol Oncol* 2012;30:252–8.
- [46] Redrow GP, Guo CC, Brausi MA, et al. Upper urinary tract carcinoma in situ: current knowledge, future direction. *J Urol* 2017;197:287–95.
- [47] Scarpini S, Roupert M, Renard-Penna R, Camparo P, Cussenot O, Comperat E. Impact of the expression of Aurora-A, p53, and MIB-1 on the prognosis of urothelial carcinomas of the upper urinary tract. *Urol Oncol* 2012;30:182–7.
- [48] Roupert M, Fromont G, Azzouzi AR, et al. Microsatellite instability as predictor of survival in patients with invasive upper urinary tract transitional cell carcinoma. *Urology* 2005;65:1233–7.
- [49] Favaretto RL, Shariat SF, Savage C, et al. Combining imaging and ureteroscopy variables in a preoperative multivariable model for

- prediction of muscle-invasive and non-organ confined disease in patients with upper tract urothelial carcinoma. *BJU Int* 2012;109:77–82.
- [50] Seisen T, Colin P, Hupertan V, et al. Postoperative nomogram to predict cancer-specific survival after radical nephroureterectomy in patients with localised and/or locally advanced upper tract urothelial carcinoma without metastasis. *BJU Int* 2014;114:733–40.
- [51] Roupret M, Hupertan V, Seisen T, et al. Prediction of cancer specific survival after radical nephroureterectomy for upper tract urothelial carcinoma: development of an optimized postoperative nomogram using decision curve analysis. *J Urol* 2013;189:1662–9.
- [52] Seisen T, Granger B, Colin P, et al. A systematic review and meta-analysis of clinicopathologic factors linked to intravesical recurrence after radical nephroureterectomy to treat upper tract urothelial carcinoma. *Eur Urol* 2015;67:1122–33.
- [53] Marchioni M, Primiceri G, Cindolo L, et al. Impact of diagnostic ureteroscopy on intra vesical recurrence in patients undergoing radical nephroureterectomy for upper tract urothelial cancer: a systematic review and meta-analysis. *BJU Int* 2017;120:313–9.
- [54] Seisen T, Peyronnet B, Dominguez-Escrig JL, et al. Oncologic outcomes of kidney-sparing surgery versus radical nephroureterectomy for upper tract urothelial carcinoma: a systematic review by the EAU Non-muscle Invasive Bladder Cancer Guidelines Panel. *Eur Urol* 2016;70:1052–68.
- [55] Cutress ML, Stewart GD, Zakikhani P, Phipps S, Thomas BG, Tolley DA. Ureteroscopic and percutaneous management of upper tract urothelial carcinoma (UTUC): systematic review. *BJU Int* 2012;110:614–28.
- [56] Villa L, Cloutier J, Letendre J, et al. Early repeated ureteroscopy within 6–8 weeks after a primary endoscopic treatment in patients with upper tract urothelial cell carcinoma: preliminary findings. *World J Urol* 2016;34:1201–6.
- [57] Lughezzani G, Jeldres C, Isbarn H, et al. Nephroureterectomy and segmental ureterectomy in the treatment of invasive upper tract urothelial carcinoma: a population-based study of 2299 patients. *Eur J Cancer* 2009;45:3291–7.
- [58] Colin P, Ouzzane A, Pignot G, et al. Comparison of oncological outcomes after segmental ureterectomy or radical nephroureterectomy in urothelial carcinomas of the upper urinary tract: results from a large French multicentre study. *BJU Int* 2012;110:1134–41.
- [59] Giannarini G, Kessler TM, Birkhauser FD, Thalmann GN, Studer UE. Antegrade perfusion with bacillus Calmette-Guerin in patients with non-muscle-invasive urothelial carcinoma of the upper urinary tract: who may benefit? *Eur Urol* 2011;60:955–60.
- [60] Xylinas E, Rink M, Cha EK, et al. Impact of distal ureter management on oncologic outcomes following radical nephroureterectomy for upper tract urothelial carcinoma. *Eur Urol* 2014;65:210–7.
- [61] Xylinas E, Kluth L, Passoni N, et al. Prediction of intravesical recurrence after radical nephroureterectomy: development of a clinical decision-making tool. *Eur Urol* 2014;65:650–8.
- [62] Ni S, Tao W, Chen Q, et al. Laparoscopic versus open nephroureterectomy for the treatment of upper urinary tract urothelial carcinoma: a systematic review and cumulative analysis of comparative studies. *Eur Urol* 2012;61:1142–53.
- [63] Ariane MM, Colin P, Ouzzane A, et al. Assessment of oncologic control obtained after open versus laparoscopic nephroureterectomy for upper urinary tract urothelial carcinomas (UUT-UCs): results from a large French multicenter collaborative study. *Ann Surg Oncol* 2012;19:301–8.
- [64] Adibi M, Youssef R, Shariat SF, et al. Oncological outcomes after radical nephroureterectomy for upper tract urothelial carcinoma: comparison over the three decades. *Int J Urol* 2012;19:1060–6.
- [65] Rodriguez JF, Packiam VT, Boysen WR, et al. Utilization and outcomes of nephroureterectomy for upper tract urothelial carcinoma by surgical approach. *J Endourol* 2017;31:661–5.
- [66] Aboumohamed AA, Krane LS, Hemal AK. Oncologic outcomes following robot-assisted laparoscopic nephroureterectomy with bladder cuff excision for upper tract urothelial carcinoma. *J Urol* 2015;194:1561–6.
- [67] Moschini M, Foerster B, Abufaraj M, et al. Trends of lymphadenectomy in upper tract urothelial carcinoma (UTUC) patients treated with radical nephroureterectomy. *World J Urol* 2017;35:1541–7.
- [68] O'Brien T, Ray E, Singh R, Coker B, Beard R. Prevention of bladder tumours after nephroureterectomy for primary upper urinary tract urothelial carcinoma: a prospective, multicentre, randomised clinical trial of a single postoperative intravesical dose of mitomycin C (the ODMIT-C Trial). *Eur Urol* 2011;60:703–10.
- [69] Ito A, Shintaku I, Satoh M, et al. Prospective randomized phase II trial of a single early intravesical instillation of pirarubicin (THP) in the prevention of bladder recurrence after nephroureterectomy for upper urinary tract urothelial carcinoma: the THP Monotherapy Study Group Trial. *J Clin Oncol* 2013;31:1422–7.
- [70] Fang D, Li XS, Xiong GY, Yao L, He ZS, Zhou LQ. Prophylactic intravesical chemotherapy to prevent bladder tumors after nephroureterectomy for primary upper urinary tract urothelial carcinomas: a systematic review and meta-analysis. *Urol Int* 2013;91:291–6.
- [71] Matin SF, Margulis V, Kamat A, et al. Incidence of downstaging and complete remission after neoadjuvant chemotherapy for high-risk upper tract transitional cell carcinoma. *Cancer* 2010;116:3127–34.
- [72] Seisen T, Jindal T, Karabon P, et al. Efficacy of systemic chemotherapy plus radical nephroureterectomy for metastatic upper tract urothelial carcinoma. *Eur Urol* 2017;71:714–8.
- [73] Leow JJ, Martin-Doyle W, Fay AP, Choueiri TK, Chang SL, Bellmunt J. A systematic review and meta-analysis of adjuvant and neoadjuvant chemotherapy for upper tract urothelial carcinoma. *Eur Urol* 2014;66:529–41.
- [74] Seisen T, Krasnow RE, Bellmunt J, et al. Effectiveness of adjuvant chemotherapy after radical nephroureterectomy for locally advanced and/or positive regional lymph node upper tract urothelial carcinoma. *J Clin Oncol* 2017;35:852–60.
- [75] Ploussard G, Xylinas E, Lotan Y, et al. Conditional survival after radical nephroureterectomy for upper tract carcinoma. *Eur Urol* 2015;67:803–12.
- [76] Shigeta K, Kikuchi E, Hagiwara M, et al. The over time conditional survival of intravesical recurrence in upper tract urothelial carcinoma. *J Urol*. In press. <http://dx.doi.org/10.1016/j.juro.2017.06.073>.