

British Association of Urological Surgeons (BAUS) consensus document: Management of ureteric and bladder injury

Authors: Arun Sahai, Ased Ali, Rachel Barrett, Mohammed Belal, Suzanne Biers, Rizwan Hamid, Christopher Harding, Richard Parkinson, Sheilagh Reid, Nikesh Thiruchelvam

Section of Female, Neurological and Urodynamic Urology, British Association of Urological Surgeons

Institutions:

Arun Sahai, Urology Consultant, Guy's and St. Thomas' NHS Foundation Trust, London, UK

Ased Ali, Urology Consultant, Pinderfields Hospital, Wakefield, UK

Rachel Barrett, Urology Specialist Trainee, University College London Hospitals, London, UK

Mohammed Belal, Urology Consultant, Queen Elizabeth Hospital, Birmingham, UK

Suzanne Biers, Urology Consultant, Addenbrooke's Hospital, Cambridge, UK

Rizwan Hamid, Urology Consultant, University College London Hospitals and London Spinal Injuries Unit, Stanmore, UK

Chris Harding, Urology Consultant, *Newcastle* upon Tyne Hospitals - NHS Foundation Trust, Newcastle, UK

Richard Parkinson, Urology Consultant, *Nottingham* University Hospitals NHS Trust, UK

Sheilagh Reid, Urology Consultant, Princess Royal Spinal Injuries Unit, Northern General Hospital, Sheffield (FNUU chair)

Nikesh Thiruchelvam, Urology Consultant, Addenbrooke's Hospital, Cambridge, UK

Address for correspondence: arun.sahai@gstt.nhs.uk

This article has been accepted for publication and undergone full peer review but has not been through the copyediting, typesetting, pagination and proofreading process, which may lead to differences between this version and the [Version of Record](#). Please cite this article as [doi: 10.1111/BJU.15404](https://doi.org/10.1111/BJU.15404)

This article is protected by copyright. All rights reserved

COI /Disclosures: (none related to this work for any author)

AS – Allergan, Medtronic, Ferring, Boston Scientific, Saluda Medical

AA – None

RB – None

MB – Astellas, Allergan, Medtronic

SB – Boston Scientific

RH – Allergan, Astellas, Pfizer, Laborie

CH – Astellas, Medtronic, Allergan, GlaxoSmithKline, Teleflex Medical

RP – None

SR – None

NT – Boston Scientific, Teleflex Medical, Coloplast

Word Count: 4848

Consensus Document

Acknowledgements: Jeremy Ockrim, Sachin Malde, Andrew Symes, Muhammed Shamim Khan for their expert comments

COI /Disclosures for experts:

JO – Astellas, Ferring, Coloplast, Medtronic, Axonics, Allergan, Boston Scientific, Contura

SM – Medtronic, Saluda Medical, Boston Scientific

AS – Lumenis, Urology Representative on BOAST guideline

MK - none

Accepted Article

MR. ARUN SAHAI (Orcid ID : 0000-0003-4679-0506)

MS. RACHEL BARRATT (Orcid ID : 0000-0002-6836-2118)

MR. NIKESH THIRUCHELVAM (Orcid ID : 0000-0002-2910-2209)

Article type : Review

Abstract

Injuries to the bladder and ureter are uncommon but usually require prompt urological management. Due to their infrequent nature, Urologists maybe unfamiliar with managing these acute problems and may not work in specialist centres with readily available expertise in open and abdominal surgery.

We aim to provide advice in the form of a consensus statement led by the Female, Neurological and Urodynamic Urology (FNUU) Section of the British Association of Urological Surgeons (BAUS), in consultation with BAUS members and consultants working in units throughout the UK, to create a comprehensive management pathway and a series of statements to aid clinicians.

Keywords: bladder injury, bladder reconstruction, bladder trauma, iatrogenic injury, ureteric injury, ureteric reconstruction, ureteric trauma, ureteral injury

Introduction

Injuries to the bladder and ureter are uncommon but usually require prompt urological management. Due to their infrequent nature, Urologists maybe unfamiliar with managing these acute problems and may not work in specialist centres with readily available expertise in open and abdominal surgery. As such the British Associations of Urological Surgeons (BAUS) section of Female, Neurological and Urodynamic Urology (FNUU) have developed this consensus document for bladder and ureteric injury to aid clinicians in their management. The detailed techniques of bladder or ureteric reconstruction are beyond the scope of this document, but principles of reconstruction which are applicable to all repairs are discussed.

Methods

The BAUS FNUU Executive Committee are an elected group of urologists with an interest in the field of female urology, neurourology, urodynamics and reconstruction of the urinary tract. It was identified that bladder and ureteric injury are important areas of practice in both the emergency and elective setting and standardisation of urological practice in the UK would be beneficial. Following FNUU Executive Committee discussion, a literature search was performed with incorporation of aspects of the existing guidance from the European Association of Urology (EAU) and American Urological Association trauma guidelines, a previous consensus document on the subject, key papers and further informed by UK best practice, to provide a framework for assessment, investigation and management of these patients. The document underwent multiple rounds of review by AS and NK, 3 rounds of review by all FNUU Section Executive Committee members as a group, and then was sent to four external experts for independent review and further comments. The revised document was then re-discussed within the FNUU Executive Committee and then distributed to all BAUS FNUU membership for widespread scrutiny. This revised document was rediscussed at the FNUU Executive Committee and consensus meetings on 22nd October 2020, presented at the annual BAUS meeting on 11th November 2020 for final comments before being sent to BAUS council for final approval. The methodology is summarised in Figure 1. These statements provide guidance for the management of bladder and ureteric injury.

Bladder injury

Bladder injury from blunt abdominal trauma is rare (<2%). As the bladder is surrounded by the bony pelvis, pelvic fractures account for the majority of bladder injuries (60%). Approximately 60% of bladder injuries are extraperitoneal, 30% are intraperitoneal, and the remaining 10% are both extra

and intraperitoneal. Iatrogenic injuries can occur with laparoscopic port placement, pelvic and endoscopic surgery and catheter placement. Rarely, spontaneous rupture may occur but this should be considered in patients who have had significant overdistension, especially in the context of reconstructed bladders. Antibiotics should be considered when there is a bladder injury and be given based on the clinical scenario and local microbiology guidance.

Trauma

Most traumatic bladder injuries will be diagnosed radiologically in the acute setting. This will usually be by a trauma protocol contrast enhanced computerised tomography (CT) scan. If there is no visible contrast leak and the index of suspicion remains high (by mechanism of injury pelvic pain, symptoms of retention, anuria, haematuria), formal CT cystogram or a fluoroscopic cystogram (typically 200-300 mL of dilute contrast medium) should be performed. If a bladder injury is diagnosed, this should be further classified into intraperitoneal, extraperitoneal or both. Ureteric and urethral injury should also be considered.

BAUS recommendation 1

When there is a high index of suspicion of bladder trauma, the diagnosis must be confirmed with contrast enhanced computerised tomography (CT) scan. If a bladder injury is diagnosed, this should be classified into intraperitoneal, extraperitoneal or both. Ureteric and urethral injury should also be considered.

Extraperitoneal

Initial management will usually involve urethral catheterisation. These injuries often heal with catheterisation alone, but open repair should be considered if the injury is major or the catheter does not stay in the bladder. Standard management usually involves leaving the catheter in place for 2-3 weeks. Extraperitoneal ruptures that do not heal after 3 months of catheter drainage should be considered for surgical repair. Any complicated extraperitoneal bladder injuries (such as those with associated bone fragments within the bladder, entrapment of the bladder wall by pelvic bones, vaginal, rectal or bladder neck injuries) usually require urgent operative repair. A cystogram should be performed to check the bladder has healed prior to catheter removal. A pelvic haematoma is not an indication on its own for surgical exploration and equally, if performing a laparotomy, aim to leave the haematoma undisturbed.

BAUS recommendation 2

Extraperitoneal bladder injuries can be managed with catheterisation alone for 2-3 weeks. Surgical repair is warranted in the case of a large bladder defect or for any associated injuries. A cystogram should be performed prior to catheter removal.

Intraperitoneal or mixed

These injuries require early catheterisation and then usually open repair. Conservative management may lead to sepsis, peritonitis and fistula formation. Surgery may involve allied specialties to deal with bone and viscus injuries. Laparoscopic or robotic repair is feasible if expertise is available but lack of immediate availability or a deteriorating patient should not delay open surgery.

After open repair, a suprapubic catheter should be considered, in addition to the urethral catheter, as urethral catheters may block or fall out. The benefits of a suprapubic and urethral catheter outweigh the risks of urethral catheterisation alone during open bladder repair. Exceptions may include a simple, small injury to the bladder. There is no additional risk to orthopaedic repair by placement of a suprapubic catheter.

Conservative management of small intraperitoneal injuries, with good urinary drainage (catheter +/- drain), antibiotics and careful patient observation, in clinically well patients is possible. A cystogram should be performed to check the bladder has healed prior to catheter removal.

Baus recommendation 3

Intraperitoneal bladder injury usually requires open repair with subsequent drainage by a urethral catheter and preferably also a suprapubic catheter for 2-3 weeks. Exceptions may include a simple, small injury to the bladder. A cystogram should be performed prior to catheter removal.

Iatrogenic injury

Management will depend on when the injury is diagnosed. Most bladder injuries are identified intra-operatively. A visible hole, a visible catheter, clear fluid in the intra-operative field, macroscopic haematuria or gaseous distension of a catheter bag during a laparoscopic procedure suggest a bladder injury. If after visual inspection, it is unclear if there is a bladder injury, a cystoscopy should be performed. Dilute Methylene blue or normal saline flushed through the urethral catheter may assist in identifying the injury and infrequently, an on-table cystogram may be necessary. Consider

ureteric injury and if there is any suspicion of one, bilateral retrograde ureterograms should be performed.

Intraoperative injury will require direct repair if observed during laparoscopic or open surgery. If the injury occurred during laparoscopic or robotic assisted laparoscopic surgery, if the expertise is available, then it would seem reasonable to perform laparoscopic or robotic assisted laparoscopic repair. However, at time of the writing, most UK urologists should feel no hesitation in converting the surgery to an open bladder repair. If the injury occurred during open surgery, the surgeon should continue with an open bladder repair. Drainage post repair should be with urethral and preferably suprapubic catheterisation. Exceptions may include a simple, small injury to the bladder. Most endoscopic bladder injuries (such as during a transurethral resection of bladder tumour) or perforation with a trocar during stress urinary incontinence surgery can be managed with catheterisation and close observation. Surgical exploration and repair should be performed after a TURBT if there is a large intraperitoneal injury or evidence of acute intraoperative abdominal distension. During exploration careful bowel inspection should be performed to exclude a concomitant injury. Catheterisation may last from 2-3 weeks. A cystogram should be performed prior to catheter removal.

Postoperatively an injury maybe diagnosed by haematuria, urine in an abdominal drain, abdominal distension, an ileus or an elevated serum creatinine. Diagnosis should initially be made by imaging, ideally by a CT or fluoroscopic cystogram. Proceeding with an urgent open repair will depend on the clinical condition of the patient, duration since surgery and site of the bladder injury. Maximal urinary drainage should be obtained which may involve simple urethral catheterisation but may also involve image guided suprapubic or bilateral nephrostomy drainage or externalised ureteric stents. If the clinical condition of the patient deteriorates due to the bladder injury and if it is clinically safe to do so, then open bladder repair should be performed.

Baus recommendation 4

Intraoperative bladder injury should be repaired by open surgery unless expertise and pre-existing approach allows a laparoscopic or robot assisted laparoscopic repair. Consider ureteric injury and if there is any suspicion of ureteric injury bilateral retrograde ureterograms should be performed. Drainage post repair should be with urethral and preferably suprapubic catheterisation. Exceptions may include a simple, small injury to the bladder. If a bladder injury is discovered postoperatively, a number of patient factors will determine if or when bladder repair should be performed.

Bladder traumatic haemorrhage

This may be intravesical or extravesical. Intravesical bleeding may occur from mucosa or detrusor haemorrhage. Extravesical haemorrhage into the pelvis or peritoneum may occur from laceration of the bladder wall or of the bladder vasculature. Management will depend on the clinical condition of the patient but options for management include cystoscopy with washout and / or diathermy, arterial radiological embolization, laparotomy +/- packing, cauterisation and rapid suture ligation of bleeding points/vessels. As a last resort, cystectomy maybe required.

Baus recommendation 5

Management will depend on the clinical condition and expertise available and may involve arterial radiological embolization or endoscopic or surgical control.

Intravesical foreign bodies

Iatrogenic or placed foreign bodies should ideally be removed cystoscopically. If this fails or if the item is too large to pass through the urethra safely and cannot be broken in the bladder, or has sharp edges, perform percutaneous or open removal of the foreign body.

Baus recommendation 6

Intravesical foreign bodies should be removed cystoscopically or by open surgery if this is not possible.

Principles of open repair

A urethral catheter should be in situ. Perform a lower midline or a pfannenstiel laparotomy. The abdomen and pelvis should have adequate exposure which may involve lengthening a pre-existing incision. Good retraction with equipment such as an Omni-tract® (Integra Life Sciences) or Bookwalter® (Surgical symmetry) retractor will allow good exposure to the surgical field for repair. Bowel should be packed away. Examine the whole bladder which may involve extending the injury further or debriding back to clean edges. Consider ureteric involvement (see below). Mobilise the attachments of the bladder to allow good approximation of the bladder edges without tension. Place a suprapubic catheter unless the injury is small and simple. Close the bladder with absorbable

sutures in either a single full-thickness layer or two-layer closure, ensuring mucosa to mucosa apposition, this can be by continuous or interrupted suturing (or a combination). If possible, interpose omentum over the repair and hold in place with an absorbable suture. Place a non-suction drain before wound closure. Catheters should remain on free drainage until a cystogram is performed at 2-3 weeks. If there is concern of difficulty in bladder emptying, remove the urethral catheter with the suprapubic catheter clamped to check for bladder emptying ability.

Baus recommendation 7

Important aspects of surgery involve adequate exposure, urethral catheterisation, mobilisation of the bladder, closure of the bladder injury with absorbable sutures, without tension in a continuous or interrupted fashion with interposition of omentum. Place a suprapubic catheter unless the injury is small and simple. Leave a non-suction drain. At 2-3 weeks, perform a cystogram prior to catheter removal.

Ureteric injury

Ureteric trauma is rare and accounts for approximately 1-2.5% of all urinary tract trauma. The ureters due to their location, course and mobility are generally protected from traumatic injury. Injury to the ureter is usually iatrogenic (80%) and is often missed at the time of the original surgery. These injuries are typically related to pelvic surgery from gynaecological, colorectal or urological procedures such as ureteroscopy. Of the remainder, approximately 2/3 are penetrating and 1/3 blunt trauma. Penetrating abdominal trauma, especially gunshot wounds, can cause ureteric injury in 2-3% of cases and so must be considered in the workup. The commonest mechanism of blunt injury to the ureter is a deceleration injury classically seen in motor vehicle accidents and usually involves the pelvi-ureteric junction. These types of injury are more common with anomalies to the upper urinary tract such as pelviureteric junction obstruction.

Management strategy

The work up and management of patients with ureteric injury will depend on whether the presentation is immediate or delayed and whether other injuries co-exist and their severity (see Figure 2). Blunt and iatrogenic causes of ureteric trauma are more likely to present after a delay. In general, the ureter can be divided anatomically into abdominal, pelvic and intramural segments or in

radiological terms can be demarcated into: proximal (above the sacro-iliac joint), mid (sacro-iliac joint) and distal (below sacro-iliac joint). The distal ureter is the most common site of injury.

Patients should have urine sent for dipstick and culture and bloods including full blood count, urea, creatinine and electrolytes. Assessment is best with a CT-urogram in those who do not require an immediate laparotomy. A contrast CT scan of the abdomen and pelvis will allow detailed imaging of the bones and organs and a delayed phase will allow assessment of the ureter. This is typically done with further scanning 10 minutes following contrast administration. Positive signs to look for include: frank extravasation of contrast from the ureter, hydronephrosis, free fluid and ureteric dilatation. If despite CT imaging, there is doubt then cystoscopy and retrograde studies are recommended to delineate the ureter and look for injury.

Ureteric injury can be graded according to the American Association for the Surgery of Trauma scale and can broadly be separated into contusion, partial and complete injury.

Antibiotics should be considered and be given based on the clinical scenario and local microbiology guidance.

The type of repair will depend on the severity and location of injury. A very short segment injury due to suture ligation maybe successfully treated with ureteric stenting in the acute setting. However, in the majority formal reconstruction will be required. In the distal ureter options include uretero-neocystostomy with or without psoas hitch. In the mid ureter, Boari flap, transuretero-ureterostomy or uretero-ureterostomy. In the proximal ureter the options are as per the mid ureter but also uretero-calycostomy. When there is significant ureteric loss, options include auto-transplantation, interposition with bowel, graft interposition e.g. buccal mucosa and nephrectomy. A further option may include renal mobilisation and a long Boari flap.

At 4-6 weeks following repair, the covering ureteric stent should be removed and further imaging at 3 months is recommended in the form of a MAG3-renalogram or CT-urogram. Additional imaging should also be performed at 12 months.

Baus recommendation 8

Ureteric trauma should be considered in trauma patients with penetrating injuries in or near the course of the ureter and in blunt trauma with deceleration injuries.

Unless patients require an immediate laparotomy the investigation of choice of a suspected ureteric injury is a CT urogram +/- cystoscopy + retrograde studies if required

The type of repair will be dependent on location and type of injury

At 4-6 weeks following repair, the covering ureteric stent should be removed and further imaging at 3 months is recommended in the form of a MAG3-renalogram or CT-urogram. Additional imaging should also be performed at 12 months.

Principles of ureteric reconstruction

In all ureteric reconstructive surgery important surgical principles include

- careful ureteric mobilisation with preservation of adventitia and blood supply
- debridement of all necrotic tissue to leave clean margins
- wide spatulation of ureteric lumens
- tension free ureteric repair over a double J stent using absorbable sutures
- placement of a non-suction drain adjacent to the repair
- where possible isolation of the reconstruction using omentum or peritoneum
- the choice between a refluxing or non-refluxing anastomosis will depend on the clinical scenario and the surgeon's expertise / preference

Baus recommendation 9

The principles of ureteric reconstruction including careful mobilisation preserving blood supply, spatulation and tension-free anastomosis over a stent together with an omental wrap must be adhered to for a successful repair.

Trauma

Trauma patients should be managed as per Advanced Trauma Life Support guidelines when they arrive to hospital. Penetrating ureteric injuries should be suspected when there has been significant abdominal trauma affecting bowel / bladder / vascular structures or when for example a gunshot wound has been in and or around the course of the ureter. In cases of blunt trauma, injury to the ureter should be considered when there has been a decelerating injury or injury to the lumbo-sacral

spine or bones of the pelvis. Haematuria is an unreliable symptom / sign and its absence does not exclude a ureteric injury.

Some patients who are unstable may need to go straight to theatre for a laparotomy. In such cases the ureters should be inspected for injury. This may require gentle mobilisation, the use of intravenous or directly injected agents such as indigo carmine or methylene blue to help identify injury or cystoscopy and retrograde studies. The use of single shot intravenous urography 'on table' in this setting is no longer recommended, as it is unreliable. Ureteric injury identified at time of laparotomy should be repaired. However, in unstable patients, once life threatening injuries have been managed, it is appropriate to either ligate the ureter and place a nephrostomy tube or place a ureteric catheter secured at the proximal injury margin which is then exteriorised along with a drain near the site of injury. The patient can then return to theatre when clinically stable for a definitive repair at a later interval in the subsequent days. Areas of contusion but with intact ureters should be managed on a case by case basis. Where there is risk or concern for delayed breakdown with necrosis and subsequent urine leak and / or stricture, stenting should be employed, and the ureter re-assessed with retrograde studies at a minimal interval of 6 weeks. In cases of severe contusion, segmental resection and uretero-ureterostomy should be considered.

In all other cases patients should be assessed with a CT-urogram +/- cystoscopy and retrograde studies to delineate the anatomy. In cases of partial injury, a trial of ureteric stenting is appropriate. However, if there is a risk of extending the injury i.e. making a partial injury, complete, or there is a complete injury at diagnosis, immediate repair is warranted. The approach will depend on other injuries if present and location of the injury.

Baus recommendation 10

Trauma patients should be managed as per ATLS guidelines

Haematuria is an unreliable symptom / sign of ureteric injury

In unstable patients needing an immediate laparotomy, the ureters should be inspected for injury

In cases of ureteric injury options include immediate repair over a ureteric stent or ligation and planned nephrostomy with definitive semi-urgent repair.

In all other cases patients should be assessed with CT-urogram +/- cystoscopy and retrograde studies

In cases of partial injury a trial of ureteric stenting is appropriate

In cases of complete injury or ureteric stenting risks converting a partial to a complete injury, immediate repair is warranted

Peri-operative ureteric injury

Iatrogenic injury is the commonest mechanism of ureteric injury. Hysterectomy is the commonest cause. Other examples based on specialty include gynaecology (stress incontinence and pelvic organ prolapse surgery, caesarean section, endometriosis surgery), colorectal (abdominoperineal resection, low anterior resection) or urological surgery (ureteroscopy, radical prostatectomy). Injuries are more likely to occur in patients who have had multiple previous operations, where there is significant fibrosis, bulky tumours, significant inflammation, abnormal ureteric anatomy e.g. duplex or a radiation field.

During ureteroscopy injury to the ureter should lead to the operation being terminated and a ureteric stent being deployed. In cases where stenting is not possible or where access is lost, and in cases where a stent does not adequately divert urine from extravasation, patients should have a percutaneous nephrostomy tube inserted +/- percutaneous drainage. Assessment of the ureter at an interval is required and in cases where urinary leak is ongoing or a stricture has developed, delayed reconstruction and ureteric repair is required.

Ureteric avulsion injury is thankfully rare. In cases of complete avulsion, if the ureter is delivered whole and preserved, it can be utilised with a greater omentum wrap and concomitant pyeloureterostomy and ureteroneocystostomy. Alternatives include nephrectomy and autotransplantation or bowel interposition. In those with partial avulsion, this should be managed as described previously depending on the location of the injury. Immediate repair is best but if there is a lack of expertise available, a nephrostomy should be sited along with a drain prior to transfer.

In cases involving another specialty it is important to gather as much information as possible. The theatre in question maybe on another site and therefore one should be prepared and assume they may not have the equipment required. In all cases it is important to speak to the surgeon directly involved in the case to hear about the injury and the sister in charge of the theatre to describe what equipment you will need. A useful strategy in this scenario is to check and discuss the 5Ps (Patient, Position, Personnel, Planning, Procedure) (see Table 1). It is important when asked for an opinion or if a concern about ureteric injury is made that you, as the urologist, review and assess the case in

person. It is possible the host surgeon feels competent enough at repairing the injury, however, discourage this practice and let them know that you are on your way to deal with the problem.

Crush or suture ligation injury to the ureter (most commonly seen in attempts to control haemorrhage) if recognised promptly should be managed by release and ureteric stenting. If prolonged, then following release the affected segment should be excised and a uretero-ureterostomy should be performed. Partial ureteric transection can be managed by ureteric stenting and closure of the defect with absorbable suture. In cases of full transection this will require formal reconstruction over a ureteric stent, depending on location as highlighted previously. If the injury occurred during laparoscopic or robotic assisted laparoscopic surgery, and the expertise is available, then it would seem reasonable to perform laparoscopic or robotic assisted laparoscopic repair.

Baus recommendation 11

During ureteroscopy injury to the ureter should lead to the operation being terminated and a ureteric stent deployed

Crush / Ligation injury if immediately recognised can be managed by release and ureteric stenting with delayed retrograde studies at 6 weeks to assess for ureteric stricture

In cases of ureteric transection immediate repair is recommended over a ureteric stent. The type of repair will depend on location but must adhere to the principles of reconstruction highlighted above.

Post-operative / Delayed

The majority of iatrogenic injuries are diagnosed post-operatively. Signs and symptoms typically include loin pain on the affected side, fever, incontinence secondary to uretero-vaginal fistula, prolonged ileus and acute kidney injury (for example after sepsis or bilateral renal injury). Management will depend on when the patient presents. Patients should be assessed with a urine dipstick and MSU as well as bloods for FBC, urea, creatinine and electrolytes, and coagulation profile when indicated. A CT urogram is required to assess the urinary tract and to check for other problems such as urinoma or haemorrhage. Cystoscopy and retrograde studies and an attempt at ureteric stenting should be performed. A thorough inspection of the bladder and retrograde study on the contralateral ureter should also be performed to look for other injuries to the urinary system. A percutaneous drain may be required. If stenting is successful, then a delayed retrograde study at 6 weeks should be performed to ensure normal integrity and calibre of the ureter at the site of injury. Further functional imaging with a MAG3-renogram should be performed at 3 months. In cases

where a stricture has developed or there is ongoing leak, formal repair and reconstruction is required. The type of repair will depend on the level of injury.

In patients who have a percutaneous nephrostomy in situ already an antegrade nephrostogram is useful to delineate the level of injury. In select cases a combination of antegrade and retrograde approach can be utilised (rendez-vous procedure) to stent across the site of ureteric injury.

In cases where stenting is unsuccessful and the injury is within 14 days, a primary repair according to the level of injury over a ureteric stent should be performed. If the patient is not medically fit a percutaneous nephrostomy should be inserted.

In cases where the injury is significantly delayed e.g. > 14 days and ureteric stenting is not possible, a percutaneous nephrostomy should be inserted. In such cases a delayed primary repair and reconstruction should be performed at 3-6 months depending on the degree of urinary contamination. Balloon dilatation or endoscopic incision is usually not successful as a treatment option.

Uretero-vaginal fistula may be managed successfully with a ureteric stent. In cases where there is ongoing leak, or if a stricture develops a ureteric re-implantation should be performed.

Baus recommendation 12

CT-urogram should be performed to assess the urinary system and the presence of other abdominal pathology

Cystoscopy and ureteric stenting should be attempted and assessment of the rest of the urinary tract performed at the same sitting

An immediate primary repair can be performed if the injury is within 14 days

In cases of failed stenting a percutaneous nephrostomy should be inserted +/- abdominal drain

A delayed repair at 3-6 months should be performed in cases where presentation is > 14 days and stenting is not possible or in those who have ongoing urinary leak or develop a stricture after the placement of a ureteric stent. Balloon dilatation or endoscopic incision is usually not successful as a treatment option.

Late presentation of injury or insult

A number of other conditions not related to trauma could affect the ureter and lead to stricture formation or obstruction and include radiotherapy, TB, schistosomiasis, malignancy, endometriosis or retroperitoneal fibrosis. Symptoms and work up are similar to post-operative or delayed presentation. Patients should have urine sent for dipstick and culture and bloods including FBC, urea, creatinine and electrolytes. It is worth noting in cases of gradual obstruction, patients may be asymptomatic. The ureter is best assessed with a CT-urogram +/- cystoscopy + retrograde studies or via an antegrade study if a nephrostomy tube is present to understand the level of obstruction and severity. In cases of long-standing obstruction where cross sectional imaging has suggested a poorly functioning kidney or there is a doubt, a nuclear medicine DMSA scan should be requested or MAG3-Renogram in cases where obstruction is not clear. Both scans will allow assessment of kidney function which will help dictate future management. Management will be based on disease severity, level of ureter affected, kidney function and pathology. Non-malignant cases which involve obstruction or stricture formation should be managed initially with a ureteric stent to preserve renal function. Definitive repair and reconstruction in adequately functioning kidneys can then be performed dependent on location of injury. The repair and reconstruction of the ureter can be via the open, laparoscopic or robotic assisted laparoscopic approach depending on the expertise available. Malignant cases should be discussed in a multi-disciplinary meeting for that specialty cancer and be managed according to NICE guidelines.

Baus recommendation 13

Assessment of level and degree of ureteric involvement is best achieved with a CT-urogram +/- cystoscopy + retrograde studies

In select cases nuclear medicine scanning is recommended to ascertain kidney function

Management of the ureteric injury will depend on kidney function, level of injury and patient factors

Prevention of bladder / ureteric injury

The most important factor in preventing injury is direct inspection in an adequately exposed surgical field. Care must be taken to avoid skeletonising the ureteric blood supply or using diathermy on or near the ureter as this will lead to ischaemic stricture and thermal injury, respectively. Thermal injury will lead to a delayed ureteric injury which may present as either a urine leak or stricture. Pre-operative cross-sectional imaging needs to be up to date, in particular those for malignancy. In select

Accepted Article

cases ureters can be stented pre-operatively either electively or at the start of the procedure. This is appropriate in patients with advanced malignancy, where significant inflammation or fibrosis is likely or in patients with multiple previous surgeries. This is best discussed where possible well in advance of the planned surgery preferably at multi-disciplinary meetings. Stenting may help surgeons feel the ureter via tactile feedback in certain locations and identify injury when it occurs, the majority of the time. However, stenting does not prevent injury. Inventive options include ureteric stents that can transilluminate or intravenous administration of novel agents which result in renal excretion of a near-infrared fluorescent dye in the ureter. The urethral catheter can be filled to help distend the bladder to aid identification during surgery.

Baus recommendation 14

Ureteric stenting should be used in high risk cases to help identify the ureter and intra-operative ureteric injury

Indications for Referral to Specialist Units

If no expertise is available to manage the ureteric injury in the acute setting, temporising measures should be employed where possible depending on circumstances e.g. percutaneous nephrostomy +/- drain or ureteric stenting and patients referred for further urgent management.

Appendix 1 Recommended reading

American Urological Association (AUA) Urotrauma guideline (2020)

European Association of Urology (EAU) Guideline on Urogenital Trauma (2020)

Brandes et al., Diagnosis and management of ureteric injury: an evidence based analysis. *BJU Int.* 2004 Aug;94(3):277-89.

Frober. *Surgical Atlas. Surgical Anatomy of the Ureter.* *BJU* 2007 100: 949-965

Stein et al. *Surgical Atlas. Psoas Hitch and Boari Flap Ureteroneocystostomy.* *BJU* 2013 112: 137-155

Table 1 Source - from Datta et a., BJUI 2013 112(5):540-2.

Patient	Who is the patient in terms of: sex, co-morbidity, body mass index, epidural/spinal/general anaesthetic? Cross match sent? Is there a urethral catheter?
Position	What position is the patient in? Laparoscopic operation? Is that patient on an X-ray compatible table? What does the referring surgeon think is injured?
Personnel	Who is around and what seniority? Has the consultant been informed, if not present? Are the theatre staff familiar with cystoscopy, stack systems and urological stenting? Is there a radiographer with an image intensifier available?
Planning	Is an open repair necessary or could it be done laparoscopically? Is there laparotomy instrument set available? Are the relevant sutures available? Will the patient need to be transferred to an X-ray table. Is there sufficient equipment to perform a safe retrograde and stenting? Are X-ray gowns available?
Procedure	Depends largely on the procedure attempted. Ureteric repair or re-implantation: guidewires, stents and contrast. If checking bladder or bilateral ureteric integrity, consider checking: the stack system is working, cystoscope, guidewires, ureteric catheter, contrast and two JJ stents. Make detailed legible medical notes. Leave contact details with clear postoperative plan.

Figure 1: Consensus Methodology

Consensus document methodology

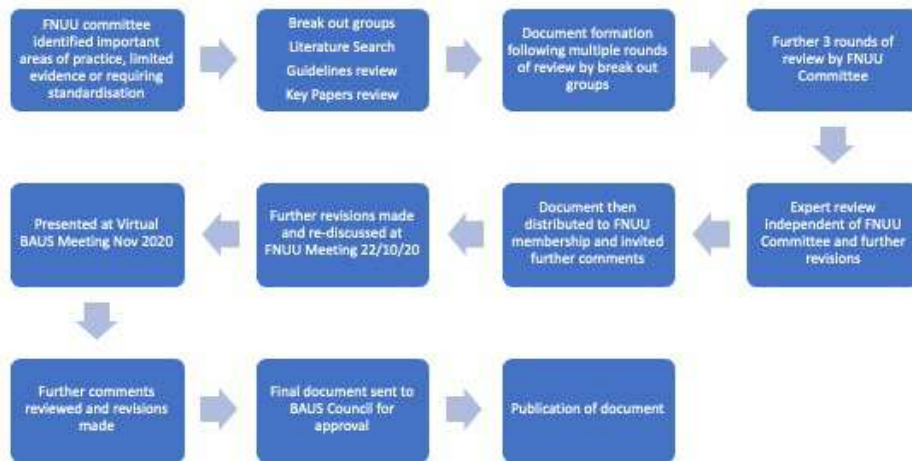


Figure 2: Management of ureteric Injury

