




## GUIDELINES

# 2024 European guidelines for the management of genital herpes

Rajul Patel<sup>1,2</sup>  | Benjamin Moran<sup>3</sup> | Emily Clarke<sup>4,5</sup> | Anna Maria Geretti<sup>6,7,8</sup> |  
 Stephan Lautenschlager<sup>9</sup> | John Green<sup>10</sup> | Gilbert Donders<sup>11</sup> | Mikhail Gomberg<sup>12</sup>  |  
 Shyam Samraj<sup>8</sup> | George Sorin Tiplica<sup>13</sup>  | Elizabeth Foley<sup>1</sup>

<sup>1</sup>Department of Genitourinary Medicine, Southampton, UK

<sup>2</sup>Southampton Medical School, Southampton, UK

<sup>3</sup>Croydon University Hospital, Croydon Health Services Trust, London, UK

<sup>4</sup>Axess Sexual Health, Liverpool University Hospitals NHS Foundation Trust, Liverpool, UK

<sup>5</sup>University of Liverpool, Liverpool, UK

<sup>6</sup>University of Rome Tor Vergata, Rome, Italy

<sup>7</sup>North Middlesex University Hospital, London, UK

<sup>8</sup>King's College London, London, UK

<sup>9</sup>Swissparc Clinic and University of Zurich, Zurich, Switzerland

<sup>10</sup>Central and North West London NHS Trust, London, UK

<sup>11</sup>Department of Obstetrics and Gynecology, University Hospital Antwerp, Edegem, Belgium

<sup>12</sup>Moscow Scientific and Practical Center of Dermatovenereology and Cosmetology, Moscow, Russia

<sup>13</sup>Dermatology 2, Colentina Clinical Hospital, Carol Davila University of Medicine and Pharmacy Bucharest, Bucharest, Romania

### Correspondence

George Sorin Tiplica, Dermatology 2,  
 Colentina Clinical Hospital, Carol Davila  
 University of Medicine and Pharmacy  
 Bucharest, Bucharest, Romania.  
 Email: [george.tiplica@umfcd.ro](mailto:george.tiplica@umfcd.ro)

### Abstract

Genital herpes is one of the most common sexually transmitted infections worldwide. Using the best available evidence, this guideline recommends strategies for diagnosis, management and follow-up of the condition as well as for minimizing transmission. Early recognition and initiation of therapy is key and may reduce the duration of illness or avoid hospitalization with complications, including urinary retention, meningism or severe systemic illness. The guideline covers a range of common clinical scenarios, such as recurrent genital herpes, infection during pregnancy and coinfection with human immunodeficiency virus.

## INTRODUCTION

First infection with either herpes simplex virus type 1 (HSV-1) or type 2 (HSV-2) is termed primary infection and results in either symptomatic disease at the site of viral entry (i.e. on the face or genital area) or asymptomatic, and thus unrecognized, infection. In addition, there may be systemic symptoms, as with other acute viral illnesses. Only 25% of patients

who acquire genital herpes have any recognized clinical features at the time of acquisition.<sup>1</sup> Following infection, the virus becomes latent in the local sensory ganglion, periodically reactivating to cause symptomatic lesions, or undergo asymptomatic, but nonetheless infectious, viral shedding.<sup>2</sup> Genital herpes can be caused by either HSV-1—the usual cause of oro-labial herpes—or by HSV-2—the usual cause of genital herpes. Infection with either virus can cause an

This guideline is produced on behalf of the following organizations: International Union against Sexually Transmitted Infections (IUSTI) Europe; the European Academy of Dermatology and Venereology (EADV); the European Dermatology Forum (EDF); the Union of European Medical Specialists (UEMS). The European Centre for Disease Prevention and Control (ECDC) and the European Office of the World Health Organization (WHO-Europe) also contributed to their development.

This is an open access article under the terms of the [Creative Commons Attribution-NonCommercial-NoDerivs](https://creativecommons.org/licenses/by-nc-nd/4.0/) License, which permits use and distribution in any medium, provided the original work is properly cited, the use is non-commercial and no modifications or adaptations are made.

© 2024 The Author(s). *Journal of the European Academy of Dermatology and Venereology* published by John Wiley & Sons Ltd on behalf of European Academy of Dermatology and Venereology.

identical initial illness; however, the actual clinical presentation may depend upon previous HSV-1 or HSV-2 infection and previous sites of infection. Subsequent recurrence frequency is greater for HSV-2 than HSV-1 disease when infection involves the genital area.<sup>3</sup>

### Transmission risk

Risk of transmission appears to be greatest during lesional recurrences or prodrome and patients should be advised to abstain from sexual contact during this time. Transmission can occur in the absence of lesional recurrence as a result of sub-clinical viral shedding.<sup>2</sup> Efficacy of condoms to prevent sexual transmission has not been formally assessed; however, indirect evidence from failed vaccine trials provides strong support for their consistent usage to prevent transmission to both males and females (1, B).<sup>4,5</sup> The efficacy of condoms is easier to demonstrate in male to female transmissions where increasing consistent use results in lower levels of transmission.<sup>6</sup>

## DIAGNOSIS

### Clinical diagnosis

Although classical genital herpes can be recognized by the presence of typical papular lesions progressing to vesicle and ulcer formation, associated with local adenitis and in recurrent cases preceded by prodromal symptoms, the features in many patients can be highly variable. The majority of patients will suffer from atypical lesions where signs may be easily confused with other genital dermatoses.<sup>7</sup> In all cases, but in particular for atypical cases, clinical diagnosis alone should be avoided, running the risk of adversely affecting a relationship and adding psychological burden with stigma, without cause.

Herpes is an important cause of proctitis and should be considered in all cases and especially where a sexually transmitted infection is being considered.

### Differential diagnosis

The differential diagnosis of genital ulceration is wide but in the context of young sexually active populations in Europe presenting with painful blistering eruptions an infective cause is usually likely (Table 1. Genital ulcerations—differential diagnosis). Care must be taken to ensure that the possibility of mixed infections is considered. Syphilis is increasing in frequency and can cause painful lesions particularly in the perianal area. Herpes zoster is the cause of the genital blistering in 2% of cases (although mostly at the extremes of age)<sup>8</sup> and is frequently unilateral. Sporadic cases of Mpox are reported in at risk populations despite vaccination.

### Principle changes made to the European guidelines for the management of genital herpes

- The need for and importance of considering a wider range of pathogens when assessing a case of genital ulceration.
- The importance of excluding HSV in proctitis.
- Clearer recommendations around interpretation of type-specific serology.
- Clarification of duration of course of treatment for an initial episode of HSV.
- Recommended regimens for suppressive therapy, including recommendations for second-stage treatment for poorly controlled patients.
- Advice on investigations in those poorly controlled on suppressive therapy.
- Advice on timing the start of antivirals in pregnancy (pre-third trimester disease) based on local epidemiology of preterm delivery and neonatal herpes infection.
- Advice about refraining from sexual intercourse during pregnancy in HSV discordant couples.

Lymphogranuloma venereum can also present as perianal ulceration, with or without proctitis.<sup>9</sup>

### Laboratory diagnosis

#### Virus detection

- Laboratory confirmation is recommended in all patients with suspected genital herpes, using methods that directly demonstrate the virus in genital specimens, typically swabs should be taken from the base of the lesion (vesicles should be unroofed with a needle or scalpel blade) (1, A).<sup>1</sup> Viral detection in early disease (for both first episodes and recurrences) are much more likely to be successful. In suspected recurrent disease, patient taken swabs (at home) can be better at demonstrating virus than those taken in clinical settings. Viral production rapidly peaks during a herpes episode and swabbing for laboratory confirmation should not be delayed.
- HSV typing into HSV-1 and HSV-2 is recommended in all patients with first-episode genital herpes to guide counselling and management (1, C).<sup>4</sup>
- As HSV shedding is intermittent, testing swabs from asymptomatic patients is not recommended for routine diagnosis as it is unlikely to yield confirmation of carrier status (1, A).<sup>4</sup>
- HSV DNA detection is now considered the gold standard for diagnosis. Compared with cell culture it is both more sensitive and specific (1, A)<sup>1,10-14</sup> and increases HSV

detection rates in muco-cutaneous swabs by 11%–71% and is recommended as the preferred diagnostic method (1, A).<sup>1,13,14</sup> Real-time PCR can tolerate less stringent conditions for sample storage and transport than virus culture, and allows the rapid detection and typing of HSV with a lower risk of contamination than traditional PCR assays. Cell culture may occasionally be required to determine anti-viral sensitivity, but it is increasingly unavailable to clinicians.

- Viral antigen detection methods such as direct immunofluorescence assay (IFA), enzyme immunoassay (EIA) and Tzanck and Papanicolaou staining are no longer recommended except in extremely limited resource settings (1, A).<sup>15–17</sup>
- In cases of unexplained culture negative sepsis unresponsive to antibiotic therapy, HSV PCR testing of tissues possibly involved at the possible port of entry are recommended (3, D).<sup>18</sup>

## HSV type-specific serology

Serological testing is not routinely recommended in asymptomatic patients (1, D), but may be useful in the following groups.<sup>2,4,19–23</sup>

- History of recurrent or atypical genital disease when direct virus detection methods have been negative (1, C). HSV-2 antibodies are supportive of a diagnosis of genital herpes; HSV-1 antibodies do not differentiate between genital and oro-pharyngeal infection. Counselling of HSV-2 IgG-negative, HSV-1 IgG-positive patients should take into account that HSV-1 genital infection is showing a substantial increase in incidence among younger populations.<sup>24</sup>
- First-episode genital herpes, where differentiating between primary and established infection guides counselling and management (1, C). At the onset of symptoms, the absence of HSV IgG against the virus type detected in the genital lesion is consistent with a primary infection.<sup>4</sup> Seroconversion should be demonstrated at follow-up, typically at 90 days.
- Sexual partners of patients with genital herpes, where concerns are raised about transmission. Serodiscordant couples can be counselled about strategies to reduce the risk of infection and disease (1, A).<sup>17</sup>
- Asymptomatic pregnant women should be routinely recommended to be tested if there is a history of genital herpes in the partner (1, B).<sup>25–27</sup> HSV-1 and/or HSV-2 seronegative women should be counselled about strategies to prevent a new infection with either virus type during pregnancy.

Care must be taken in interpreting negative results as antibodies to both HSV-1 and 2 may not form or be lost with time.

Limited data suggest an increased risk of perinatal HIV transmission among HSV-2 seropositive HIV-infected women.<sup>28,29</sup> As evidence is not consistent, testing of pregnant

women living with HIV is not routinely recommended (1, D).<sup>30</sup>

HSV serological assays that detect antibodies against the antigenically unique glycoproteins gG1 and gG2 should be used.<sup>17,31</sup> Non type-specific HSV antibody assays are of no value in the management of genital herpes.

Western blot (WB) is the serological diagnostic gold standard. It is >97% sensitive and >98% specific but is labour-intensive and not commercially available.<sup>32,33</sup>

The sensitivities and specificities of commercially available seroassays can vary significantly across populations.<sup>34–43</sup> The positive predictive value (PPV) in low prevalence settings can make results uninterpretable. False-negative results are more likely to occur in early infection and can be resolved by repeat testing.

HSV seroprevalence rates, the presence of risk factors for genital herpes and clinical history influence the PPV of HSV type-specific serology and should guide testing and result interpretation (1, C).<sup>2,29–38</sup> The specificities of ELISA tests can be improved by raising the index value for interpreting positivity and testing all intermediate specimens with an alternate confirmatory test (1, B).<sup>33,34,36–38</sup>

IgM testing is not recommended in routine clinical practice. Studies suggest that 12%–30% of patients lose their HSV type-specific IgG antibodies depending on their HSV types and the test used.<sup>44</sup>

## Other investigations

Zoster PCR tests should be performed to exclude this diagnostic when the genital manifestations are not clearly suggesting HSV infection (e.g. expanding groups of vesicles and unilateral distribution of the lesions).

Tests for other STI: syphilis, chlamydia, *Neisseria gonorrhoeae*, *Mycoplasma genitalium* and *Trichomonas vaginalis* are indicated due to the risk of combined transmission during sexual contact.<sup>45</sup>

## MANAGEMENT OF GENITAL HERPES

### First-episode genital herpes

#### Indications for therapy

First episodes of genital herpes are frequently associated with a prolonged disease course (Figure 1).<sup>46</sup> Untreated, many patients suffer general and local complications. Therapy can be highly effective and should be instigated at the earliest opportunity and on clinical suspicion alone (1,A).<sup>46</sup>

#### Antivirals

Patients presenting within 5 days of the start of the episode, or while new lesions are still forming, should be given oral

**TABLE 1** Genital ulceration—differential diagnosis.

<b>(a) Infectious</b>	<b>(b) Tumoral</b>	<b>(c) Inflammation</b>
Apthous ulcers associated with cytomegalovirus or Epstein-Barr virus	Acanthosis nigricans	Angioedema
Bullous impetigo	<b>Bartholin duct abscess</b>	Atopic dermatitis (eczema)
Candida albicans	Basal cell carcinoma	Behçet's disease
Chancroid	<b>Epidermal cyst</b>	Contact dermatitis (allergic, irritant)
Chlamydia trachomatis L1-L3	Extramammary Paget disease	Crohn disease
Granuloma inguinale (Donovanosis)	Fibroepithelial polyp	Fixed drug eruption
<b>Herpes Simplex Virus</b>	Hidradenoma papilliferum	Fox Fordyce disease
Herpes zoster	Kaposi sarcoma	Hidradenitis suppurativa
<b>Infectious non-STI</b>	Lipoma	Keratosis pilaris
LGV	Melanocytic nevus	Langerhans histiocytosis
Mpox	Melanoma	Lichen planus
Scabies	Miliium	Lichen sclerosus
<b>Syphilis</b>	Neurofibroma	Lichen simplex chronicus
Syphilitic Balanitis of Follmann	Pyogenic granuloma	Lipschutz ulcer
<b>(d) Bullous diseases</b>	Scar	<b>Physiologic hyperpigmentation</b>
Cicatrical pemphigoid	Seborrheic keratosis	Plasma cell vulvitis
Epidermolysis bullosa acquisita	<b>Squamous cell carcinoma</b>	Postinflammatory hypopigmentation
Hailey-Hailey disease	Syringoma	<b>Prurigo nodularis</b>
Linear IgA disease	Verrucous carcinoma	<b>Psoriasis</b>
Non-accidentally trauma in children	Vulvar intraepithelial neoplasia	Pyoderma gangrenosum
<b>Pemphigoid</b>	Vulvar melanosis/lentiginosis	Sarcoidosis
Pemphigoid gestationis	Vulvar papillomatosis	Stevens-Johnson syndrome
<b>Pemphigus</b>	<b>(e) Vascular</b>	Toxic epidermal necrolysis
Subcorneal pustular dermatosis	<b>Angiokeratoma</b>	<b>(f) Trauma</b>
	Cherry angioma	Post-surgical
	Granulomatosis with polyangiitis	Post-irradiation
	Hemangioma	<b>Accidental and self-induced (penile injury, immersion burns, traumatic)</b>
	Lymphangioma	
	Milroy's congenital edema	

First-episode genital herpes	Recurrent genital herpes			
	Episodic antiviral treatment		Suppressive therapy	
	Short course therapies	Alternative longer courses	First stage	Second stage suppressive therapy
Aciclovir 400 mg x3/day, 5-10 days	Aciclovir 800 mg x3/day, 2 days	Aciclovir 400 mg x3/day, 5 days	Aciclovir 400mg x2/day	Aciclovir 400mg x3/day
Aciclovir 200 mg x5/day, 5-10 days		Aciclovir 200 mg x5/day, 5 days		
Valaciclovir 500 mg x2/day, 5-10 days	Valaciclovir 500 mg x2/day, 3 days	Valaciclovir 500 mg x2/day, 5 days	Valaciclovir 500 mg – 1000 mg /day	Valaciclovir 500mg x2/day
Famciclovir 250 mg x3/day, 5-10 days		Famciclovir 125 mg x2/day, 5 days		

**FIGURE 1** Management of genital herpes.

antiviral drugs. Aciclovir, valaciclovir and famciclovir are all effective in reducing the severity and duration of episode (1, A).<sup>46,47</sup> No therapy alters the natural course of genital herpes infection.

Topical agents are not recommended as they are less effective than oral agents and easily generate resistance (1, D).<sup>48</sup>

The only indication for the use of intravenous therapy is when the patient is unable to swallow or tolerate oral

medication because of vomiting. The recommended regimens—all for 5–10 days—are as follows:

- Aciclovir 400 mg three times a day or
- Aciclovir 200 mg five times a day or
- Famciclovir 250 mg three times a day or
- Valaciclovir 500 mg two times a day.

Choice should be made by individual clinicians, taking cost of therapy and likely compliance into account. A number of patients will have extended episodes beyond 5 days. If a decision to provide 5 days of therapy is made, the patient should have early review to ensure they have no further lesion development, systemic symptoms or disease complications—they all will require extended therapy. It will often be expedient to provide at least a 7-day course of treatment to ensure the patient does not run out of therapy at a weekend.

### Supportive measures

Bathing with normal saline and the use of appropriate analgesia are recommended. Frequent application of an anaesthetic cream may also help to prevent the (rare) complication of a labial fusion after a severe first episode. Although the potential for sensitisation exists in the use of topical anaesthetic agents, lidocaine is a rare sensitizer and can be used safely in genital herpes in the form of gel or ointment.<sup>49</sup> Benzocaine, however, is a potent sensitizer and should not be used (1, D). In women with severe dysuria, urination with the genitals submerged in water or physiological saline solution along with spreading the labia can alleviate symptoms.

### Counselling

It is important to provide counselling for the patient with genital herpes covering genital herpes evolution, severity of the lesions and symptoms, recurrences and transmission of the disease. The diagnosis should be communicated in a patient-centred approach (providing patients with information and hope, in a non-dominant, supportive way).<sup>50</sup> Advice on disclosure should be practical and tailored to the patient's personal situation—disclosure to sexual partners would usually be recommended. It is important to be frank about transmission risks including subclinical shedding and the limited impact of condoms and antivirals.<sup>5</sup> The low physical morbidity and high population prevalence should be stressed. Clear information about herpes simplex impact on pregnancy is important to patients and sexual contacts. High distress at diagnosis is common, often persists with recurrences and may be reduced by antivirals (1, A).<sup>51–53</sup> Most patients require one or two sessions but adjustment is difficult to predict and careful follow-up is important with more intensive input for those who do not adjust within 3–6 months. The physician should be prepared for lengthy consultations, for stigma avoidance and improve coping.

Patients may show a fear of rejection and can develop symptoms of depression,<sup>54,55</sup> and believe they have become less sexually attractive.<sup>56</sup> Fear of disclosure may be an important contributor to withdrawal from intimate relationships,<sup>57</sup> and diminished quality of life.<sup>58</sup> Clinicians need to be aware of the poor quality of online information and the patient should only be signposted to trusted information sources or adequate printed materials.

### Management of complications

Hospitalization may be required for urinary retention, meningism, severe constitutional symptoms or adverse social circumstances. If catheterisation is required, consideration should be given as to whether a suprapubic approach offers better symptom control to the individual patient. Super infection of lesions is rare but may occur during the second week. This is characterized by the recrudescence of local symptoms. Candida is most often implicated and is easily diagnosed and treated.

Genital HSV can theoretically be associated with superinfection of atopic dermatitis, relapsing eczema herpeticum, or be associated with recurrent erythema multiformae. Occasional case reports are described and the management is identical to that for these complications when arising from oral HSV-1.

### Information for patients

The following information should be discussed when counselling patients with first-episode genital herpes.

- The course of infection, including subclinical shedding.
- Genital herpes has a high a population prevalence.
- Treatment options.
- The risk of transmission and interventions that may limit or reduce the risk of transmission.
- The risk of transmission to the infant at birth. The patient should be counselled to inform the obstetrician and midwife.
- The utility of partner notification and the possible source of infection.
- That transmissions can occur from an asymptomatic partner some years into a monogamous relationship.
- The value of disclosure to fight stigma, depression or a diminished self-worth.

### Follow-up

Patients are followed up until the episode has resolved and counselling is considered complete. Further follow-up may be required to exclude other causes of genital ulceration that may be co-existent. Patients should be invited to re-attend should recurrences be problematic.

## Recurrent genital herpes

### Indications for therapy

Genital herpes recurrences are self-limiting and generally cause minor symptoms (Figure 1). The level of distress and the disruption caused to individual's sexual and social life is often independent of the frequency of symptoms. Decisions about how best to manage clinical recurrences should be made in partnership with the patient. Management strategies include supportive therapy only, episodic antiviral treatments and suppressive antiviral therapy. The most appropriate strategy for managing an individual patient may vary over time according to recurrence frequency, symptom severity and relationship status. For most patients, management will need to be supportive only, with simple local measures such as saline bathing or topical petroleum jelly being adequate.

### Episodic antiviral treatment

Oral aciclovir, valaciclovir and famciclovir are effective at reducing the duration and severity of recurrent genital herpes. The reduction in duration is a median of 1–2 days (1, A).<sup>59–61</sup> Head-to-head studies of their effects show no advantage of one therapy over another or the advantage of extended 5-day treatment over ultra-short therapy. Prodrugs offer simplified twice-a-day dosing. Patient-initiated treatment started within 24 h is most likely to be effective. Aborted lesions have been documented in up to one-third of patients with early treatment.<sup>62</sup> To ensure prompt treatment, patients should be advised to carry a small quantity of drugs at all times and not rely on sourcing medication after a recurrence starts.

Short course therapies should be tried in the first instance:

- Aciclovir 800 mg three times daily for 2 days or<sup>63</sup>
- Famciclovir 1 g twice daily for 1 day or<sup>64</sup>
- Valaciclovir 500 mg twice daily for 3 days (1, A).<sup>63,65–68</sup>

Alternative longer 5-day courses include the following:

- Aciclovir 400 mg three times daily or
- Aciclovir 200 mg five times daily or
- Valaciclovir 500 mg twice daily or
- Famciclovir 125 mg twice daily.

### Suppressive therapy

The majority of early trials of suppressive therapy were done in patients with a recurrence rate equivalent to  $\geq 6$  recurrences/annum.<sup>69,70</sup> More recently, studies have been completed in patients with much milder disease.<sup>71,72</sup> These indicate that patients across all spectrums of disease will benefit from a reduced rate of recurrence with treatment. The frequency of recurrence at which it is worth starting

suppressive therapy is a subjective issue and needs to balance the frequency of recurrence, the impact of disease on the individual and the need to manage transmission risk against the cost and inconvenience of treatment.

All patients are highly likely to experience a substantial reduction in recurrence frequency on suppressive antiviral therapy. However, the majority of patients on such a regimen will still experience an occasional symptomatic recurrence.

Experience with suppressive antiviral therapy is most extensive with aciclovir (1, A).<sup>73</sup> Safety and resistance data on patients on long-term therapy now extends to over 18 years of continuous surveillance. There is no accumulative toxicity or organ damage in long-term use. Dose adjustments are only required in severe renal disease. Regular blood monitoring in otherwise well patients is not recommended. Although not essential, it may be prudent to regularly assess the need for continuing therapy since patient circumstances may alter significantly. However, even after prolonged periods of suppression, many patients do not find a significant alteration in disease frequency or severity upon discontinuation and reassessment.

A few patients continue to experience frequent virologically confirmed symptomatic recurrences despite full dose antiviral therapy. Outside the immunocompromised population this is very unlikely to be due to resistant HSV. Investigations hoping to find a treatable immunological cause in these patients are not useful and, other than excluding HIV, no further investigations are warranted. Therapy involving interferon to improve control cannot be recommended, as these have not been widely assessed and are only available in parts of Eastern Europe.<sup>74</sup>

### Recommended regimens

The optimal total daily dose of suppressive aciclovir therapy is 800 mg. The only published clinical dose-ranging study concluded that 200 mg four times a day was marginally superior to 400 mg twice daily ( $p < 0.02$ ) (1, B).<sup>75</sup> However, ability to adhere with a four times a day dosing regimen should determine prescribing decisions for individual patients. Twice-daily valaciclovir (250 mg twice daily) has been shown to be as effective as twice-daily aciclovir (400 mg twice daily). Once-daily aciclovir does not suppress genital herpes recurrences. There is some debate as to whether once-daily therapy is as effective as twice-daily therapy with valaciclovir. For those patients experiencing  $< 10$  recurrences per annum, a dose of 500 mg once-daily valaciclovir will be adequate; for those patients experiencing  $> 10$  recurrences per annum, 250 mg twice a day or 1 g once a day is required.<sup>76</sup>

No major clinically significant differences between suppressive therapy with valaciclovir (500 mg daily) and famciclovir (250 mg twice daily) have been documented (1, D).<sup>14</sup> In patients with an insufficient clinical response with daily suppressive treatment, therapy may need to be doubled or

its frequency increased (1, D). Routine blood monitoring (e.g. serum creatinine, complete blood count and AST) of standard dose therapy is not required.<sup>77</sup> Occasionally a mild headache or nausea may occur with valaciclovir.

The decision to continue suppressive therapy should be reviewed at least annually. Discontinuation of therapy at this time, if the patient is willing, will allow a reassessment of recurrence frequency. A small number of patients will experience a reduction in recurrence frequency compared with pre-suppression symptomatic levels. The minimum period of assessment should include two recurrences to allow a view to be taken both on the frequency and severity. It is safe and reasonable to restart treatment in patients who continue to have significant disease (1, D).<sup>78</sup>

Short courses of suppressive therapy to prevent clinical symptoms may be helpful for some patients (for holidays, exams, etc.). Clinicians need to note that full suppressive effect is usually only obtained 5 days into treatment.

Recommended doses:

- Aciclovir 400 mg twice daily (for all frequencies of disease recurrence).
- Valaciclovir 500 mg daily (if fewer than 10 recurrences per annum).
- Valaciclovir 1 g daily (if more than 10 recurrences per annum).

Second stage therapy for poorly controlled patients:

- Aciclovir 400 mg three times a day.
- Valaciclovir 500 mg twice a day.

### Viral shedding and transmission on suppressive therapy

Subclinical shedding of infectious virus occurs in most individuals with genital HSV-1 and/or HSV-2. This virus is viable and is transmissible. Viral shedding is more likely to occur in patients with genital HSV-2, in the first year after

infection or in individuals with frequent symptomatic recurrences. Aciclovir, valaciclovir and famciclovir all suppress symptomatic and asymptomatic viral shedding.

Even if it seems biologically plausible, partial suppression of viral shedding does not necessarily equate to reduced transmission. However, suppressive therapy with valaciclovir 500 mg once a day (in those with 10 or fewer recurrent episodes per year) significantly reduced transmission—by nearly 50%—in serodiscordant couples (1, A).<sup>22</sup> Twice-daily aciclovir 400 mg achieves similar levels of reduction in asymptomatic shedding to once-daily valaciclovir. Suppressive antiviral therapy may be considered in addition to the use of condoms and selective sexual abstinence when transmission concerns are present.


## SPECIAL SITUATIONS

### Management of HSV in people with immunocompromise and in those living with HIV

For those patients that have a CD4 count in the normal range and an undetectable viral load, any management of HSV disease can follow the same protocol as those who are HIV negative (Figure 2). There is epidemiological synergy between HSV and HIV infections.<sup>79,80</sup> Herpes simplex infections activate HIV replication and may facilitate onward HIV transmission to sexual partners.<sup>81–88</sup> Suppressive treatment of HSV-2 infection with valaciclovir has been shown to reduce genital HIV shedding in women (not on ARVs).<sup>89</sup> In addition, both prevalent and incident HSV-2 infections are associated with an increased risk of HIV acquisition.<sup>90,91</sup>

The natural history of genital herpes in untreated people living with HIV is significantly different from that in HIV-negative individuals. The most important risk factor for herpes reactivation is the degree of HIV associated immunosuppression.<sup>92–94</sup>

Standard systemic antiviral drugs, as used to treat genital herpes in HIV-negative patients, have been shown to

Management of initial episode HSV in people living with HIV	Management of recurrent disease in people living with HIV	
	Episodic therapy for HSV in people living with HIV	Suppressive therapy for HSV in people living with HIV
Aciclovir 400mg x5/day, 7-10 days	Standard doses of antivirals short course or 5 days	Aciclovir 400mg x2-3/day
Valaciclovir 500-1g x2/day, for 10 days		Valaciclovir 500mg x 2/day
Famciclovir 250-500mg x3/day, 10 days		<i>If disease not adequately controlled: double the dose</i>
<i>If fulminant herpetic disease:</i> Aciclovir iv 5-10mg/kg body weight every 8 hours, for 2-7 days or until clinical improvement, and followed by oral antiviral therapy to complete 10 days total treatment	<i>In people living with advanced HIV: double the dose and &gt;5days therapy</i>	 <i>If control not achieved:</i> Famciclovir 500 mg orally x2/day
<i>In patients living with advanced HIV: double the standard dose (or higher dose if needed)</i>		

**FIGURE 2** Special situations: management of genital herpes in people with immunocompromise and in those living with HIV.

successfully treat genital herpes in people living with HIV.<sup>95–100</sup> Resistance to anti-herpes drugs is more common in those with HIV co-infection and is associated with treatment failure of genital herpes.<sup>101</sup> Suppressive antiviral therapy with currently available agents has been shown in multiple studies to have no impact on HIV acquisition or transmission risk. HSV treatment used only to manage or reduce HIV transmission or acquisition risk cannot be recommended (1, A).<sup>102,103</sup>

Much of the evidence on herpes management in people living with HIV comes from studies performed before the era of combination antiretroviral therapy; prospective studies performed early in the epidemic showed that clinical lesions might be persistent and progressive in those living with HIV. Genital herpes, including chronic erosive lesions may occur as a manifestation of the immune reconstitution inflammatory syndrome (IRIS) following antiretroviral therapy.<sup>104–108</sup> Patients with a low CD4 count typically have a higher susceptibility to HSV-2 shedding, with a high risk of lesion manifestation within the first 6 months after ART initiation, particularly in the first 2 months. High levels of HSV viral shedding are associated with a high HIV load before ART commences.<sup>109,110</sup> HSV associated IRIS may be unresponsive to previously effective anti-herpes viral therapy in the absence of increased antiviral resistance. Management is difficult but the judicious use of prednisolone as in other situations with IRIS may be useful.

### Management of initial episode HSV in people living with HIV

There is no trial data for any antiviral in initial episode genital HSV in people living with HIV. The vast majority of adults living with HIV have serological evidence of established HSV-1 and -2 infections making acquisition trials extremely difficult to perform.

Case studies report that acquisition of genital HSV may be associated with a prolonged and uncertain clinical course. Systemic symptoms may predominate, and chronic lesions may become established if immunological clearance of the skin does not occur. In the absence of HIV therapy, primary genital herpes may be severe and prolonged with risk of progressive, multifocal, and coalescing mucocutaneous anogenital lesions. Moreover, serious complications such as meningitis, and potentially life-threatening systemic complications such as fulminant hepatitis, pneumonia, neurological disease and disseminated infection, have been reported.

In the absence of data, most authorities advise that multiples of the standard levels of treatment for first-episode HSV be used in the immunocompromised. Some clinicians advocate a 10-day course of treatment at twice the standard dose of any of the usual agents (1, D).<sup>111</sup>

However, for those living with HIV these may not always be required particularly for those with normal CD4 counts.

In patients living with advanced HIV, double the standard dose of antiviral should be considered and if new lesions continue to form at Days 3–5, a higher dose should be considered. Prompt initiation of therapy is recommended. If new lesions

are still forming after 3–5 days, a repeat viral isolation should be attempted, and susceptibility testing arranged (if possible). The dose of HSV therapy should also be increased.

Recommended initial doses in all people living with HIV<sup>45,78</sup>:

- Aciclovir 400 mg five times daily, for 7–10 days (1, D)
- Valaciclovir 500 mg–1 g twice daily, for 10 days (1, D)
- Famciclovir 250–500 mg three times daily, for 10 days (1, D)

Treatment should be given for at least 10 days or until all lesions have re-epithelialized—this will often exceed the usual 10-day duration of treatment that is given to HIV-negative patients.

If fulminant disease ensues, then intravenous aciclovir be substituted at 5–10 mg/kg body weight every 8 h, for 2–7 days or until clinical improvement and followed by oral antiviral therapy to complete a minimum of 10 days total treatment (1, D).<sup>45</sup>

### Management of recurrent disease in people living with HIV

Both clinical and subclinical reactivations of genital herpes are more frequent in people living with HIV and may lead to persistent and progressive anogenital mucocutaneous lesions, especially with CD4 cell counts <50 per mm<sup>3</sup>. Features can be atypical in nature and larger, deeper and hypertrophic lesions can occur. Optimizing the control of HIV replication with antiretroviral therapy is of fundamental importance for the management of recurrent genital herpes. Antiretroviral therapy will reduce the frequency of clinical recurrences but has less effect upon asymptomatic viral shedding. Thereafter, specific antiviral drugs can be used for either episodic or suppressive treatment. A number of trials of antiviral therapy in the immunocompromised have been reported.<sup>112,113</sup>

### Episodic therapy for HSV in people living with HIV

It is likely that 5 days of therapy will be adequate for most patients. It should be noted that with advanced HIV 13%–17% of patients have been reported to have new lesions developing at the end of a 7-day course of treatment. Shorter courses of therapy may be adequate in those with good CD4 counts (>500 cell/mm<sup>3</sup>); although only one trial with famciclovir has reported this effect (1, A).<sup>64</sup>

Standard doses of antivirals should suffice in those with no evidence of immune failure (1, A). In those living with advanced HIV, it may be necessary to double the standard doses and to continue therapy beyond 5 days (1, A).<sup>45,78</sup> Caution should be exercised in using ultra-short courses of episodic therapy as these have not been evaluated fully in the immunocompromised.



## Suppressive therapy for HSV in people living with HIV

Suppressive antiviral therapy for HSV appears to be less effective in people living with HIV than in HIV-negative people but remains well tolerated. All three agents have been trialled. Standard suppressive doses of aciclovir are effective. Valaciclovir is more effective when given twice daily (500 mg bid) compared to once-daily dosing (1000 mg). The valaciclovir 500 mg once-daily dose has not been evaluated in those living with HIV. Trial data for the efficacy of high-dose famciclovir is only available over much shorter durations.

It is recommended that intermittent cessation of suppressive antiviral therapy for genital herpes should occur, especially in those in whom there is also adequate inhibition of HIV replication and rising CD4 cell counts. In some people living with HIV with less frequent outbreaks of genital herpes, episodic treatment may be substituted. In others, where the pre-treatment pattern of recurrences resumes, suppressive treatment may need to restart (1, D).<sup>45,78</sup>

There is a considerable body of data on the safety of oral antivirals in those living with HIV who are immunocompromised. Two studies in the pre-HAART era looked at high-dose aciclovir (400 mg four times a day) and more recently at standard dose regimens. For valaciclovir, a number of studies looked at the value of valaciclovir for the suppression of recurrent genital herpes. High-dose valaciclovir (2 g four times a day) has been studied and reported in people living with HIV and those immunosuppressed and recovering from bone marrow transplants. Most recently a large number of studies looking at the efficacy of aciclovir and valaciclovir suppression and its impact on HIV transmission from co-infected patients have been reported. These trials indicate that use of oral aciclovir at standard dose and valaciclovir at 1 g once daily and 500 mg twice a day is associated with little or no adverse effect or toxicity as compared with HIV-negative people. High-dose valaciclovir (8 g daily) has been associated with microangiopathic haemolytic uraemic syndrome.

Recommended drug regimens for daily HSV suppressive treatment in people living with HIV<sup>45,114–116</sup>:

- Aciclovir 400 mg orally twice to three times a day;
- Valaciclovir 500 mg orally twice a day.

If these options do not adequately control disease, then the first option should be to double the dose. If control is still not achieved then famciclovir 500 mg orally twice a day can be tried (1, B).

## HSV suppression to limit HIV progression

Suppressive antiviral therapy with aciclovir or valaciclovir has been shown to decrease the levels of HIV viraemia in those patients with detectable HIV viral loads through a mechanism not yet fully elucidated.<sup>117</sup> Such a strategy will impact on HIV progression, particularly for those individuals

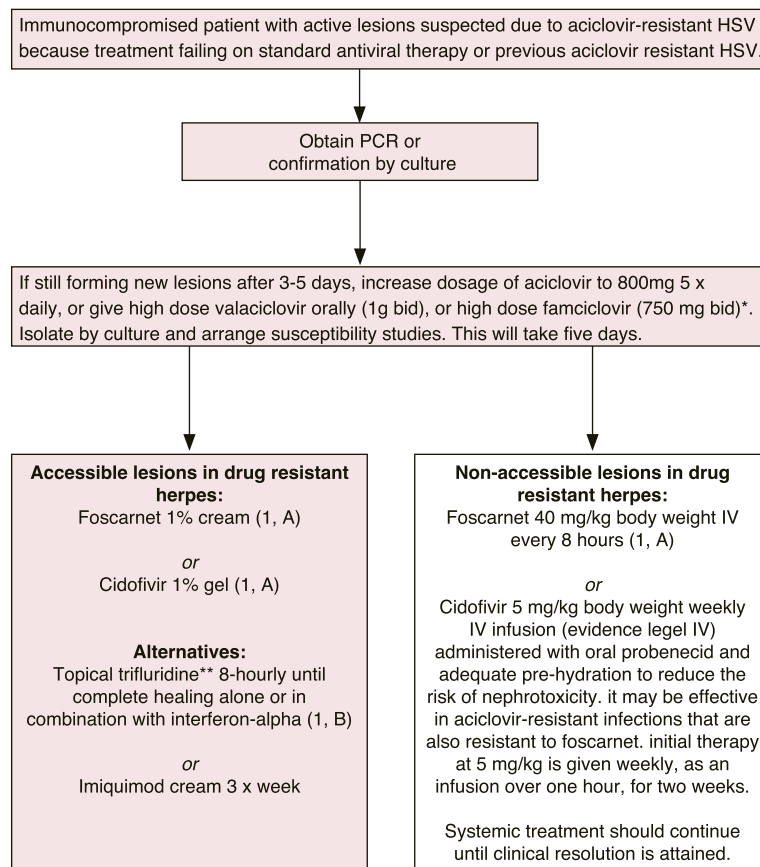
not on antiretroviral therapy. A large RCT in people with early HIV (those individuals not on antiretroviral therapy and with CD4 counts above 250 cells/mm<sup>3</sup>) has shown that standard doses of suppressive antiviral therapy (aciclovir 400 mg twice a day) will sustain CD4 counts above 250 cell/mm<sup>3</sup> and this effect reduced the need for antiretroviral at 2 years by 16% in the treatment group. However, benefits of suppressive antivirals have not been demonstrated in the presence of effective antiretroviral therapy.<sup>103,104</sup> Effective antiretroviral therapy remains the priority for people living with HIV for their own health outcomes and to prevent transmission and therefore HSV antiviral suppression to control HIV is unlikely to be clinically relevant.

## Management of recalcitrant herpes in immunocompromised individuals

Although rare in immunocompetent individuals, clinically refractory lesions due to genital HSV are a major problem in patients with severe immunodeficiency, including late-stage HIV. Algorithms for treatment in such situations are shown in Figure 3. Systemic therapy with either foscarnet or cidofovir is generally preferred to treat drug-resistant herpes in those living with HIV.<sup>118</sup> There is evidence for alternating courses of treatment with aciclovir and cidofovir for subsequent recurrences as a strategy that may reduce the development of cidofovir-resistant strains. The efficacy, safety and durability of the therapeutic response of these agents have yet to be determined in prospective controlled trials.

In prospective studies, aciclovir-resistant strains have been found in around 5%–7% isolates from genital herpes lesions in people living with HIV.<sup>48,119,120</sup> Aciclovir resistance is confirmed if isolates require aciclovir concentrations >1–3 mg/L for inhibition. Aciclovir resistance is most commonly related to a mutation in the gene encoding HSV thymidine kinase (TK), which is responsible for initial phosphorylation of aciclovir to its active form, resulting in TK that either has reduced affinity for aciclovir or is not synthesized. TK-deficient strains are of reduced pathogenicity in immunocompetent individuals but may cause serious local and systemic disease in severely immunocompromised individuals.<sup>121,122</sup> They appear less likely to be associated with the development of latency; hence, subsequent clinical reactivations of genital herpes are often caused by aciclovir sensitive isolates. Partially resistant strains may sometimes be successfully treated with high-dose intravenous aciclovir and other nucleoside analogues but fully aciclovir-resistant strains are resistant to valaciclovir and ganciclovir, and the majority are resistant to famciclovir.<sup>121–123</sup> TK-deficient strains are susceptible to foscarnet and cidofovir which do not depend upon TK but which inhibit viral DNA polymerase.

Hypertrophic herpes simplex is an unusual condition often presenting with painful and exophytic tumoral nodules with or without an ulcerated surface located predominantly in the anogenital region. It is often refractory to first-line systemic antiviral agents such as aciclovir (administered orally or intravenously), valaciclovir and



**FIGURE 3** Algorithm for the treatment of herpes in immunocompromised individuals.

famciclovir; a higher frequency of drug-resistant HSV strains has been described. Immunomodulators, such as topical imiquimod, or thalidomide, can be useful in treating this condition.<sup>124-126</sup>

Reports of outcomes in the open access pritelivir programme for immunocompromised people living with refractory lesions has shown great promise for this novel helicase primase inhibitor.<sup>127</sup> Amenamevir (a helicase-primase inhibitor, currently licensed for the treatment of herpes zoster) has also been used for this indication.<sup>128</sup>

Antiviral susceptibility testing for HSV has limited availability and therefore the clinical response to antiviral therapy is often used to guide decisions. Advice from a clinical virologist about appropriate drug dosages and duration may be sought when clinical resistance is suspected.

## Management of pregnant women with genital herpes

### Management of pregnant women with first-episode genital herpes

#### *First- and second-trimester acquisitions*

Management of the woman should be in line with her clinical condition and will often involve the use of either oral or intravenous aciclovir in standard doses (Figure 4).

Providing that delivery does not ensue, the pregnancy should be managed expectantly, and vaginal delivery anticipated (1, D).

Daily suppressive aciclovir 400 mg three times a day from 36 weeks gestation may prevent HSV lesions at term and hence the need for delivery by caesarean section (1, A).<sup>129-134</sup> In countries where the risk transmission in premature neonates is particularly high, suppressive therapy should be started at an earlier time such as from 32 weeks gestation and from 22 weeks in those identified as being at particularly high risk of premature delivery.

#### *Third trimester acquisition (1, D)*

Late pregnancy acquisitions are associated with high risks of transmission and morbidity in the neonate. Caesarean section should be considered for all women, particularly those developing symptoms within 6 weeks of delivery, as the risk of viral shedding in labour is very high (1, A).

Daily suppressive aciclovir 400 mg three times a day to delivery should be considered to be continued to term.

If vaginal delivery is unavoidable, prolonged rupture of membranes and invasive procedures, including the use of scalp electrodes, should be avoided. Intrapartum IV aciclovir given to the mother and subsequently to the baby may be considered and the paediatrician should be informed.<sup>135</sup>

Management of pregnant women with first episode genital herpes		Management of pregnant women with recurrent genital herpes	
First and second trimester acquisition	Third trimester acquisition	Management of recurrent HSV in early pregnancy	Management of recurrent HSV in late pregnancy
Standard doses in line with the clinical condition of the pregnant woman	<i>Suppressive</i> Aciclovir 400mg x 3 /day to delivery	<i>Continuous or episodic therapy</i> is not licensed for use in early pregnancy but has not been associated with adverse effects; a decision on its use should be made on a case-by-case basis.	<i>Suppressive</i> Aciclovir 400mg x 3/ day from 36 weeks gestation (earlier if there is any risk of prematurity) in all women with a history of genital herpes
<i>Suppressive:</i> Aciclovir 400mg x 3/day daily from 36 weeks gestation (earlier if risk of premature delivery) to prevent HSV lesions at term (and the need for Caesarean section)	Caesarean section		
			<i>If pregnant women living with HIV with recurrent HSV infection:</i> Aciclovir 400mg x 3/day from 36 weeks gestation (earlier if there is any risk of prematurity)
			<i>If genital lesions at onset of labour:</i> Caesarean section may be considered

**FIGURE 4** Special situations: management of genital herpes in pregnant women.

## Management of pregnant women with recurrent genital herpes (1, C)

Women with recurrent genital herpes should be informed that the risk of neonatal herpes is low.

### *Management of recurrent HSV in early pregnancy*

Continuous or episodic therapy is not licensed for use in early pregnancy but has not been associated with adverse effects in a large pregnancy registry. A decision on its use should be made on a case-by-case basis. Famciclovir should not be used and the dose of aciclovir titrated down to the minimum effective level.

### *Management of recurrent HSV in late pregnancy*

Symptomatic recurrences of genital herpes during the third trimester will be brief; vaginal delivery is appropriate if no lesions are present at delivery.

For women with a history of recurrent genital herpes, the use of antiviral suppression has been demonstrated to reduce asymptomatic HSV shedding and lesions at term, and may also reduce premature delivery, but have not been studied sufficiently to definitively demonstrate prevention of neonatal HSV disease.<sup>130-139</sup> Daily suppressive aciclovir 400 mg three times a day from 36 weeks gestation should therefore be offered to all women with a history of genital herpes (1, A).<sup>140</sup> This may be started earlier if there is any risk of prematurity such as from 32 weeks gestation and from 22 weeks in those identified as being at particularly high risk of premature delivery; and should be guided by national neonatal HSV epidemiology.

If there are no genital lesions at delivery, there is no indication for a caesarean section to prevent neonatal herpes.

Sequential PCR during late gestation to predict viral shedding at term is not indicated.<sup>141</sup>

The utility of taking PCR at delivery, in order to identify women who are asymptotically shedding HSV, is unproven.

## Management of pregnant women living with HIV with recurrent HSV infection (1, D)

There is some evidence that women living with HIV with genital HSV ulceration in pregnancy are more likely to transmit HIV infection independent of other factors.<sup>28,30</sup> However, this is not a consistent finding across all studies.<sup>30</sup>

Women who are HIV antibody positive and have a history of genital herpes should be offered daily suppressive aciclovir 400 mg three times a day from 32 weeks gestation to reduce the risk of transmission of HIV-1 infection especially in women where a vaginal delivery is planned. Starting therapy at an earlier gestation than usual should be considered in view of the increased possibility of preterm labour and consideration may be given to starting at 22 weeks of gestation in those at particularly high risk of premature delivery (1, D).

There is currently insufficient evidence to recommend daily suppressive treatment for HIV-1 antibody-positive women who are HSV-1 or -2 seropositive but have no history of genital herpes.<sup>139,142</sup>

## Management of women with genital lesions at onset of labour

Caesarean section may be considered for women with recurrent genital herpes lesions at the onset of labour but the risk of neonatal herpes following vaginal delivery is small and must be set against risks to the mother of caesarean section. Evidence from the Netherlands shows that a conservative approach, allowing vaginal delivery in the presence of a recurrent anogenital lesion, was not initially associated with a rise in numbers of neonatal HSV cases (1, C).<sup>143,144</sup> However, this approach can only be adopted if fully supported by obstetricians and neonatologists, and if consistent with the local medico-legal advice.

Clinical diagnosis of genital herpes at the time of labour correlates relatively poorly with HSV detection from genital

sites by PCR and fails to identify women with asymptomatic HSV shedding.

Note: None of the antiviral drugs is licensed for use in pregnancy but the use of aciclovir in pregnancy has not been associated with any consistent pregnancy or foetal/neonatal adverse effects other than transient neutropenia.<sup>143–145</sup> Safety data for aciclovir may be extrapolated to valaciclovir in late pregnancy, as it is the valine ester, but there is less experience with use of valaciclovir.<sup>137</sup> Famciclovir should currently be avoided.<sup>146,147</sup>

## Prevention of acquisition of infection (1, D)

Maternal risk of HSV acquisition in pregnancy varies geographically and local epidemiological surveillance should guide strategy for prevention (Table 2). Any strategy for prevention of neonatal herpes needs to involve both parents.

All women should be asked at their first antenatal visit if they or their partner have had genital or oral herpes.

Female partners of men with genital herpes, but without a personal history of genital herpes should be advised about reducing their risk of acquiring herpes in pregnancy and of subsequent transmission to their baby. Strategies include selective and complete abstinence (especially in the third trimester) and conscientious condom use.

Daily suppressive treatment has been shown to significantly reduce the risk of transmission of HSV to a seronegative partner; however, the effectiveness of suppressive treatment of the male partner to reduce transmission to a pregnant woman has not been evaluated so can currently only be recommended with caveats.

Pregnant women should be advised of the risk of acquiring HSV-1 as a result of receptive orogenital contact especially in the last trimester of pregnancy.

Identifying susceptible women by means of type-specific antibody testing has not been shown to be cost effective and is not indicated in Europe unless the history suggests they may be in a discordant relationship.

All women, not just those with a history of genital herpes, should undergo careful vulval inspection at the onset of labour to look for clinical signs of herpes infection.

Mothers, staff and other relatives/friends with active oral HSV lesions or herpetic whitlow should be advised to avoid direct contact between lesions and the neonate.

**TABLE 2** Strategies to prevent neonatal herpes in the sero-discordant couple.

1	Complete abstinence from 26/40 of the pregnancy
2	Use of condoms for all sex acts irrespective of the absence of symptoms
3	Avoid sex when any symptoms or signs suggestive of genital herpes are present
4	Anti-viral medication for suppression of HSV in the affected non pregnant partner

## Management of the neonate

*Babies born to mothers with first-episode genital herpes at the onset of labour*

The paediatrician should be informed.

HSV PCR from the oropharynx, nose, conjunctiva, rectum and any visible lesions, should be taken to allow early identification of infected babies. HSV PCR should be performed on a blood sample (it may take over 24 h for sufficient HSV replication to occur for a positive result to occur and so a negative test does not exclude infection, may need to be repeated) and a lumbar puncture for CSF should be considered.

The potential benefits and risks of starting intravenous aciclovir without waiting for the results of these tests should be discussed.

If aciclovir is not started immediately the neonate should be closely monitored for signs of lethargy, fever, poor feeding or lesions.

*Babies born to mothers with recurrent genital herpes at the onset of labour*

Although some clinicians feel that taking a set of specimens for viral PCR collected 24–48 h after delivery may help with early identification of infection there is no evidence to support this practice. However, healthcare workers and parents should be advised to consider HSV in the differential diagnosis if the baby shows any signs of infection or develops skin, eye or mucous membrane lesions, particularly in the first 2 weeks of life or features of sepsis in the neonatal period.

## Management of partners

There is no evidence on which to base recommendations for partner notification. On an individual basis, it may be appropriate to offer to see partners to help with the counselling process. Partner notification in relation to pregnancy is discussed below. It is worth considering the following points when counselling partners:

- The use of condoms is advisable especially when transmission concerns are present—even when the index case is on suppressive antiviral treatment.<sup>22</sup>
- Asymptomatic shedding plays a major role in the transmission of HSV infection and selective abstinence (abstinence during the presence of symptoms or signs) is therefore not an effective strategy for managing transmission risk.
- Partner notification is an effective way of detecting uninfected or asymptomatic individuals especially when combined with type-specific antibody testing.
- Up to 50% of asymptomatic HSV-2 seropositive women can be taught to recognize some of their genital herpes recurrences after counselling.<sup>148</sup>
- Virus transmission can be reduced either with suppressive antiviral treatment or by using condoms.

## Aciclovir intolerance

Aciclovir intolerance is rare but is described. Minor allergic reactions to aciclovir or the excipients within tablets are difficult to distinguish but changing between the many generic brands often manages the problem. Urticarial reactions should be investigated and managed as per well-established, dermatological protocols. Neurotoxic reactions are rare and changing between aciclovir and valaciclovir will not be helpful.

Proposed date for review: 2029.

## ACKNOWLEDGEMENTS

The authors wish to acknowledge the following individuals for their helpful comments: Mr. Morgan Blake, Dr. Gemma-Martin Ezquerro, Dr. Derek Freedman, Professor Jonathan Ross, Dr. Michael Waugh and Dr. Henry JC de Vries. Composition of Editorial Board: Please refer to document at [http://www.iusti.org/regions/Europe/pdf/2014/Editorial\\_Board2014.pdf](http://www.iusti.org/regions/Europe/pdf/2014/Editorial_Board2014.pdf). List of Contributing Organizations: Please refer to text at <https://iusti.org/treatment-guidelines/>.

## FUNDING INFORMATION

No funding was utilized for the preparation of the manuscript (design, data collection, analysis etc).

## CONFLICT OF INTEREST STATEMENT

Rajul Patel received grants from GSK; received consulting fees from Rational Vaccine, Hiedelberg University, GSK and Innovative Molecules; received honoraria from Abbott Diagnostics. Benjamin Moran, Stephan Lautenschlager, John Green, Gilbert Donders, Mikhail Gomberg and Shyam Samraj have no conflict of interest to declare. Emily Clarke received grants from GSK. Anna Maria Geretti received grants from Gilead, Roche and ViiV; received consulting fees from Abbott, GSK, MSD and ViiV; received honoraria from GSK, Gilead, Roche and ViiV. George Sorin Tiplica received honoraria from Abbott, Organon, Genesis Biopharma Romania SRL, Leo Pharma Romania, Antibiotice SA and BMS. Elizabeth Foley received consulting fee from GSK.

## DATA AVAILABILITY STATEMENT


The data that support the findings of this study are available from the corresponding author upon reasonable request.


## ETHICS STATEMENT

The patients in this manuscript have given written informed consent to publication of their case details. No other ethical approval was required for this study.

## ORCID

Rajul Patel  <https://orcid.org/0000-0002-9947-7145>

Mikhail Gomberg  <https://orcid.org/0000-0002-1070-5229>

George Sorin Tiplica  <https://orcid.org/0000-0002-8719-6952>

## REFERENCES

- Gupta R, Warren T, Wald A. Genital herpes. *Lancet*. 2007;370(9605):2127–37. [https://doi.org/10.1016/s0140-6736\(07\)61908-4](https://doi.org/10.1016/s0140-6736(07)61908-4)
- Ashley RL, Wald A. Genital herpes: review of the epidemic and potential use of type-specific serology. *Clin Microbiol Rev*. 1999;12(1):1–8.
- Wald A, Zeh J, Selke S, Ashley RL, Corey L. Virologic characteristics of subclinical and symptomatic genital herpes infections. *N Engl J Med*. 1995;333(12):770–5.
- Casper C, Wald A. Condom use and the prevention of genital herpes acquisition. *Herpes*. 2002;9(1):10–4.
- Wald A, Langenberg AG, Krantz E, Douglas JM Jr, Handsfield HH, DiCarlo RP, et al. The relationship between condom use and herpes simplex virus acquisition. *Ann Intern Med*. 2005;143(10):707–13.
- Wald A, Langenberg AG, Link K, Izu AE, Ashley R, Warren T, et al. Effect of condoms on reducing the transmission of herpes simplex virus type 2 from men to women. *JAMA*. 2001;285(24):3100–6.
- Garland SM, Steben M. Genital herpes. *Best Pract Res Clin Obstet Gynaecol*. 2014;28(7):1098–110.
- Magdalenó-Tapiá J, Hernández-Bel P, Ortiz-Salvador JM, López-Martí C, Martínez-Doménech Á, García-Legaz-Martínez M, et al. Genital herpes zoster: a rare location that can mimic genital herpes. *Sex Transm Dis*. 2022;49(1):e34–e36.
- Singhrai T, Higham E, French P. Lymphogranuloma venereum presenting as perianal ulceration: an emerging clinical presentation? *Sex Transm Infect*. 2011;87(2):123–4. <https://doi.org/10.1136/sti.2010.047019>
- Koutsky LA, Stevens CE, Holmes KK, Ashley RL, Kiviat NB, Critchlow CW, et al. Underdiagnosis of genital herpes by current clinical and viral-isolation procedures. *N Engl J Med*. 1992;326(23):1533–9.
- Wald A, Huang ML, Carrell D, Selke S, Corey L. Polymerase chain reaction for detection of herpes simplex virus (HSV) DNA on mucosal surfaces: comparison with HSV isolation in cell culture. *J Infect Dis*. 2003;188(9):1345–51. <https://doi.org/10.1086/379043>
- Ramaswamy M, McDonald C, Smith M, Thomas D, Maxwell S, Tenant-Flowers M, et al. Diagnosis of genital herpes by real time PCR in routine clinical practice. *Sex Transm Infect*. 2004;80(5):406–10.
- van Doornum GJ, Guldemeester J, Osterhaus AD, Niesters HG. Diagnosing herpesvirus infections by real-time amplification and rapid culture. *J Clin Microbiol*. 2003;41(2):576–80.
- Geretti AM. Genital herpes. *Sex Transm Infect*. 2006;82(Suppl 4):iv31–iv34. <https://doi.org/10.1136/sti.2006.023200>
- Verano L, Michalski FJ. Herpes simplex virus antigen direct detection in standard virus transport medium by Du Pont Herpcheck enzyme-linked immunosorbent assay. *J Clin Microbiol*. 1990;28(11):2555–8.
- Slomka MJ, Emery L, Munday PE, Moulds M, Brown DW. A comparison of PCR with virus isolation and direct antigen detection for diagnosis and typing of genital herpes. *J Med Virol*. 1998;55(2):177–83.
- Cone RW, Swenson PD, Hobson AC, Remington M, Corey L. Herpes simplex virus detection from genital lesions: a comparative study using antigen detection (HerpCheck) and culture. *J Clin Microbiol*. 1993;31(7):1774–6.
- Kimberley WC. Sampson and Samantha Mulcahy: prevention of future deaths report. *Judiciary CaT*. 2023. 17/09/2023. Available at: <https://www.judiciary.uk/prevention-of-future-death-reports/kimberley-sampson-and-samantha-mulcahy-prevention-of-future-deaths-report/> (last accessed 01 January 2024).
- Munday PE, Vuddamalay J, Slomka MJ, Brown DW. Role of type specific herpes simplex virus serology in the diagnosis and management of genital herpes. *Sex Transm Infect*. 1998;74(3):175–8.
- Malkin JE. Herpes simplex virus: who should be tested? *Herpes*. 2002;9(2):31.
- Copas AJ, Cowan FM, Cunningham AL, Mindel A. An evidence based approach to testing for antibody to herpes simplex virus type 2. *Sex Transm Infect*. 2002;78(6):430–4.

22. Corey L, Wald A, Patel R, Sacks SL, Tyring SK, Warren T, et al. Once-daily valacyclovir to reduce the risk of transmission of genital herpes. *N Engl J Med*. 2004;350(1):11–20.
23. Ramaswamy M, McDonald C, Sabin C, Tenant-Flowers M, Smith M, Geretti AM. The epidemiology of genital infection with herpes simplex virus types 1 and 2 in genitourinary medicine attendees in inner London. *Sex Transm Infect*. 2005;81(4):306–8. <https://doi.org/10.1136/sti.2004.011643>
24. Falk-Hanson E, Marconi A, Sarrouf EB, Sullivan P. Herpes simplex type one as the predominant cause of genital herpes in college students. *Sex Transm Dis*. 2024;51:784–7.
25. Brown ZA, Selke S, Zeh J, Kopelman J, Maslow A, Ashley RL, et al. The acquisition of herpes simplex virus during pregnancy. *N Engl J Med*. 1997;337(8):509–16.
26. Rouse DJ, Stringer JS. An appraisal of screening for maternal type-specific herpes simplex virus antibodies to prevent neonatal herpes. *Am J Obstet Gynecol*. 2000;183(2):400–6. <https://doi.org/10.1067/mob.2000.105967>
27. Tita AT, Grobman WA, Rouse DJ. Antenatal herpes serologic screening: an appraisal of the evidence. *Obstet Gynecol*. 2006;108(5):1247–53. <https://doi.org/10.1097/01.AOG.0000236433.29679.9a>
28. Drake AL, John-Stewart GC, Wald A, Mbori-Ngacha DA, Bosire R, Wamalwa DC, et al. Herpes simplex virus type 2 and risk of intrapartum human immunodeficiency virus transmission. *Obstet Gynecol*. 2007;109(2 Part 1):403–9.
29. Bollen LJ, Whitehead SJ, Mock PA, Leelawiwat W, Asavapiriyant S, Chalermchokchareonkit A, et al. Maternal herpes simplex virus type 2 coinfection increases the risk of perinatal HIV transmission: possibility to further decrease transmission? *AIDS*. 2008;22(10):1169–76.
30. Chen KT, Tuomala RE, Chu C, Huang ML, Watts DH, Zorrilla CD, et al. No association between antepartum serologic and genital tract evidence of herpes simplex virus-2 coinfection and perinatal HIV-1 transmission. *Am J Obstet Gynecol*. 2008;198(4):399.e1.
31. Ashley RL. Performance and use of HSV type-specific serology test kits. *Herpes*. 2002;9(2):38–45.
32. Ashley R, Benedetti J, Corey L. Humoral immune response to HSV-1 and HSV-2 viral proteins in patients with primary genital herpes. *J Med Virol*. 1985;17(2):153–66.
33. Ashley R. Type-specific antibodies to HSV-1 and -2: review of methodology. *Herpes*. 1998;5:33–8.
34. Smith JS, Bailey RC, Westreich DJ, Maclean I, Agot K, Ndinya-Achola JO, et al. Herpes simplex virus type 2 antibody detection performance in Kisumu, Kenya, using the Herpesselect ELISA, Kalon ELISA, Western blot and inhibition testing. *Sex Transm Infect*. 2009;85(2):92–6.
35. Gopal R, Gibbs T, Slomka MJ, Whitworth J, Carpenter LM, Vyse A, et al. A monoclonal blocking EIA for herpes simplex virus type 2 antibody: validation for seroepidemiological studies in Africa. *J Virol Methods*. 2000;87(1–2):71–80.
36. Morrow RA, Friedrich D, Krantz E. Performance of the focus and Kalon enzyme-linked immunosorbent assays for antibodies to herpes simplex virus type 2 glycoprotein G in culture-documented cases of genital herpes. *J Clin Microbiol*. 2003;41(11):5212–4.
37. Van Dyck E, Buvé A, Weiss HA, Glynn JR, Brown DW, De Deken B, et al. Performance of commercially available enzyme immunoassays for detection of antibodies against herpes simplex virus type 2 in African populations. *J Clin Microbiol*. 2004;42(7):2961–5.
38. Golden MR, Ashley-Morrow R, Swenson P, Hogrefe WR, Handsfield HH, Wald A. Herpes simplex virus type 2 (HSV-2) Western blot confirmatory testing among men testing positive for HSV-2 using the focus enzyme-linked immunosorbent assay in a sexually transmitted disease clinic. *Sex Transm Dis*. 2005;32(12):771–7.
39. Morrow RA, Friedrich D, Meier A, Corey L. Use of “biokit HSV-2 rapid assay” to improve the positive predictive value of focus HerpeSelect HSV-2 ELISA. *BMC Infect Dis*. 2005;5:84. <https://doi.org/10.1186/1471-2334-5-84>
40. Ashley Morrow R, Krantz E, Friedrich D, Wald A. Clinical correlates of index values in the focus HerpeSelect ELISA for antibodies to herpes simplex virus type 2 (HSV-2). *J Clin Virol*. 2006;36(2):141–5. <https://doi.org/10.1016/j.jcv.2006.02.006>
41. Nascimento MC, Ferreira S, Sabino E, Hamilton I, Parry J, Pannuti CS, et al. Performance of the HerpeSelect (focus) and Kalon enzyme-linked immunosorbent assays for detection of antibodies against herpes simplex virus type 2 by use of monoclonal antibody-blocking enzyme immunoassay and clinicovirological reference standards in Brazil. *J Clin Microbiol*. 2007;45(7):2309–11.
42. LeGoff J, Mayaud P, Gresenguet G, Weiss HA, Nzambi K, Frost E, et al. Performance of HerpeSelect and Kalon assays in detection of antibodies to herpes simplex virus type 2. *J Clin Microbiol*. 2008;46(6):1914–8.
43. Gamiel JL, Tobian AA, Laeyendecker OB, Reynolds SJ, Morrow RA, Serwadda D, et al. Improved performance of enzyme-linked immunosorbent assays and the effect of human immunodeficiency virus coinfection on the serologic detection of herpes simplex virus type 2 in Rakai, Uganda. *Clin Vaccine Immunol*. 2008;15(5):888–90.
44. van Rooijen MS, Roest W, Hansen G, Kwa D, de Vries HJ. False-negative type-specific glycoprotein G antibody responses in STI clinic patients with recurrent HSV-1 or HSV-2 DNA positive genital herpes, The Netherlands. *Sex Transm Infect*. 2016;92(4):257–60. <https://doi.org/10.1136/sextrans-2015-052213>
45. Workowski KA, Bachmann LH, Chan PA, Johnston CM, Muzny CA, Park I, et al. Sexually transmitted infections treatment guidelines, 2021. *MMWR Recomm Rep*. 2021;70(4):1–187. <https://doi.org/10.15585/mmwr.r7004a1>
46. Fife KH, Barbarash RA, Rudolph T, Degregorio B, Roth R. Valaciclovir versus acyclovir in the treatment of first-episode genital herpes infection. Results of an international, multicenter, double-blind, randomized clinical trial. The valaciclovir international herpes simplex virus study group. *Sex Transm Dis*. 1997;24(8):481–6.
47. Corey L, Benedetti J, Critchlow C, Mertz G, Douglas J, Fife K, et al. Treatment of primary first-episode genital herpes simplex virus infections with acyclovir: results of topical, intravenous and oral therapy. *J Antimicrob Chemother*. 1983;12(suppl\_B):79–88.
48. Reyes M, Shaik NS, Graber JM, Nisenbaum R, Wetherall NT, Fukuda K, et al. Acyclovir-resistant genital herpes among persons attending sexually transmitted disease and human immunodeficiency virus clinics. *Arch Intern Med*. 2003;163(1):76–80.
49. Weightman W, Turner T. Allergic contact dermatitis from lignocaine: report of 29 cases and review of the literature. *Contact Dermatitis*. 1998;39(5):265–6.
50. Barnack-Tavlaris JL, Reddy DM, Ports K. Psychological adjustment among women living with genital herpes. *J Health Psychol*. 2011;16(1):12–21.
51. Carney O, Ross E, Bunker C, Ikkos G, Mindel A. A prospective study of the psychological impact on patients with a first episode of genital herpes. *Genitourin Med*. 1994;70(1):40–5.
52. Patel R, Tyring S, Strand A, Price MJ, Grant DM. Impact of suppressive antiviral therapy on the health related quality of life of patients with recurrent genital herpes infection. *Sex Transm Infect*. 1999;75(6):398–402.
53. Green J, Kocsis A. Psychological factors in recurrent genital herpes. *Genitourin Med*. 1997;73(4):253–8.
54. Green J, Ferrier S, Kocsis A, Shadrick J, Ukoumunne OC, Murphy S, et al. Determinants of disclosure of genital herpes to partners. *Sex Transm Infect*. 2003;79:42–4.
55. Patel R, Boselli F, Cairo I, Barnett G, Price M, Wulf HC. Patients' perspectives on the burden of recurrent genital herpes. *Int J STD AIDS*. 2001;12:640–5.
56. Newton DC, McCabe MP. The impact of stigma on couples managing a sexually transmitted infection. *Sex Relatsh Ther*. 2005;20:51–63.
57. Radecki BC. The theoretical basis of stigma as applied to genital herpes. *Herpes*. 2004;11:4–7.
58. Doward LC, McKenna SP, Kohlmann T, Niero M, Patrick D, Spencer B, et al. The international development of the RGHQoL: a quality of life measure for recurrent genital herpes. *Qual Life Res*. 1998;7:143–53.

59. Nilsen A, Aasen T, Halsos A, Kinge BR, Tjøtta EL, Wikström K, et al. Efficacy of oral acyclovir in the treatment of initial and recurrent genital herpes. *Lancet*. 1982;320(8298):571–3.
60. Spruance SL, Tyring SK, DeGregorio B, Miller C, Beutner K. A large-scale, placebo-controlled, dose-ranging trial of peroral valaciclovir for episodic treatment of recurrent herpes genitalis. Valaciclovir HSV Study Group. *Arch Intern Med*. 1996;156(15):1729–35.
61. Sacks SL, Aoki FY, Diaz-Mitoma F, Sellors J, Shafran SD. Patient-initiated, twice-daily oral famciclovir for early recurrent genital herpes. A randomized, double-blind multicenter trial. Canadian famciclovir study group. *JAMA*. 1996;276(1):44–9.
62. Spruance SL, Overall JC Jr, Kern ER, Krueger GG, Pliam V, Miller W. The natural history of recurrent herpes simplex labialis: implications for antiviral therapy. *N Engl J Med*. 1977;297(2):69–75. <https://doi.org/10.1056/nejm197707142970201>
63. Wald A, Carrell D, Remington M, Kexel E, Zeh J, Corey L. Two-day regimen of acyclovir for treatment of recurrent genital herpes simplex virus type 2 infection. *Clin Infect Dis*. 2002;34(7):944–8. <https://doi.org/10.1086/339325>
64. Bodsworth N, Bloch M, McNulty A, Denham I, Doong N, Trottier S, et al. Corrigendum to: 2-day versus 5-day famciclovir as treatment of recurrences of genital herpes: results of the FaST study. *Sex Health*. 2008;5(4):379.
65. Aoki FY, Tyring S, Diaz-Mitoma F, Gross G, Gao J, Hamed K. Single-day, patient-initiated famciclovir therapy for recurrent genital herpes: a randomized, double-blind, placebo-controlled trial. *Clin Infect Dis*. 2006;42(1):8–13. <https://doi.org/10.1086/498521>
66. Abudalu M, Tyring S, Koltun W, Bodsworth N, Hamed K. Single-day, patient-initiated famciclovir therapy versus 3-day valacyclovir regimen for recurrent genital herpes: a randomized, double-blind, comparative trial. *Clin Infect Dis*. 2008;47(5):651–8. <https://doi.org/10.1086/590561>
67. Leone PA, Trottier S, Miller JM. Valacyclovir for episodic treatment of genital herpes: a shorter 3-day treatment course compared with 5-day treatment. *Clin Infect Dis*. 2002;34(7):958–62. <https://doi.org/10.1086/339326>
68. Strand A, Patel R, Wulf HC, Coates KM. Aborted genital herpes simplex virus lesions: findings from a randomised controlled trial with valaciclovir. *Sex Transm Infect*. 2002;78(6):435–9.
69. Straus SE, Tariff HE, Seidlin M, Bachrach S, Lininger L, DiGiovanna JJ, et al. Suppression of frequently recurring genital herpes: a placebo-controlled double-blind trial of oral acyclovir. *N Engl J Med*. 1984;310(24):1545–50.
70. Engel JP. Long-term suppression of genital herpes. *JAMA*. 1998;280(10):928–9.
71. Handsfield HH, Warren T, Werner M, Phillips JA. Suppressive therapy with valacyclovir in early genital herpes: a pilot study of clinical efficacy and herpes-related quality of life. *Sex Transm Dis*. 2007;34(6):339–43.
72. Fife KH, Warren TJ, Justus SE, Heitman CK, HS2100275 Study Team. An international, randomized, double-blind, placebo-controlled, study of valacyclovir for the suppression of herpes simplex virus type 2 genital herpes in newly diagnosed patients. *Sex Transm Dis*. 2008;35(7):668–73.
73. Mertz GJ, Jones CC, Mills J, Fife KH, Lemon SM, Stapleton JT, et al. Long-term acyclovir suppression of frequently recurring genital herpes simplex virus infection: a multicenter double-blind trial. *JAMA*. 1988;260(2):201–6.
74. Vasil'ev AN, Kagramanova ZA, Malinovskaia VV, Parfenov VV. Viferon suppositories in therapy of relapsing herpesvirus infection in women. *Antibiot Khimioter*. 2009;54(5–6):54–6, 58.
75. Mindel A, Faherty A, Carney O, Patou G, Freris M, Williams P. Dosage and safety of long-term suppressive acyclovir therapy for recurrent genital herpes. *Lancet*. 1988;1(8591):926–8.
76. Lebrun-Vignes B, Bouzamondo A, Dupuy A, Guillaume JC, Lechat P, Chosidow O. A meta-analysis to assess the efficacy of oral antiviral treatment to prevent genital herpes outbreaks. *J Am Acad Dermatol*. 2007;57(2):238–46. <https://doi.org/10.1016/j.jaad.2007.02.008>
77. Highlights of prescribing information. Valacyclovir Oral. Available at: [https://gskpro.com/content/dam/global/hcpportal/en\\_US/Prescribing\\_Information/Valtrex/pdf/VALTREX-PI-PIL.PDF](https://gskpro.com/content/dam/global/hcpportal/en_US/Prescribing_Information/Valtrex/pdf/VALTREX-PI-PIL.PDF) (last accessed 01 July 2024).
78. WHO. Guidelines for the treatment of genital Herpes Simplex virus. Geneva: World Health Organization; 2016. 4, Recommendations for treatment of genital Herpes Simplex Virus. Available at: <https://www.ncbi.nlm.nih.gov/books/NBK396233/> (last accessed 03 April 2024).
79. Wasserheit JN. Epidemiological synergy. Interrelationships between human immunodeficiency virus infection and other sexually transmitted diseases. *Sex Transm Dis*. 1992;19(2):61–77.
80. Hook EW III, Cannon RO, Nahmias AJ, Lee FF, Campbell CH Jr, Glasser D, et al. Herpes simplex virus infection as a risk factor for human immunodeficiency virus infection in heterosexuals. *J Infect Dis*. 1992;165(2):251–5.
81. Mosca JD, Bednarik DP, Raj NB, Rosen CA, Sodroski JG, Haseltine WA, et al. Activation of human immunodeficiency virus by herpesvirus infection: identification of a region within the long terminal repeat that responds to a trans-acting factor encoded by herpes simplex virus 1. *Proc Natl Acad Sci U S A*. 1987;84(21):7408–12.
82. Ostrove JM, Leonard J, Weck KE, Rabson AB, Gendelman HE. Activation of the human immunodeficiency virus by herpes simplex virus type 1. *J Virol*. 1987;61(12):3726–32.
83. Golden MP, Kim S, Hammer SM, Ladd EA, Schaffer PA, DeLuca N, et al. Activation of human immunodeficiency virus by herpes simplex virus. *J Infect Dis*. 1992;166(3):494–9.
84. Margolis DM, Rabson AB, Straus SE, Ostrove JM. Transactivation of the HIV-1 LTR by HSV-1 immediate-early genes. *Virology*. 1992;186(2):788–91.
85. Koelle DM, Abbo H, Peck A, Ziegweid K, Corey L. Direct recovery of herpes simplex virus (HSV)-specific T lymphocyte clones from recurrent genital HSV-2 lesions. *J Infect Dis*. 1994;169(5):956–61.
86. Kreiss J, Carael M, Meheus A. Role of sexually transmitted diseases in transmitting human immunodeficiency virus. *Genitourin Med*. 1988;64(1):1–2.
87. Kreiss JK, Coombs R, Plummer F, Holmes KK, Nikora B, Cameron W, et al. Isolation of human immunodeficiency virus from genital ulcers in Nairobi prostitutes. *J Infect Dis*. 1989;160(3):380–4.
88. Schacker T, Ryncarz AJ, Goddard J, Diem K, Shaughnessy M, Corey L. Frequent recovery of HIV-1 from genital herpes simplex virus lesions in HIV-1-infected men. *JAMA*. 1998;280(1):61–6.
89. Nagot N, Ouédraogo A, Foulongne V, Konaté I, Weiss HA, Vergne L, et al. Reduction of HIV-1 RNA levels with therapy to suppress herpes simplex virus. *N Engl J Med*. 2007;356(8):790–9.
90. Todd J, Grosskurth H, Chagalucha J, Obasi A, Mosha F, Balira R, et al. Risk factors influencing HIV infection incidence in a rural African population: a nested case-control study. *J Infect Dis*. 2006;193(3):458–66.
91. Freeman EE, Weiss HA, Glynn JR, Cross PL, Whitworth JA, Hayes RJ. Herpes simplex virus 2 infection increases HIV acquisition in men and women: systematic review and meta-analysis of longitudinal studies. *AIDS*. 2006;20(1):73–83.
92. Chen CY, Ballard RC, Beck-Sague CM, Dangor Y, Radebe F, Schmid S, et al. Human immunodeficiency virus infection and genital ulcer disease in South Africa: the herpetic connection. *Sex Transm Dis*. 2000;27(1):21–9.
93. Bagdades EK, Pillay D, Squire SB, O'Neil C, Johnson MA, Griffiths PD. Relationship between herpes simplex virus ulceration and CD4+ cell counts in patients with HIV infection. *AIDS*. 1992;6(11):1317–20.
94. Wright PW, Hoesley CJ, Squires KE, Croom-Rivers A, Weiss HL, Gnann JW Jr. A prospective study of genital herpes simplex virus type 2 infection in human immunodeficiency virus type 1 (HIV-1)-seropositive women: correlations with CD4 cell count and plasma HIV-1 RNA level. *Clin Infect Dis*. 2003;36(2):207–11. <https://doi.org/10.1086/345440>
95. Quinnan GV, Masur H, Rook AH, Armstrong G, Frederick WR, Epstein J, et al. Herpesvirus infections in the acquired immune deficiency syndrome. *JAMA*. 1984;252(1):72–7.

96. Maier JA, Bergman A, Ross MG. Acquired immunodeficiency syndrome manifested by chronic primary genital herpes. *Am J Obstet Gynecol.* 1986;155(4):756–8.
97. Leung DT, Sacks SL. Current recommendations for the treatment of genital herpes. *Drugs.* 2000;60(6):1329–52.
98. Drew WL, Buhles W, Erlich KS. Management of herpes virus infection (cytomegalovirus, herpes simplex virus and varicella zoster virus). *The medical management of AIDS.* Vol 13. 9th ed. London: Saunders; 2012. p. 433–54.
99. Aoki FY. Management of genital herpes in HIV-infected patients. *Herpes.* 2001;8(2):41–5.
100. Foley E, Patel R. Treatment of genital herpes infections in HIV-infected patients. *J HIV Ther.* 2004;9(1):14–8.
101. Marks GL, Nolan PE, Erlich KS, Ellis MN. Mucocutaneous dissemination of acyclovir-resistant herpes simplex virus in a patient with AIDS. *Rev Infect Dis.* 1989;11(3):474–6.
102. Celum C, Wald A, Hughes J, Sanchez J, Reid S, Delany-Moretlwe S, et al. Effect of aciclovir on HIV-1 acquisition in herpes simplex virus 2 seropositive women and men who have sex with men: a randomised, double-blind, placebo-controlled trial. *Lancet.* 2008;371(9630):2109–19.
103. Celum C, Wald A, Lingappa JR, Magaret AS, Wang RS, Mugo N, et al. Acyclovir and transmission of HIV-1 from persons infected with HIV-1 and HSV-2. *N Engl J Med.* 2010;362(5):427–39.
104. Sacks SL, Wanklin RJ, Reece DE, Hicks KA, Tyler KL, Coen DM. Progressive esophagitis from acyclovir-resistant herpes simplex. Clinical roles for DNA polymerase mutants and viral heterogeneity? *Ann Intern Med.* 1989;111(11):893–9.
105. Gateley A, Gander RM, Johnson PC, Kit S, Otsuka H, Kohl S. Herpes simplex virus type 2 meningoencephalitis resistant to acyclovir in a patient with AIDS. *J Infect Dis.* 1990;161(4):711–5.
106. Englund JA, Zimmerman ME, Swierkosz EM, Goodman JL, Scholl DR, Balfour HH Jr. Herpes simplex virus resistant to acyclovir. A study in a tertiary care center. *Ann Intern Med.* 1990;112(6):416–22.
107. Ratnam I, Chiu C, Kandala NB, Easterbrook PJ. Incidence and risk factors for immune reconstitution inflammatory syndrome in an ethnically diverse HIV type 1-infected cohort. *Clin Infect Dis.* 2006;42(3):418–27. <https://doi.org/10.1086/499356>
108. Fox PA, Barton SE, Francis N, Youle M, Henderson DC, Pillay D, et al. Chronic erosive herpes simplex virus infection of the penis, a possible immune reconstitution disease. *HIV Med.* 1999;1(1):10–8.
109. Graham SM, Masese L, Gitau R, Mwakangalu D, Jaoko W, Ndinya-Achola J, et al. Increased risk of genital ulcer disease in women during the first month after initiating antiretroviral therapy. *J Acquir Immune Defic Syndr.* 2009;52(5):600–3.
110. Couppié P, Sarazin F, Clyti E, Guedj ME, Vaz T, Sainte-Marie D, et al. Increased incidence of genital herpes after HAART initiation: a frequent presentation of immune reconstitution inflammatory syndrome (IRIS) in HIV-infected patients. *AIDS Patient Care STDS.* 2006;20(3):143–5.
111. Stone KM, Whittington WL. Treatment of genital herpes. *Rev Infect Dis.* 1990;12(Suppl\_6):S610–S619.
112. Conant MA, Schacker TW, Murphy RL, Gold J, Crutchfield LT, Crooks RJ. Valaciclovir versus aciclovir for herpes simplex virus infection in HIV-infected individuals: two randomized trials. *Int J STD AIDS.* 2002;13(1):12–21.
113. Cowan FM, Pascoe SJ, Barlow KL, Langhaug LF, Jaffar S, Hargrove JW, et al. A randomised placebo-controlled trial to explore the effect of suppressive therapy with acyclovir on genital shedding of HIV-1 and herpes simplex virus type 2 among Zimbabwean sex workers. *Sex Transm Infect.* 2008;84(7):548–53.
114. DeJesus E, Wald A, Warren T, Schacker TW, Trottier S, Shahmanesh M, et al. Valacyclovir for the suppression of recurrent genital herpes in human immunodeficiency virus-infected subjects. *J Infect Dis.* 2003;188(7):1009–16.
115. Warren T, Harris J, Brennan CA. Efficacy and safety of valacyclovir for the suppression and episodic treatment of herpes simplex virus in patients with HIV. *Clin Infect Dis.* 2004;39(Suppl 5):S258–S266. <https://doi.org/10.1086/422362>
116. CDC – 2015 sexually transmitted diseases treatment guidelines – genital HSV infections. Available at: <http://www.cdc.gov/std/tg2015/herpes.htm> (Last accessed on 02 September 2016).
117. Delany S, Mlaba N, Clayton T, Akpomimie G, Capovilla A, Legoff J, et al. Impact of aciclovir on genital and plasma HIV-1 RNA in HSV-2/HIV-1 co-infected women: a randomized placebo-controlled trial in South Africa. *AIDS.* 2009;23(4):461–9.
118. Lalezari J, Schacker T, Feinberg J, Gathe J, Lee S, Cheung T, et al. A randomized, double-blind, placebo-controlled trial of cidofovir gel for the treatment of acyclovir-unresponsive mucocutaneous herpes simplex virus infection in patients with AIDS. *J Infect Dis.* 1997;176(4):892–8.
119. Stránská R, Schuurman R, Nienhuis E, Goedegebuure IW, Polman M, Weel JF, et al. Survey of acyclovir-resistant herpes simplex virus in The Netherlands: prevalence and characterization. *J Clin Virol.* 2005;32(1):7–18.
120. Hill EL, Hunter GA, Ellis MN. In vitro and in vivo characterization of herpes simplex virus clinical isolates recovered from patients infected with human immunodeficiency virus. *Antimicrob Agents Chemother.* 1991;35(11):2322–8.
121. Safran S. Treatment of acyclovir-resistant herpes simplex virus infections in patients with AIDS. *J Acquir Immune Defic Syndr.* 1992;5(Suppl 1):S29–S32.
122. Gnann J, Davis M, Harden E. Resistance T force on Hacyclovir-resistant HSV from HIV-infected individuals. Population surveillance and in vitro characterization of isolates (abstract). New Orleans, USA. In 38th annual international disease Society of America (IDSA) meeting 2000.
123. Engel JP, Englund JA, Fletcher CV, Hill EL. Treatment of resistant herpes simplex virus with continuous-infusion acyclovir. *JAMA.* 1990;263(12):1662–4.
124. Deza G, Martin-Ezquerro G, Curto-Barredo L, Villar García J, Pujol RM. Successful treatment of hypertrophic herpes simplex genitalis in HIV-infected patient with topical imiquimod. *J Dermatol.* 2015;42(12):1176–8. <https://doi.org/10.1111/1346-8138.12969>
125. Sbidian E, Battistella M, LeGoff J, Lafaurie M, Bézier M, Agbalika F, et al. Recalcitrant pseudotumoral anogenital herpes simplex virus type 2 in HIV-infected patients: evidence for predominant B-lymphoplasmocytic infiltration and immunomodulators as effective therapeutic strategy. *Clin Infect Dis.* 2013;57(11):1648–55.
126. Holmes A, McMenamin M, Mulcahy F, Bergin C. Thalidomide therapy for the treatment of hypertrophic herpes simplex virus-related genitalis in HIV-infected individuals. *Clin Infect Dis.* 2007;44(11):e96–e99. <https://doi.org/10.1086/517513>
127. Serris A, Pouvaret A, Loiseau C, Abid H, Burrel S, Fourgeaud J, et al. Pritelivir for recurrent aciclovir-resistant herpes simplex virus 2 infections in immunocompromised patients. *J Antimicrob Chemother.* 2022;77(8):2303–5.
128. Kawashima M, Imafuku S, Fujio K, Komazaki H. Single-dose, patient-initiated amenamevir therapy for recurrent genital herpes: a phase 3, randomized, double-blind, placebo-controlled study. *Open Forum Infect Dis.* 2022;9(10):ofac494. <https://doi.org/10.1093/ofid/ofac494>
129. Sheffield JS, Hollier LM, Hill JB, Stuart GS, Wendel GD. Acyclovir prophylaxis to prevent herpes simplex virus recurrence at delivery: a systematic review. *Obstet Gynecol.* 2003;102(6):1396–403.
130. Watts DH, Brown ZA, Money D, Selke S, Huang ML, Sacks SL, et al. A double-blind, randomized, placebo-controlled trial of acyclovir in late pregnancy for the reduction of herpes simplex virus shedding and cesarean delivery. *Am J Obstet Gynecol.* 2003;188(3):836–43.
131. Scott LL, Hollier LM, McIntire D, Sanchez PJ, Jackson GL, Wendel GD Jr. Acyclovir suppression to prevent recurrent genital herpes at delivery. *Infect Dis Obstet Gynecol.* 2002;10(2):71–7. <https://doi.org/10.1155/s1064744902000054>
132. Brocklehurst P, Kinghorn G, Carney O, Helsen K, Ross E, Ellis E, et al. A randomised placebo controlled trial of suppressive acyclovir in late pregnancy in women with recurrent genital herpes infection. *BJOG.* 1998;105(3):275–80.
133. Scott LL, Sanchez PJ, Jackson GL, Zeray F, Wendel GD Jr. Acyclovir suppression to prevent cesarean delivery after first-episode genital herpes. *Obstet Gynecol.* 1996;87(1):69–73.



134. Braig S, Luton D, Sibony O, Edlinger C, Boissinot C, Blot P, et al. Acyclovir prophylaxis in late pregnancy prevents recurrent genital herpes and viral shedding. *Eur J Obstet Gynecol Reprod Biol.* 2001;96(1):55–8.
135. Hollier LM, Wendel GD. Third trimester antiviral prophylaxis for preventing maternal genital herpes simplex virus (HSV) recurrences and neonatal infection. *Cochrane Database Syst Rev.* 2008;23(1):CD004946. <https://doi.org/10.1002/14651858.CD004946.pub2>
136. Sheffield JS, Hill JB, Hollier LM, Laibl VR, Roberts SW, Sanchez PJ, et al. Valacyclovir prophylaxis to prevent recurrent herpes at delivery: a randomized clinical trial [published correction appears in *Obstet Gynecol.* 2006;108(3 Pt 1):695]. *Obstet Gynecol.* 2006;108(1):141–7. <https://doi.org/10.1097/01.AOG.0000219749.96274.15>
137. James SH, Sheffield JS, Kimberlin DW. Mother-to-child transmission of herpes simplex virus. *J Pediatric Infect Dis Soc.* 2014;3(Suppl 1):S19–S23. <https://doi.org/10.1093/jpids/piu050>
138. Pinninti SG, Angara R, Feja KN, Kimberlin DW, Leach CT, Conrad DA, et al. Neonatal herpes disease following maternal antenatal antiviral suppressive therapy: a multicenter case series. *J Pediatr.* 2012;161(1):134–8.
139. Nakubulwa S, Kaye DK, Bwanga F, Tumwesigye NM, Nakku-Joloba E, Mirembe F. Effect of suppressive acyclovir administered to HSV-2 positive mothers from week 28 to 36 weeks of pregnancy on adverse obstetric outcomes: a double-blind randomised placebo-controlled trial. *Reprod Health.* 2017;14(1):31. <https://doi.org/10.1186/s12978-017-0292-7>
140. Gardella C, Brown ZA, Wald A, Morrow RA, Selke S, Krantz E, et al. Poor correlation between genital lesions and detection of herpes simplex virus in women in labor. *Obstet Gynecol.* 2005;106(2):268–74.
141. Chen KT, Segú M, Lumey LH, Kuhn L, Carter RJ, Bulterys M, et al. Genital herpes simplex virus infection and perinatal transmission of human immunodeficiency virus. *Obstet Gynecol.* 2005;106(6):1341–8.
142. Poeran J, Wildschut H, Gaytant M, Galama J, Steegers E, van der Meijden W. The incidence of neonatal herpes in The Netherlands. *J Clin Virol.* 2008;42(4):321–5. <https://doi.org/10.1016/j.jcv.2008.02.004>
143. Acyclovir and valacyclovir in pregnancy registry final report. 1999 Available at: <http://pregnancyregistry.gsk.com/acyclovir.html> (accessed 2nd September 2016).
144. Hemelaar SJ, Poeran J, Steegers EA, van der Meijden WI. Neonatal herpes infections in The Netherlands in the period 2006–2011. *J Matern Fetal Neonatal Med.* 2015;28(8):905–9. <https://doi.org/10.3109/14767058.2014.937691>
145. Andrews WW, Kimberlin DF, Whitley R, Cliver S, Ramsey PS, Deeter R. Valacyclovir therapy to reduce recurrent genital herpes in pregnant women. *Am J Obstet Gynecol.* 2006;194(3):774–81. <https://doi.org/10.1016/j.ajog.2005.11.051>
146. Pasternak B, Hviid A. Use of acyclovir, valacyclovir, and famciclovir in the first trimester of pregnancy and the risk of birth defects. *JAMA.* 2010;304(8):859–66. <https://doi.org/10.1001/jama.2010.1206>
147. GSK acyclovir and valacyclovir pregnancy registries. Available at: <https://pregnancyregistry.gsk.com/index.html> (last accessed on 03 April 2024)
148. Langenberg A, Benedetti J, Jenkins J, Ashley R, Winter C, Corey L. Development of clinically recognizable genital lesions among women previously identified as having “asymptomatic” herpes simplex virus type 2 infection. *Ann Intern Med.* 1989;110(11):882–7.

## SUPPORTING INFORMATION

Additional supporting information can be found online in the Supporting Information section at the end of this article.

**How to cite this article:** Patel R, Moran B, Clarke E, Geretti AM, Lautenschlager S, Green J, et al. 2024 European guidelines for the management of genital herpes. *J Eur Acad Dermatol Venereol.* 2024;00:1–17. <https://doi.org/10.1111/jdv.20450>