

EAU GUIDELINES ON UROTHELIAL CARCINOMA OF THE UPPER URINARY TRACT (UTUCs)

(Limited text update March 2022)

M. Rouprêt, M. Babjuk, M. Burger, E. Compérat, F. Liedberg, A. Masson-Lecomte, A.H. Mostafid, J. Palou, B.W.G. van Rhijn, S.F. Shariat, R. Sylvester

Patient Advocates: I. Benedicte Gurses, R. Wood

Guidelines Associates: O. Capoun, D. Cohen, J.L. Dominguez-Escrig, T. Seisen, V. Soukup

Epidemiology

Upper urinary tract urothelial carcinomas (UTUCs) are uncommon and account for only 5-10% of urothelial carcinomas (UCs). They have a similar morphology to bladder carcinomas and nearly all UTUCs are urothelial in origin.

| Recommendations | Strength rating |
|---|-----------------|
| Evaluate patient and family history based on the Amsterdam criteria to identify patients with upper tract urothelial carcinoma. | Weak |
| Evaluate patient exposure to smoking and aristolochic acid. | Weak |

Staging and grading systems

The UICC 2017 TNM (Tumour, Node, Metastasis Classification) for the renal pelvis and ureter is used for staging (Table 1).

Tumour grade

The 2004/2016 WHO classification distinguishes between non-invasive tumours:

- papillary urothelial neoplasia of low malignant potential;
- low-grade papillary UCs;
- high-grade papillary UCs.

As well as define flat lesions (carcinoma *in situ*) and invasive carcinoma.

Upper urinary tract tumours with low malignant potential are very rare.

Table 1: TNM Classification 2017

| T - Primary tumour | |
|---------------------------------|--|
| TX | Primary tumour cannot be assessed |
| T0 | No evidence of primary tumour |
| Ta | Non-invasive papillary carcinoma |
| Tis | Carcinoma <i>in situ</i> |
| T1 | Tumour invades subepithelial connective tissue |
| T2 | Tumour invades muscularis |
| T3 | (Renal pelvis) Tumour invades beyond muscularis into peripelvic fat or renal parenchyma (Ureter) Tumour invades beyond muscularis into periureteric fat |
| T4 | Tumour invades adjacent organs or through the kidney into perinephric fat |
| N - Regional lymph nodes | |
| NX | Regional lymph nodes cannot be assessed |
| N0 | No regional lymph node metastasis |
| N1 | Metastasis in a single lymph node 2 cm or less in greatest dimension |

| | |
|-------------------------------|---|
| N2 | Metastasis in a single lymph node more than 2 cm, or multiple lymph nodes |
| M - Distant metastasis | |
| M0 | No distant metastasis |
| M1 | Distant metastasis |

Diagnosis

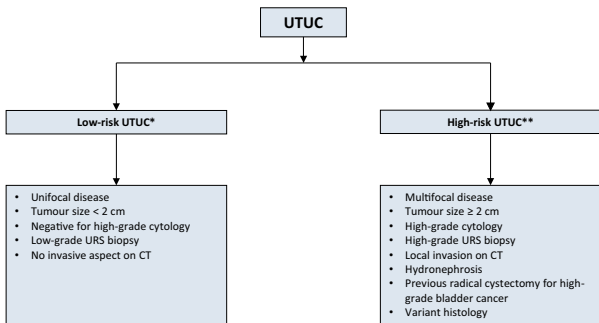
UTUCs are diagnosed using imaging, cystoscopy, urinary cytology and diagnostic ureteroscopy. Computed tomography urography has the highest diagnostic accuracy of the available imaging techniques. In case conservative management is considered, a pre-operative ureteroscopic assessment is needed.

| Recommendations | Strength rating |
|---|-----------------|
| Perform a urethrocytoscopy to rule out bladder tumour. | Strong |
| Perform a computed tomography (CT) urography for diagnosis and staging. | Strong |
| Use diagnostic ureteroscopy and biopsy if imaging and cytology are not sufficient for the diagnosis and/or risk stratification of the tumour. | Strong |
| Magnetic resonance urography or ¹⁸ F-Fluorodeoxyglucose positron emission tomography/CT may be used when CT is contra-indicated. | Weak |

Prognosis

Invasive UTUC usually have a very poor prognosis. The main factors to consider for risk stratification are listed in Figure 1.

Figure 1: Risk stratification of non-metastatic UTUC



*CT = computed tomography; URS = ureteroscopy;
UTUC = upper urinary tract urothelial carcinoma.*

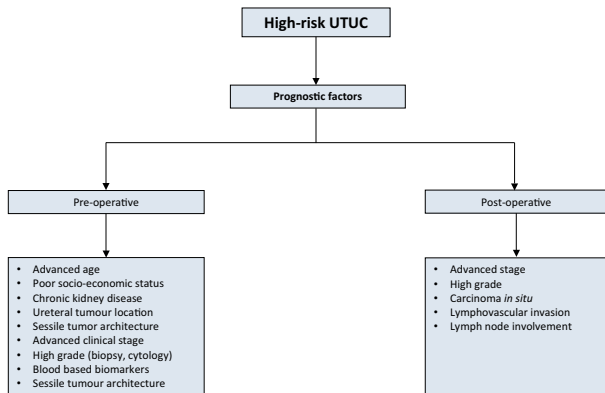
**All these factors need to be present.*

***Any of these factors need to be present.*

Risk stratification

As tumour stage is difficult to assess clinically in UTUC, it is useful to “risk stratify” UTUC between low- and high-risk tumours to identify those patients who are more likely to benefit from kidney-sparing treatment. These factors can be used to counsel patients regarding follow-up and administration of peri-operative chemotherapy (see Figures 1 and 2).

Figure 2: UTUC prognostic factors included in prognostic models



UTUC = upper urinary tract urothelial carcinoma.

| Recommendation | Strength rating |
|--|-----------------|
| Use prognostic factors to risk-stratify patients for therapeutic guidance. | Weak |

Disease management (see also Figures 3 & 4)

Localised disease

Kidney-sparing surgery

Kidney-sparing surgery for low-risk UTUC consists of surgery preserving the upper urinary renal unit and should be discussed in all low-risk cases, irrespective of the status of the contralateral kidney.

Kidney-sparing surgery potentially allows avoiding the morbidity associated with open radical surgery without compromising oncological outcomes and kidney function.

Kidney-sparing surgery can also be considered in select patients with serious renal insufficiency or solitary kidney (i.e., imperative indications).

| Recommendations | Strength rating |
|---|------------------------|
| Offer kidney-sparing management as primary treatment option to patients with low-risk tumours. | Strong |
| Offer kidney-sparing management (distal ureterectomy) to patients with high-risk tumours limited to the distal ureter. | Weak |
| Offer kidney-sparing management to patients with solitary kidney and/or impaired renal function, providing that it will not compromise survival. This decision will have to be made on a case-by-case basis in consultation with the patient. | Strong |

The instillation of bacillus Calmette-Guérin or mitomycin C in the urinary tract by percutaneous nephrostomy, or via a ureteric stent is technically feasible after kidney-sparing management, or for treatment of carcinoma *in situ*. However, the benefits have not been confirmed.

High-risk non-metastatic disease

Radical nephroureterectomy

Open nephroureterectomy (RNU) with bladder cuff excision is the standard treatment for high-risk UTUC, regardless of tumour location. Minimally-invasive approaches (i.e. pure laparoscopic and/or robot-assisted RNU) have shown oncologic equivalence in experienced hands.

- Neoadjuvant chemotherapy has been associated with significant downstaging at surgery and ultimately survival benefit as compared to RNU alone.
- Adjuvant chemotherapy was only associated with an overall survival benefit in patients with pure UC and the main limitation of using adjuvant chemotherapy for advanced UTUC remains the limited ability to deliver full dose cisplatin-based regimen after RNU, given that this surgical procedure is likely to impact renal function.
- In patients with regional lymph node invasion who are cisplatin-unfit after RNU, induction chemotherapy with radiological evaluation and consolidating surgery is a treatment option.
- A single post-operative dose of intravesical chemotherapy (mitomycin C, pirarubicin) 2-10 days after surgery reduces the risk of bladder tumour recurrence within the first years post-RNU.
- Preliminary data have shown improved disease-free survival rates for adjuvant immunotherapy (nivolumab).

| Recommendations | Strength rating |
|---|------------------------|
| Perform radical nephroureterectomy (RNU) in patients with high-risk non-metastatic UTUC. | Strong |
| Perform open RNU in non-organ-confined UTUC. | Weak |
| Perform a template-based lymphadenectomy in patients with high-risk non-metastatic UTUC. | Strong |
| Offer post-operative systemic platinum-based chemotherapy to patients with high-risk non-metastatic UTUC. | Strong |

| | |
|--|--------|
| Deliver a post-operative bladder instillation of chemotherapy to lower the intravesical recurrence rate. | Strong |
|--|--------|

Metastatic disease

Radical nephroureterectomy has no benefit in metastatic (M+) disease but may be used in palliative care. As UTUCs are urothelial tumours, platinum-based chemotherapy should provide similar results to those in bladder cancer. Currently, insufficient data are available to provide any recommendations.

Data are emerging for systemic treatments; both in first-line and subsequent-line settings. Encouraging results allow providing recommendations for a number of drugs.

| Recommendations | Strength rating |
|--|-----------------|
| Offer radical nephroureterectomy as a palliative treatment to symptomatic patients with resectable locally advanced tumours. | Weak |
| First-line treatment in cisplatin-eligible patients | |
| Use cisplatin-containing combination chemotherapy with GC or HD-MVAC. | Strong |
| Do not offer carboplatin or non-platinum combination chemotherapy. | Strong |
| Use maintenance avelumab in patients who did not have disease progression after 4 to 6 cycles of gemcitabine plus cisplatin. | Strong |
| First-line treatment in patients unfit for cisplatin | |
| Offer checkpoint inhibitors pembrolizumab or atezolizumab depending on PD-L1 status. | Weak |
| Offer carboplatin combination chemotherapy if PD-L1 is negative. | Strong |

| | |
|--|--------|
| Use maintenance avelumab in patients who did not have disease progression after 4 to 6 cycles of gemcitabine plus carboplatin. | Strong |
| Second-line treatment | |
| Offer checkpoint inhibitor (pembrolizumab) to patients with disease progression during or after platinum-based combination chemotherapy for metastatic disease. | Strong |
| Offer checkpoint inhibitor (atezolizumab or nivolumab) to patients with disease progression during or after platinum-based combination chemotherapy for metastatic disease. | Strong |
| Offer erdafitinib in platinum refractory tumours with FGFR alterations. | Strong |
| Only offer vinflunine to patients for metastatic disease as second-line treatment if immunotherapy or combination chemotherapy is not feasible. Alternatively, offer vinflunine as third- or subsequent-line treatment | Strong |

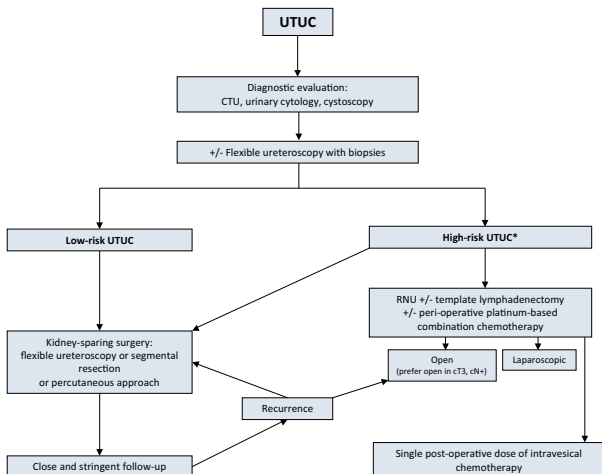
GC = gemcitabine plus cisplatin; FGFR = fibroblast growth factor receptors; HD-MVAC = high-dose intensity methotrexate, vinblastine, adriamycin plus cisplatin; PD-L1 = programmed death ligand 1; PCG = paclitaxel, cisplatin, gemcitabine.

Follow-up after initial treatment

In all cases, there should be strict follow-up after radical management to detect metachronous bladder tumours, as well as invasive tumours, local recurrence and distant metastases. When kidney-sparing surgery is performed, the ipsilateral upper urinary tract requires careful follow-up due to the high risk of recurrence.

| Recommendations | Strength rating |
|---|-----------------|
| After radical nephroureterectomy | |
| <i>Low-risk tumours</i> | |
| Perform cystoscopy at 3 months. If negative, perform subsequent cystoscopy 9 months later and then yearly, for 5 years. | Weak |
| <i>High-risk tumours</i> | |
| Perform cystoscopy and urinary cytology at 3 months. If negative, repeat subsequent cystoscopy and cytology every 3 months for a period of 2 years, and every 6 months thereafter until 5 years, and then yearly. | Weak |
| Perform computed tomography (CT) urography and chest CT every 6 months for 2 years, and then yearly. | Weak |
| After kidney-sparing management | |
| <i>Low-risk tumours</i> | |
| Perform cystoscopy and CT urography at 3 and 6 months, and then yearly for 5 years. | Weak |
| Perform ureteroscopy (URS) at 3 months. | Weak |
| <i>High-risk tumours</i> | |
| Perform cystoscopy, urinary cytology, CT urography and chest CT at 3 and 6 months, and then yearly. | Weak |
| Perform URS and urinary cytology <i>in situ</i> at 3 and 6 months. | Weak |

Figure 3: Proposed flowchart for the management of UTUC



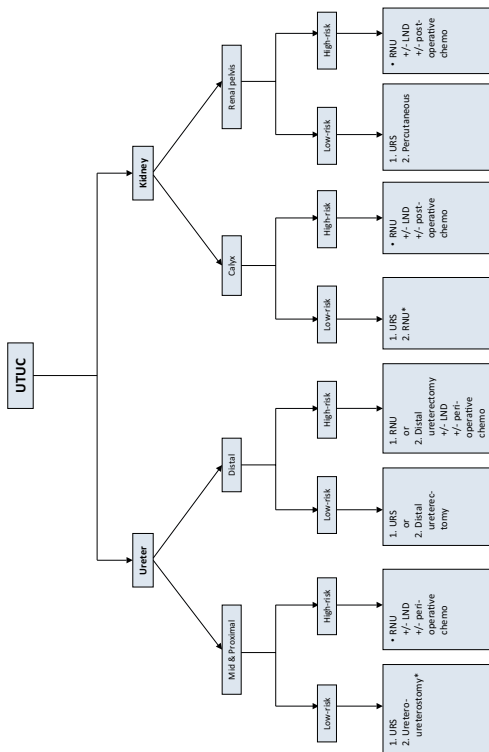
* *In patients with a solitary kidney, consider a more conservative approach.*

CTU = computed tomography urography;

RNU = nephroureterectomy; UTUC = upper urinary tract urothelial carcinoma.

This short booklet text is based on the more comprehensive EAU Guidelines (ISBN 978-94-92671-16-5) available to all members of the European Association of Urology at their website, <http://www.uroweb.org/guidelines>.

Figure 4: Surgical treatment according to location and risk status



**In patients with solitary kidney, consider a more conservative approach.*

CTU = computed tomography urography; RNU = radical nephroureterectomy; UTUC = upper urinary tract urothelial carcinoma.