

EAU GUIDELINES ON UROLOGICAL TRAUMA

(Limited text update March 2022)

N.D. Kitrey (Chair), F. Campos-Juanatey, P. Hallscheidt,
E. Serafetinidis, D.M. Sharma, M. Waterloos.

Guidelines Associates: K. Zimmermann.

Guidelines Office: E.J. Smith.

Introduction

Traumatic injuries are classified according to the basic mechanism of the injury into **penetrating** and **blunt** injuries. Penetrating trauma is further classified according to the velocity of the projectile into high- and medium-velocity projectiles (e.g. rifle and handgun bullets, respectively), and low-velocity items (e.g. knife stab). High-velocity weapons inflict greater damage due to a temporary expansive cavitation that causes destruction in a much larger area than the projectile tract itself. In lower velocity injuries, the damage is usually confined to the projectile tract. **Blast injury** is a complex cause of trauma which includes blunt and penetrating trauma and burns.

Urological trauma is often associated with significant injuries in the polytraumatised patient. Advances in trauma care include the widespread acceptance of damage control principles and trauma centralisation to major trauma centres staffed by dedicated trauma teams. Urologists increasingly understand their role in the context of polytrauma with the ultimate aims of improving survivability and decreasing morbidity in these patients.

Renal Trauma

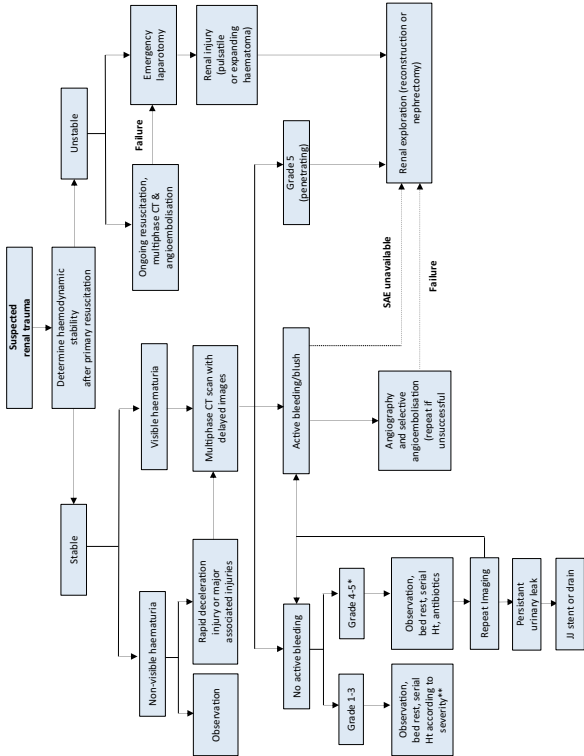
Renal trauma is present in to up 5% of all trauma cases. It is most common in young males and has an overall population incidence of 4.9 per 100,000. Most injuries can be managed non-operatively with successful organ preservation. The most commonly used classification system is that of the American Association for the Surgery of Trauma. It is validated and predicts morbidity and the need for intervention.

Recommendations for evaluation and management of renal trauma

Recommendations	Strength rating
Evaluation	
Assess haemodynamic stability upon admission.	Strong
Record past renal surgery, and known pre-existing renal abnormalities (ureteropelvic junction obstruction, solitary kidney, lithiasis).	Strong
Test for haematuria in a patient with suspected renal injury.	Strong
Perform a multiphase computed tomography scan in trauma patients with: <ul style="list-style-type: none">• visible haematuria;• non-visible haematuria and one episode of hypotension;• a history of rapid deceleration injury and/or significant associated injuries;• penetrating trauma;• clinical signs suggesting renal trauma e.g. flank pain, abrasions, fractured ribs, abdominal distension and/or a mass and tenderness.	Strong

Management	
Manage stable patients with blunt renal trauma non-operatively with close monitoring and re-imaging as required.	Strong
Manage isolated Grade 1-4 stab and low-velocity gunshot wounds in stable patients non-operatively.	Strong
Use selective angioembolisation for active renal bleeding if there are no other indications for immediate surgical exploration.	Strong
Proceed with renal exploration in the presence of: <ul style="list-style-type: none"> • persistent haemodynamic instability; • Grade 5 vascular or penetrating injury; • expanding or pulsatile peri-renal haematoma. 	Strong
Attempt renal reconstruction if haemorrhage is controlled and there is sufficient viable renal parenchyma.	Weak
Repeat imaging in high-grade injuries and in cases of fever, worsening flank pain, or falling haematocrit.	Strong
Follow-up approximately three months after major renal injury with: <ul style="list-style-type: none"> • physical examination; • urinalysis; • individualised radiological investigation including nuclear scintigraphy; • blood pressure measurement; • renal function tests. 	Weak
Measure blood pressure annually to diagnose renovascular hypertension.	Strong

Figure 1: Management of renal trauma



* Excluding Grade 5 penetrating injuries.

** Antibiotics should be administered for all penetrating injuries.

— If haemodynamically unstable.

CT = computed tomography; Ht = haematocrit; SAE = selective angioembolisation.

Ureteral Trauma

Ureteral injuries are quite rare - most are iatrogenic. They are often missed intra-operatively, usually involve the lower ureter, and may result in severe sequelae. Overall, ureteral trauma accounts for 1-2.5% of urinary tract trauma. Ureteral injury should be suspected in all cases of penetrating abdominal injury, especially gunshot wounds, as it occurs in 2-3% of cases. It should also be suspected in blunt trauma with a deceleration mechanism, as the renal pelvis can be torn away from the ureter.

Diagnostic evaluation

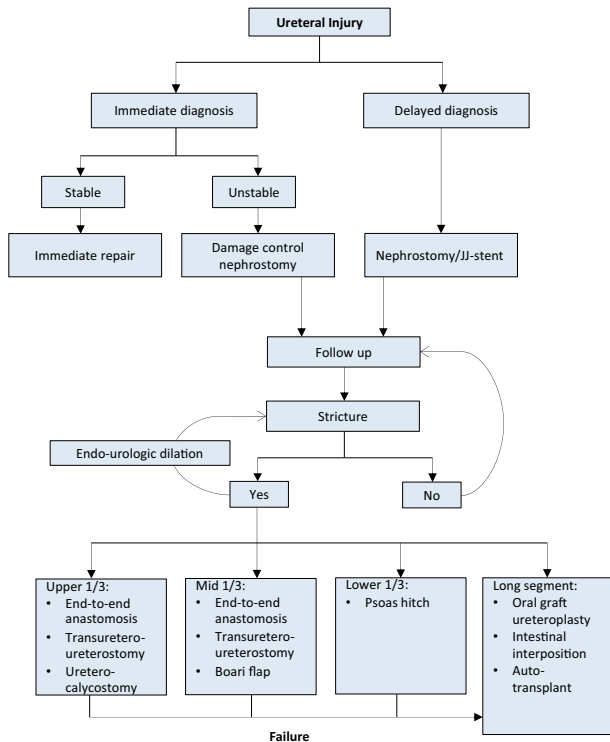
- A high index of suspicion of ureteral injury should be maintained as the majority of cases are diagnosed late, predisposing the patient to pain, infection, and renal function impairment.
- Haematuria is an unreliable indicator.
- Extravasation of contrast material in computed tomography (CT) is the hallmark sign of ureteral trauma.
- In unclear cases, a retrograde or antegrade urography is required for confirmation.

Management of ureteral trauma

Recommendations	Strength rating
Visually identify the ureters to prevent ureteral trauma during abdominal and pelvic surgery.	Strong
Beware of concomitant ureteral injury in all abdominal penetrating trauma, and in deceleration-type blunt trauma.	Strong
Use pre-operative prophylactic stents in high-risk cases.	Strong

Repair iatrogenic ureteral injuries recognised during surgery immediately.	Strong
Treat iatrogenic ureteral injuries with delayed diagnosis by nephrostomy tube/JJ stent urinary diversion.	Strong
Manage ureteral strictures by ureteral reconstruction according to the location and length of the affected segment.	Strong

Figure 2: Management of ureteric injuries



Bladder Trauma

Bladder trauma is primarily classified according to the location of the injury: **intraperitoneal**, **extraperitoneal**, and **combined** intra-extraperitoneal as it guides further management. Bladder trauma is categorised by aetiology: **non-iatrogenic** (blunt and penetrating) and **iatrogenic** (external and internal). Extraperitoneal injury is almost always associated with pelvic fractures. Intraperitoneal injury is caused by a sudden rise in intravesical pressure of a distended bladder, secondary to a blow to the pelvis or lower abdomen.

Diagnostic evaluation

The principal sign of bladder injury is visible haematuria. Absolute indications for bladder imaging include: visible haematuria and a pelvic fracture or non-visible haematuria combined with high-risk pelvic fracture or posterior urethral injury. In the absence of these absolute indications, further imaging is based on clinical signs and symptoms including:

- inability to void or inadequate urine output;
- abdominal tenderness or distension due to urinary ascites, or signs of urinary ascites in abdominal imaging;
- uraemia and elevated creatinine level due to intraperitoneal re-absorption;
- entry/exit wounds at lower abdomen, perineum or buttocks in penetrating injuries.

Intra-operative signs of external iatrogenic bladder injury include: extravasation of urine, visible laceration, visible bladder catheter, and blood and/or gas in the urine bag during laparoscopy. Internal bladder injury is recognised by cystoscopic identification of fatty tissue, dark space, or bowel.

Imaging – Cystography and Cystoscopy

Cystography is the preferred diagnostic modality for non-iatrogenic bladder injury and for a suspected iatrogenic

bladder trauma in the post-operative setting. Intraperitoneal extravasation is visualised by free contrast medium in the abdomen outlining bowel loops or abdominal viscera. Extraperitoneal bladder injury is typically diagnosed by flame-shaped areas of contrast extravasation in the peri-vesical soft tissues. **Cystoscopy** is the preferred method for detection of intra-operative bladder injuries as it may directly visualise the laceration and can localise the lesion in relation to the position of the trigone and ureteral orifices.

Management of bladder trauma

Recommendations	Strength rating
Perform cystography in the presence of visible haematuria and pelvic fracture.	Strong
Perform cystography in case of suspected iatrogenic bladder injury in the post-operative setting.	Strong
Perform cystography with active retrograde filling of the bladder with dilute contrast (300-350 mL).	Strong
Perform cystoscopy to rule out bladder injury during retropubic sub-urethral sling procedures.	Strong
Manage uncomplicated blunt extra-peritoneal bladder injuries conservatively.	Weak
Manage blunt extraperitoneal bladder injuries operatively in cases of bladder neck involvement and/or associated injuries that require surgical intervention.	Strong
Manage blunt intraperitoneal injuries by surgical exploration and repair.	Strong

Manage small uncomplicated intra-peritoneal bladder injuries during endoscopic procedures conservatively.	Weak
Perform cystography to assess bladder wall healing after repair of a complex injury or in case of risk factors for wound healing.	Strong

Urethral Trauma

- Injuries to the anterior urethra are caused by straddle injuries, trauma during sexual intercourse (associated with penile fracture), penetrating trauma and from iatrogenic trauma e.g. endoscopic instruments, catheterisation.
- Pelvic fractures are the predominant cause of male posterior and female urethral injury.
- Pelvic fracture and penetrating urethral injuries have a high likelihood of life-threatening concomitant injuries.
- Female urethral injuries are often associated with vaginal injuries.
- Insertion of a synthetic sub-urethral sling for the treatment of stress urinary incontinence is an important cause of iatrogenic **female** urethral injury.

Diagnostic evaluation

- Blood at the external urethral meatus is the most common clinical sign, and indicates the need for further diagnostic work up.
- Inability to void is usually a sign of a complete injury.
- Incomplete injuries are associated with pain on urination and haematuria in the majority of cases.
- Blood at the vaginal introitus is present in the majority of female patients with pelvic fractures and co-existing urethral injuries.
- Rectal examination may reveal a "high-riding" prostate; however, this is an unreliable finding. Blood on the examination finger is suggestive of a rectal injury

associated with pelvic fracture.

- Urethral bleeding or urinary extravasation can cause penile and scrotal swelling and haematoma, but these findings are usually delayed (> 1 hr).
- Retrograde urethrography is the standard in the early evaluation of a male urethral injury, except for penile fracture related injuries for which cysto-urethroscopy is preferred.
- Cysto-urethroscopy combined with vaginoscopy is the preferred diagnostic modality in case of suspected female urethral injury.

Management

Male urethral injuries

- The management of male anterior and posterior urethral injuries are summarised in Figure 3 and 4, respectively.

Female urethral injuries

- In case of haemodynamic instability, provide urinary diversion by suprapubic catheterisation or a single attempt at urethral catheterisation.
- Early repair within seven days has the highest success rate and the lowest complication rate in comparison with delayed repair or early endoscopic re-alignment.

Management of urethral trauma

Recommendations	Strength rating
Provide appropriate training to reduce the risk of traumatic catheterisation.	Strong
Evaluate male urethral injuries with flexible cysto-urethroscopy and/or retrograde urethrography.	Strong
Evaluate female urethral injuries with cysto-urethroscopy and vaginoscopy.	Strong

Treat iatrogenic anterior urethral injuries by transurethral or suprapubic urinary diversion.	Strong
Treat partial blunt anterior urethral injuries by suprapubic or urethral catheterisation.	Strong
Treat complete blunt anterior urethral injuries by immediate urethroplasty, if surgical expertise is available, otherwise perform suprapubic diversion with delayed urethroplasty.	Weak
Treat pelvic fracture urethral injuries (PFUIs) in hemodynamically unstable patients by transurethral or suprapubic catheterisation initially.	Strong
Perform early endoscopic re-alignment in male PFUIs when feasible.	Weak
Do not repeat endoscopic treatments after failed re-alignment for male PFUI.	Strong
Treat partial posterior urethral injuries initially by suprapubic or transurethral catheter.	Strong
Do not perform immediate urethroplasty (< 48 hours) in male PFUIs.	Strong
Perform early urethroplasty (two days to six weeks) for male PFUIs with complete disruption in selected patients (stable, short gap, soft perineum, lithotomy position possible).	Weak
Manage complete posterior urethral disruption in male PFUIs with suprapubic diversion and deferred (at least three months) urethroplasty.	Strong
Perform early repair (within seven days) for female PFUIs (not delayed repair or early re-alignment).	Strong

Figure 3: Management of anterior urethral injuries in men

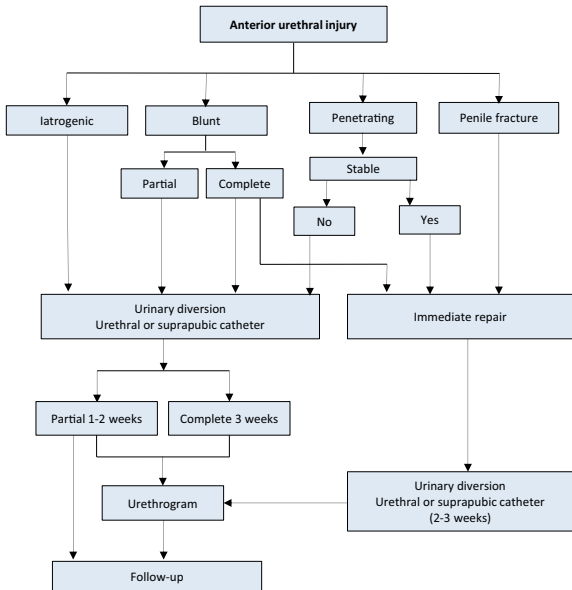
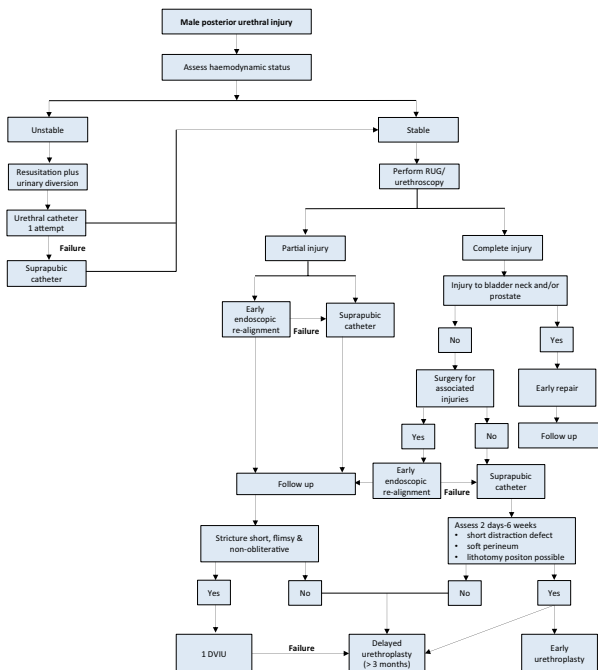


Figure 4: Management of posterior urethral injuries in men



RUG = retrograde urethrography; DVIU = direct visual internal urethrotomy.

Genital Trauma

Of all urological injuries, 33-66% involve the external genitalia. Genital trauma is much more common in males than in females this is due to anatomical differences, increased frequency of road traffic accidents and increased participation in physical sports, war and crime. The majority of genital trauma is caused by blunt injuries (80%).

Diagnostic evaluation

A summary of key points for penile fracture and testicular trauma are provided in Table 1. Blunt vulvar or perineal trauma in women may be associated with bleeding, pain and voiding problems. In genital trauma:

- Urinalysis should be performed.
- Visible haematuria requires a retrograde urethrogram in males, whilst flexible or rigid cystoscopy is recommended to exclude urethral and bladder injury in females.
- In women with genital injuries and blood at the vaginal introitus, further gynaecologic investigation to exclude vaginal injury is required.

Management

Penetrating penile trauma

- Non-operative management is recommended for small superficial injuries with intact Buck's fascia.
- More significant injuries require surgical exploration and debridement of necrotic tissue.
- Surgical approach depends upon the site and extent of the injury, but a subcoronal incision with penile degloving usually gives good exposure. Initially, a defect in the tunica albuginea should be closed after copious irrigation.
- In penile avulsion injuries acute management involves resuscitation of the patient, and preparation for surgical re-implantation of the penis if it has been recovered and is not too badly damaged.

Blunt scrotal trauma

- May result in testicular dislocation, haematocoele, testicular rupture and/or scrotal haematoma.
- Traumatic dislocation of the testis is treated by manual replacement and secondary orchidopexy. If primary manual reposition cannot be performed, immediate orchidopexy is indicated.
- If haematocoele is smaller than three times the size of the contralateral testis – conservative management.
- If large haematocoele – explore.
- If testicular rupture suspected, explore, evacuate clot and any necrotic testicular tubules and close the tunica albuginea.

Penetrating scrotal trauma

- Surgical exploration with conservative debridement of non-viable tissue.
- Primary reconstruction of testis and scrotum can be performed in most cases.
- In complete disruption of the spermatic cord, re-alignment without vaso-vasostomy may be considered.
- In extensive destruction of the tunica albuginea, mobilisation of a free tunica vaginalis flap can be performed for testicular closure.
- If reconstruction cannot be achieved, orchiectomy is indicated.
- In improvised explosive device blast injury, the extensive loss of genital tissue often requires complex and staged reconstructive surgical procedures.

Table 1. Summary of key points for penile fracture and testicular trauma

Penile fracture
The most common causes of penile fracture are sexual intercourse, forced flexion, masturbation and rolling over.
Penile fracture is associated with a sudden cracking or popping sound, pain, immediate detumescence and local swelling.
Magnetic resonance imaging is superior to all other imaging techniques in diagnosing penile fracture.
Management of penile fracture is surgical intervention with closure of the tunica albuginea.
Testicular trauma
Blunt testicular injury may occur under intense compression of the testis against the inferior pubic ramus or symphysis, resulting in a rupture of the tunica albuginea.
Testicular rupture is associated with immediate pain, nausea, vomiting, and sometimes fainting.
Scrotal ultrasound is the preferred imaging modality for the diagnosis of testicular trauma.
Surgical exploration in patients with testicular trauma ensures preservation of viable tissue when possible.

Recommendations for the management of genital trauma

Recommendations	Strength rating
Exclude urethral injury in the case of penile fracture.	Strong
Perform ultrasound (US) for the diagnosis of testis trauma.	Strong
Treat penile fractures surgically, with closure of tunica albuginea.	Strong
Explore the injured testis in all cases of testicular rupture and in those with inconclusive US findings.	Strong

This short booklet text is based on the more comprehensive EAU Guidelines (ISBN 978-94-92671-16-5) available to all members of the European Association of Urology at their website, <http://www.uroweb.org/guidelines>.