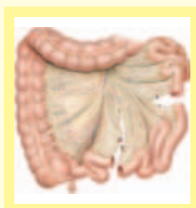


Surgery Illustrated



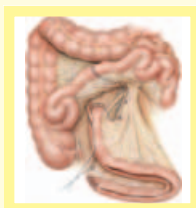Surgical Atlas

Orthotopic ileal neobladder

U.E. STUDER, C. VAROL and H. DANUSER

University of Bern, Department of Urology, Bern, Switzerland

ILLUSTRATIONS by STEPHAN SPITZER, www.spitzer-illustration.com



PLANNING AND PREPARATION

PATIENT SELECTION AND INDICATION

There are certain contraindications to constructing a bladder substitute. These are similar to those for a radical cystectomy indicated in bladder cancer, in that the exclusion of bone, lung and lymph node metastases, and establishment of operability, are essential. The presence of any major liver, renal or bowel insufficiency, or incontinence caused by urethral rhabdosphincter insufficiency necessitate using an alternative urinary diversion. In cases of bladder cancer, the concomitant presence of urethral cancer or preoperative paracollicular biopsies showing tumour at the future anastomotic margin are a definitive contraindication.

The most important factor that will determine the success of a bladder substitute is patient compliance with the long-term follow-up. Adequate physical dexterity and the mental capacity to understand their new bladder and how it functions are required. In the absence of these prerequisites, an alternative urinary diversion should be considered. The postoperative management of these patients is more important than the actual surgical construction if good long-term results are to be achieved.

PATIENT PREPARATION AND POSITIONING

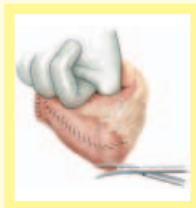
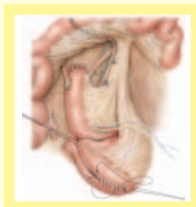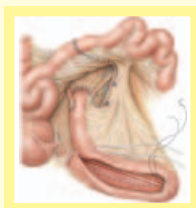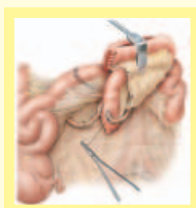
Preoperative bowel preparation with two high colonic enemas is sufficient. Subcutaneous

prophylaxis for deep vein thrombosis, started the evening before surgery, is given in the upper body to prevent postoperative pelvic lymphocele formation. Patients wear compression stockings and are mobilized on the day after surgery. Antibiotic prophylaxis with amoxycillin/clavulanic acid, aminoglycoside and metronidazole is started during surgery, the aminoglycoside/metronidazole continued for 48 h, and amoxycillin/clavulanic acid until all drains and catheters are removed.

Patients are shaved just before surgery and placed in a slight hyper-extended supine position. The instruments usually used for a cystectomy and ileal conduit formation are sufficient. An angled Babcock clamp is used for binding Santorini's plexus, with no additional instruments needed for creating the bladder substitution.

The suture materials are:

- 0 polyglycolic acid FSL for ligating the Santorini's plexus
- 0 polyglycolic acid UR-5 for oversewing Santorini's plexus
- 4-0 polyglycolic acid V-5 for anastomosing the ureters to the afferent tubular segment
- 4-0 polyglycolic acid RB-1 plus binding of the ureteric catheter to the ureter
- 2-0 polyglycolic acid SH for reservoir formation
- 2-0 polyglycolic acid UR-6 for urethral anastomosis

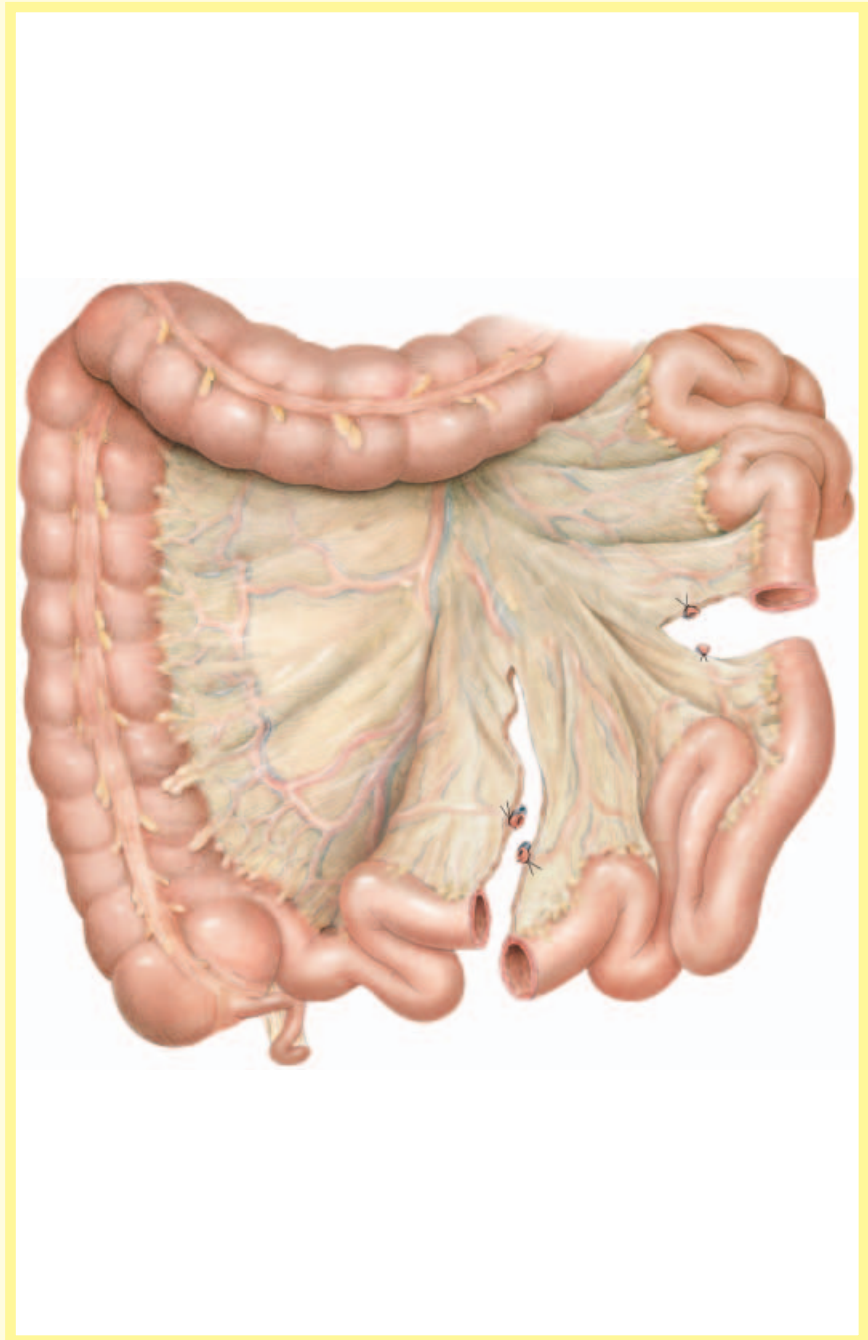


The planning and preparation checklist include:

- Patient agreement to indefinite follow-up
- Adequate mental state, dexterity and mobility
- A serum creatinine level of <150 mmol/L
- Adequate liver function
- Adequate bowel function
- No tumour in the distal urethra, paracollicular(male) or bladder neck (female) region
- Good continence status
- Deep vein thrombosis prophylaxis
- Antibiotic prophylaxis
- Hyperextended supine position

Figure 1

For constructing the reservoir an ileal segment ~54 cm long is isolated 25 cm proximal to the ileocaecal valve and bowel continuity restored with a 4-0 polyglycolic acid single-layer seromuscular running suture. The length of the ileum segment is measured with a ruler in portions of 10 or 15 cm along the border of the mesoileum without stretching the bowel. Irritation of the bowel and epidural anaesthesia with local anaesthetics should be avoided as this can increase smooth muscle tone and activity and 'shorten' the bowel, which will be too long after muscle relaxation. The distal mesoileum incision transects the main vessels, whereas the proximal mesoileum incision must be short to preserve the main vessels perfusing the future reservoir segment.



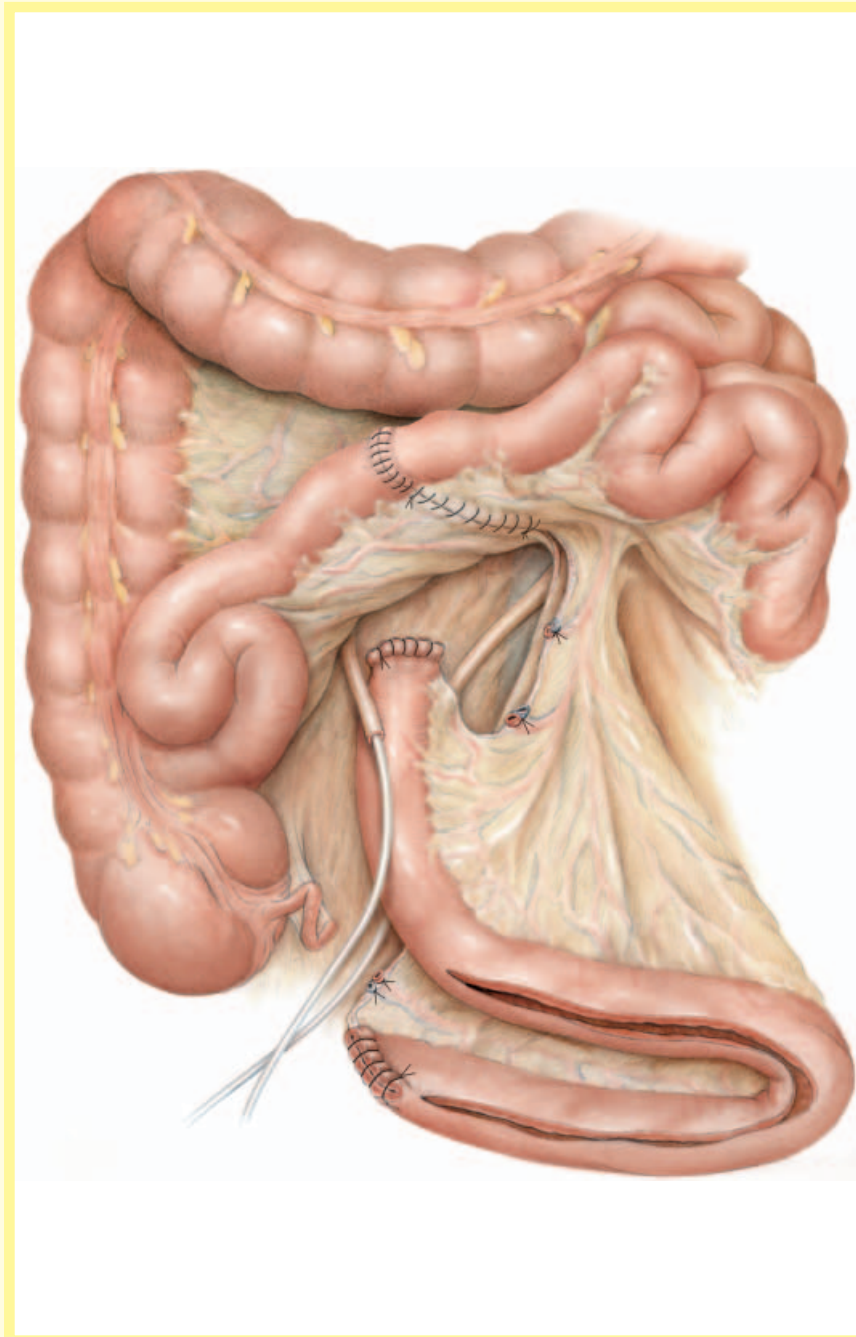
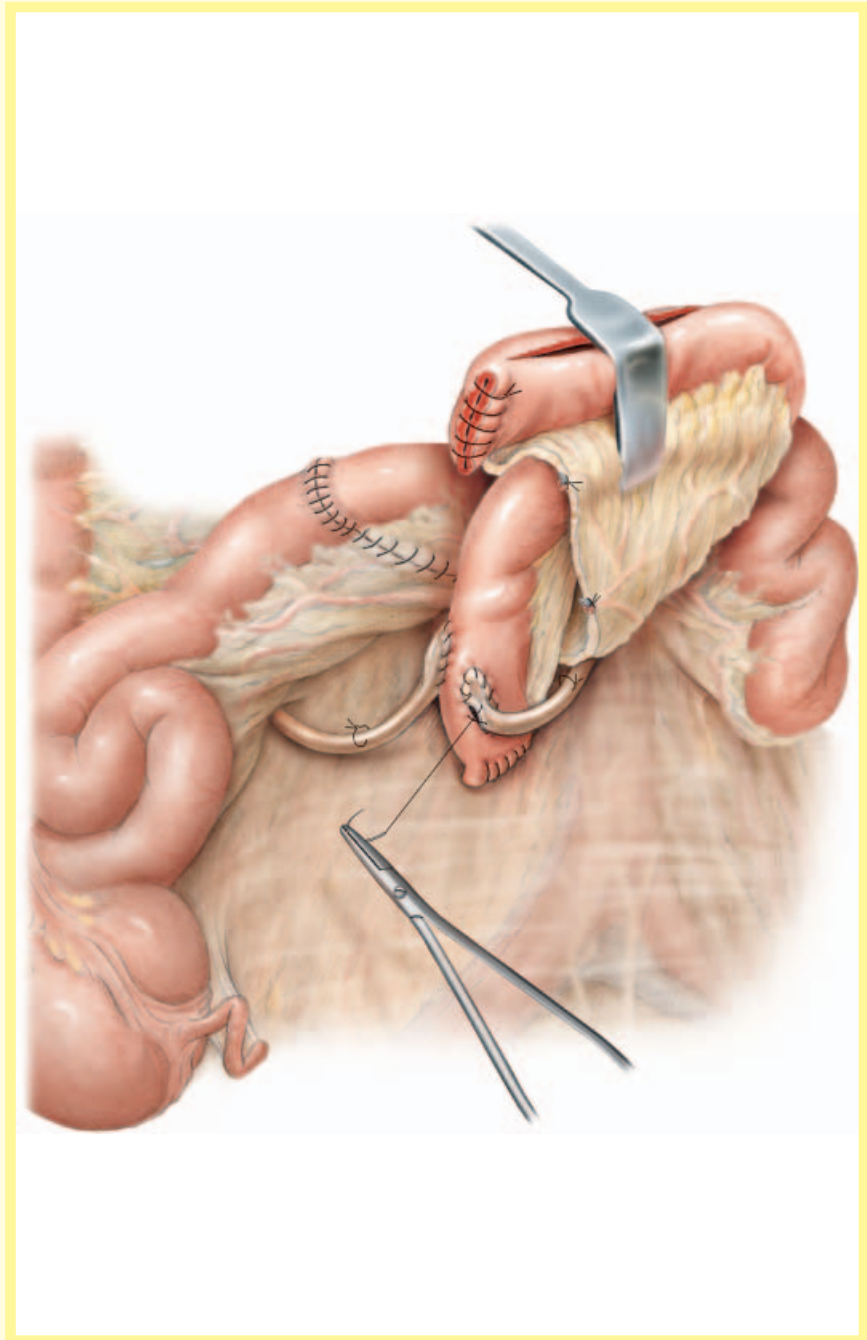


Figure 2

The mesoileum window is closed with a 2-0 polyglycolic acid running suture including the mesoileum of the bladder substitute. At the mesoileum of the bladder substitute the sutures must be applied superficially, taking care to preserve the blood supply. Both ends of the isolated ileal segment are closed by a single-layer 4-0 polyglycolic acid seromuscular running suture. The distal end of the ileal segment, 40-44 cm long, is opened along its antimesenteric border.

Figure 3

The ureters are spatulated over 1.5–2 cm and anastomosed by two 4–0 polyglycolic acid running sutures using the Nesbit technique. This is an end-to-side anastomosis to two longitudinal 1.5–2 cm long incisions along the paramedian antemesenteric border of the 12–14 cm long afferent tubular ileal segment. The ureters are stented with 7 F or 8 F catheters. To prevent dislocation of the catheters, a rapidly absorbable 4–0 polyglycolic acid suture is placed through both the ureter and catheter, 3–4 cm proximal to the anastomosis. This is tied very loosely in order not compromise the ureteric blood flow. The most distal peri-ureteric tissue is sutured to the afferent ileal segment to alleviate tension and to cover the anastomosis.



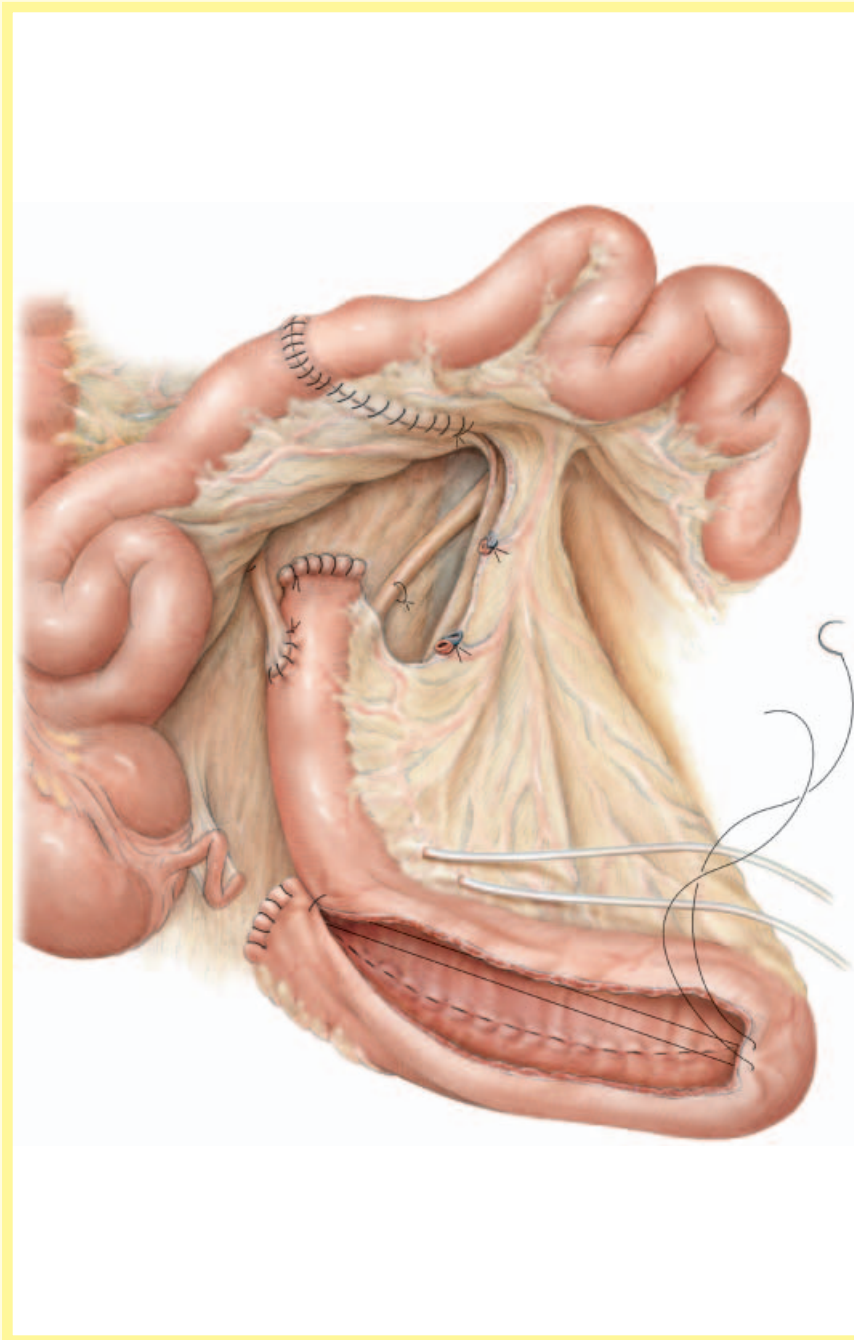
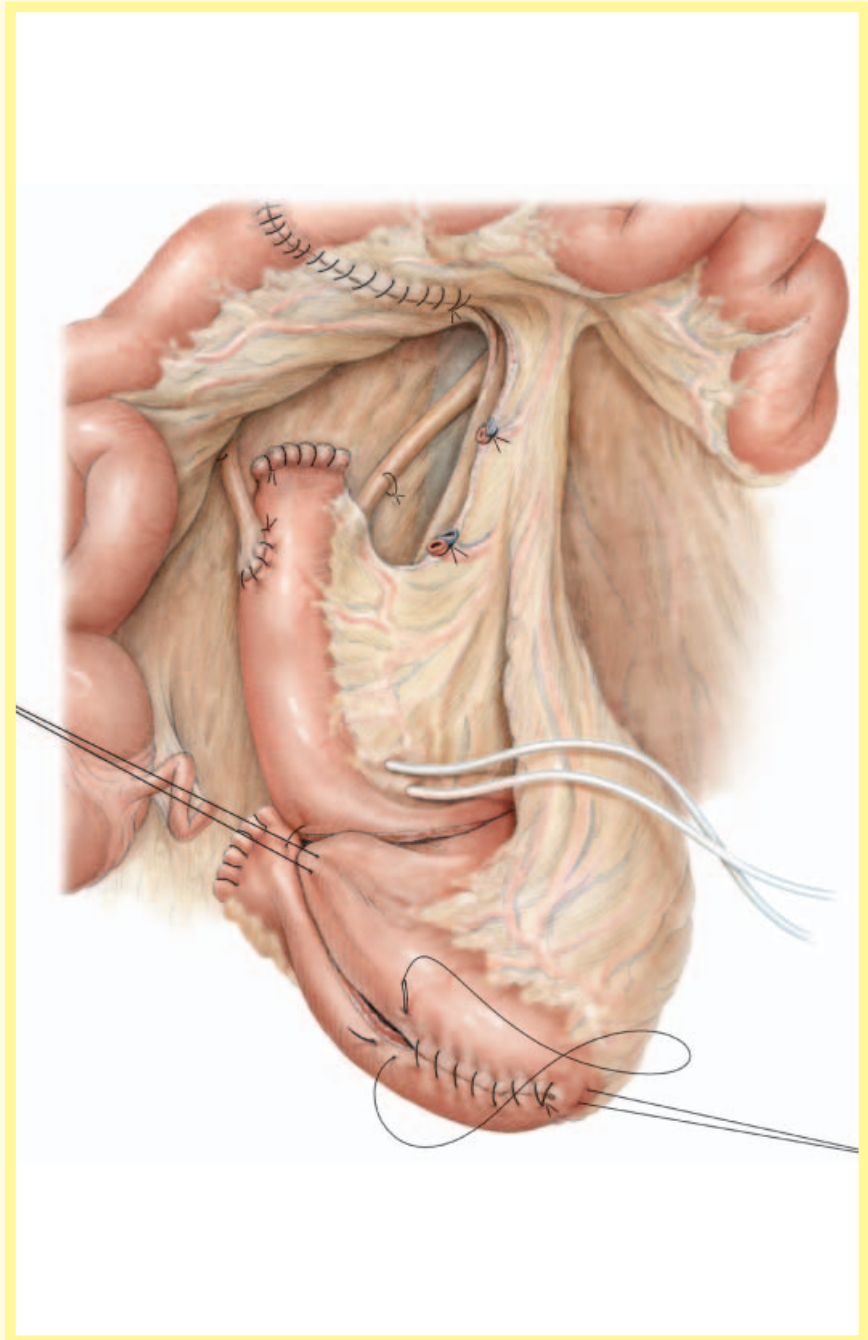


Figure 4

The ureteric catheters are passed through the wall of the most distal end of the afferent tubular segment, where it is covered by mesoileum. This provides a 'sealed' canal in the reservoir wall when the ureteric splints are sequentially removed at 5–8 days after surgery. To construct the reservoir itself the two medial borders of the opened U-shaped distal part of the ileal segment are oversewn with a single seromuscular layer, using 2–0 polyglycolic acid running suture.

Figure 5

The bottom of the U is folded over between the ends of the U, resulting in a spherical reservoir consisting of four cross-folded ileal segments.



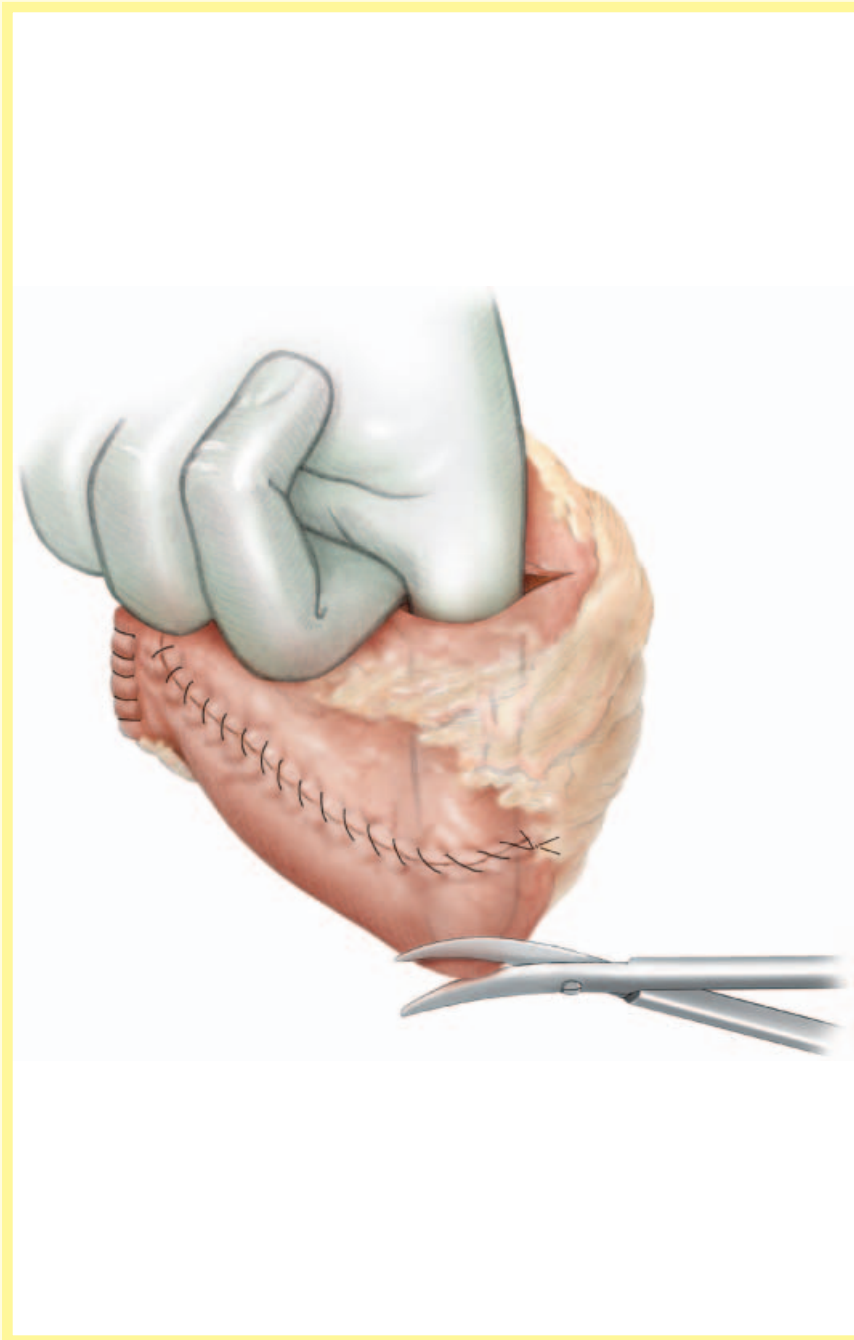
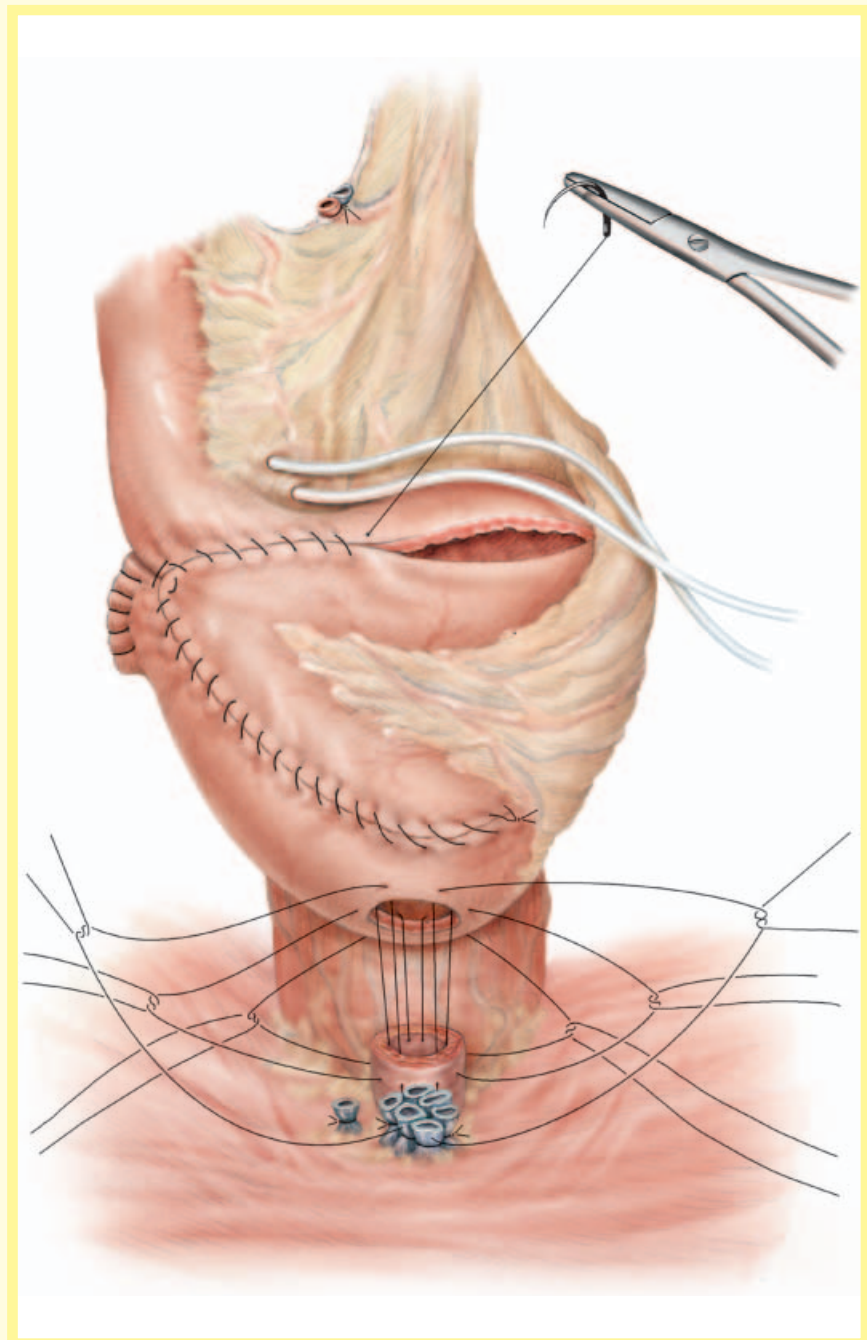


Figure 6

After closing the lower half of the anterior wall and part of the upper half, the surgeon's finger is introduced through the remaining opening to determine the most caudal part of the reservoir. A hole 8–10 mm in diameter is cut out of the pouch wall, outside the suture line, close to the mesoileum and 2–3 cm away from the edge that resulted from cross-folding the ileal segment. The outlet must be flat to the pelvic floor and not funnel-shaped, to prevent kinking.

Figure 7

Six 2-0 polyglycolic acid seromuscular sutures are placed between the hole in the reservoir and the edge of the membranous urethra. The two most posterior paramedian sutures are placed through Denonvilliers' fascia taking only 3-4 mm of the outer membranous urethra. The two most anterior sutures take very little of the urethra and pass through Santorini's plexus. The lateral two sutures take 3-4 mm of the outer urethra and only the edge of the mucosa. Placing the sutures through the edge of the intestinal and urethral mucosa assures perfect approximation, with good apposition of the seromuscularis of the reservoir to the sphincter muscle. This prevents interpositioning of intestinal mucosa between the muscle layers and thus diminishes the chance of anastomotic leakage. The tension of the anastomosis is taken up by Denonvilliers' fascia dorsally and the ligated Santorini's plexus ventrally. An 18 F urethral catheter is inserted before tying the six sutures, beginning with the most ventral sutures at the 1 and 11 o'clock position, followed by the sutures at the 3 and 9 o'clock position, and finally the two most dorsal sutures at the 5 and 7 o'clock position.



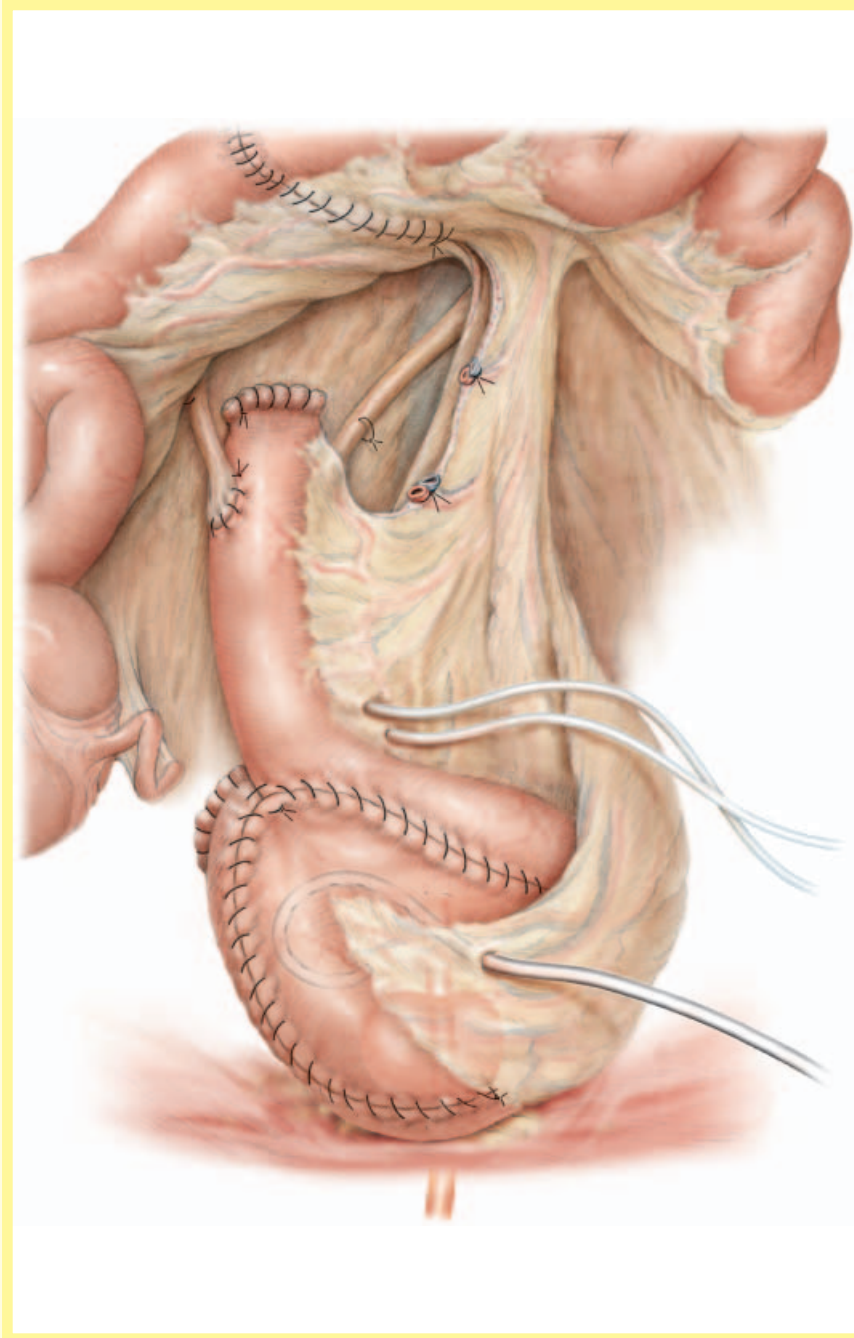


Figure 8

Before completely closing the pouch a 10 F cystostomy tube is placed into the reservoir through the fat of the mesoileum. The reservoir is flushed to remove any clots and checked for leakage.

POSTOPERATIVE CARE

The suprapubic and transurethral catheters need to be flushed and aspirated with saline 0.9% every 6 h to prevent any catheter blockages which may lead to rupture of the bladder substitute. This risk is highest when bowel activity returns and the transurethral catheter is still in-situ.

Total parenteral nutrition is commenced on the first day and stopped as soon as oral intake is established. To prevent abdominal bloating and assist bowel function, parasympathomimetic medications (e.g. neostigmine methylsulphate 3–6 × 0.5 mg subcutaneously) is started 3 days after surgery. The exteriorized ureteric catheters can also be manually irrigated if there is suspected blockage and ureteric obstruction. The ureteric catheters are removed sequentially at 5–8 days after surgery.

Exclusion of a leak with a pouchogram at 8–10 days allows removal of the suprapubic catheter. This is followed 48 h later by the urethral catheter, allowing for the puncture site from the suprapubic catheter in the bladder substitution to seal.

After catheter removal, the patient is at increased risk of a metabolic acidosis. Patients will complain of lethargy, fatigue, nausea, vomiting and anorexia associated with epigastric burning. The acidosis is monitored using the base excess estimated by venous blood gas analysis, initially every 2–3 days and later at greater intervals, depending on the blood gas values. The base excess needs to be corrected if it is negative. Virtually all patients will require sodium bicarbonate

treatment (2–6 g/day) which can be stopped 2–6 weeks later. A salt-losing syndrome by the bladder substitute can cause hypovolaemia, dehydration and a loss of body weight. Patients should therefore consume 2–3 L of fluids per day, which is supplemented with increased salt intake in their diet; body weight should also be monitored daily.

Voiding occurs initially while seated, every 2 h during the day and 3-h with the help of an alarm clock at night. Voiding occurs by relaxing the pelvic floor, followed by slight abdominal straining. This is aided by hand pressure on the lower abdomen and bending forwards. In-out catheterization is used once, together with suprapubic ultrasonography, and later the postvoid residual volume is checked only by ultrasonography. Any UTI or bacteriuria is treated. The voiding interval is increased stepwise from 2 to 4 h, in hourly steps, provided the findings from blood gas analysis are compensated. The patient has to prolong the interval to passively increase bladder capacity to a desired volume of 500 mL even if incontinent. With an increase in reservoir capacity it is easier for the patient to achieve continence. Laplace's law (pressure = tension/radius) states that the intravesical pressure will decrease with an increase in reservoir radius, resulting in a low-pressure system.

The time to recovering continence depends on surgical technique, with nerve preservation to the urethra and pelvic floor, good counselling with daily vigilant sphincter training, and the age of the patient. Effective sphincter training is taught by using a digital rectal examination and helping the patient to contract only the anal sphincter. The patient receives direct

feedback from the examiner about the adequacy of the contraction and is subsequently ensured of satisfactorily training the sphincter in the future. This comprises contraction 10 times/h, maintaining the contraction for 6 s and continued daily once continence is achieved.

DIFFICULTIES

The most challenging patients for a bladder substitution are those who are short and obese, with a narrow pelvis. In these cases the mesentery of the ileum that is being used for the bladder substitute is thick. Folding the ileal segment into a sphere can be difficult, but it is always possible. As the mesentery is also short in these patients the distance between the reservoir and the urethra can be longer than expected. To gain length and achieve a tension-free anastomosis, ensure that the distal mesentery is maximally incised without jeopardising any blood supply to the reservoir or the ileum. Careful superficial incisions (perpendicular to the mesenteric blood vessels) of the reservoir's mesenteric peritoneal surface will result in further lengthening. It is important to move the sigmoid colon or small bowel loops that may be present between the mesoileum of the reservoir and the sacral promontory before bringing the reservoir down to the urethra. The patient can also be straightened or slightly flexed at the pelvis to reduce the distance between the urethra and reservoir. To remove any tension on the reservoir-urethral anastomosis, two sutures between the reservoir and the pelvic floor can be placed lateral to the anastomosis. It should always be possible to construct a tension-free reservoir-urethral anastomosis.