available at www.sciencedirect.com
journal homepage: www.europeanurology.com

European Association of Urology

Surgery in Motion

Vattikuti Institute Prostatectomy: Contemporary Technique and Analysis of Results

Mani Menon *, *Alok Shrivastava, Sanjeev Kaul, Ketan K. Badani, Michael Fumo, Mahendra Bhandari, James O. Peabody*

Vattikuti Urology Institute, Henry Ford Health System, Detroit, MI, United States

Article info

Article history:
Accepted October 23, 2006
Published online ahead of print on November 3, 2006

Keywords:
Laparoscopy
Prostate cancer
Radical prostatectomy
Robotic

Abstract

Objectives: Contemporary techniques of radical prostatectomy achieve excellent oncologic outcomes; erectile dysfunction is the most common adverse effect. We have modified our technique of robotic radical prostatectomy (Vattikuti Institute prostatectomy [VIP]) in an attempt to minimize decrease of erectile function while maintaining the excellent oncologic outcomes achieved by the radical retropubic prostatectomy. We present our current technique of VIP with preservation of the lateral prostatic fascia (''veil of Aphrodite'').

Methods: A total of 2652 patients with localized carcinoma prostate underwent VIP. The salient features of our current technique are early transection of the bladder neck, preservation of the prostatic fascia, and control of the dorsal vein complex after dissection of the prostatic apex. Oncologic and functional outcomes were obtained through a questionnaire collected by a third party not involved in patient care.

Results: Complete follow-up information was obtained in 1142 patients with a minimum follow-up of 12 mo (range: 12–66 mo; median: 36 mo). The actuarial 5-yr biochemical recurrence rate was 8.4% and the actual biochemical recurrence rate was 2.3%. Median duration of incontinence was 4 wk; 0.8% patients had total incontinence at 12 mo. The intercourse rate was 93% in men with no preoperative erectile dysfunction undergoing veil nerve-sparing surgery, although only 51% returned to baseline function.

Conclusions: VIP with veil nerve sparing offers oncologic and continence results that are comparable to the results of conventional nerve-sparing radical prostatectomy. Early potency results are encouraging.

* Corresponding author. Case School of Medicine, The Raj and Padma Vattikuti Distinguished Chair and Director, Vattikuti Urology Institute, Henry Ford Health System, 2799 West Grand Blvd., Detroit, MI 48202, United States. Tel. +1 313 916 2066; Fax: +1 313 916 1462.
E-mail address: ashriva1@hfhs.org (M. Menon).

0302-2838/$ – see back matter doi:10.1016/j.eururo.2006.10.055

1. Introduction

Over several decades, open radical prostatectomy has developed into a refined surgical procedure, with excellent outcomes [1–3]. More recently several surgeons have developed minimally invasive surgical techniques for removing the prostate [4,5].

In 2000, we started a robot-assisted radical prostatectomy program. Our technique, the ''Vattikuti Institute prostatectomy'' (VIP) was implemented for the routine surgical care of patients with localized prostate cancer in 2001 [6,7] and has been adopted by others [8–10]. As of this writing we have performed >2600 robotic radical prostatectomy procedures. Our approach has evolved over the last 5 yr, during which time we have learned many lessons.

Because prostate cancer is being diagnosed earlier in the course of the disease, cancer cure rates have improved dramatically. A ''Trifecta'' analysis of outcomes following open radical prostatectomy has shown that erectile dysfunction is the most common adverse outcome that the patients sustain [11]. We have attempted to use the precision inherent in robotic surgery to develop enhanced techniques of potency preservation, without sacrificing cancer control. We found certain maneuvers helpful to us: approaching the bladder neck initially (first done in 2001), using a running suture for urethrovesical anastomosis (2001), and incising the prostatic fascia anterolaterally to release the nerves (2003). These techniques resulted in a decrease in operative times, of anastomotic leaks, and of erectile dysfunction, respectively. In 2004 (after >1000 cases!), we changed our technique of traction on the bladder neck and abandoned initial bulk ligation of the dorsal vein complex, in favor of precise suturing after urethral transection. These maneuvers made it easy to identify the bladder neck and resulted in a decrease in positive apical margins. Starting in 2002, we eliminated the use of monopolar cauterization after the transection of the seminal vesicle. In 2004, we stopped opening endopelvic fascia and started preserving the anterior fibromuscular stroma of the prostate in select patients with low-volume disease. We have not been able to detect a significant improvement in operative parameters or outcomes with these latter maneuvers. As we continually try to improve our technique, we despair that robotic radical prostatectomy, like golf, is easy to learn, but difficult to master. In this paper, we describe our current technique, early oncologic outcomes, and functional results.

2. Patients and methods

2.1. *Patient selection*

Although patient preference drives the decision to undergo surgery, we generally recommend that men with low prostate-specific antigen (PSA) levels and focal Gleason 6 cancer of the prostate undergo active monitoring with follow-up biopsies. We offer surgery for men with nonfocal Gleason 6 (30% of our patients), Gleason 7 (60%), and Gleason 8–9 cancer (10%). Patients with >25% Gleason 7 disease get conventional nerve-sparing surgery [1,2] on the ipsilateral side; all others get the veil nerve-sparing procedure [12].

2.2. *Technique of VIP*

2.2.1. *Patient positioning and port placement*

The patient is padded at pressure points and placed in the lithotomy position. Pneumoperitoneum is created and ports are placed; we use a six-port approach (Fig. 1). The table is then moved to a steep Trendelenburg position.

2.2.2. *Robotic instruments*

The operation can be done with either the 8-mm or 5-mm robotic instruments. We currently favor the latter. Our staples are the monopolar hook, the ''cold'' round tip scissors, a Maryland or triangular bipolar grasper, and a needle holder. In patients in whom nerve sparing is not contemplated, the scissors can be eliminated and the procedure can be done with three instruments, reducing the cost.

2.2.3. *Development of the extraperitoneal space*

The peritoneal cavity is inspected using the 30° upward-looking lens. A transverse peritoneal incision is made extending from the left to the right medial umbilical ligament; this incision is extended in an inverted U to the level of the vasa on either side. The space anterior to the peritoneum and space of Retzius is entered. The rest of the surgery is performed in this space anterior to the peritoneal reflection of the bladder and prostate.

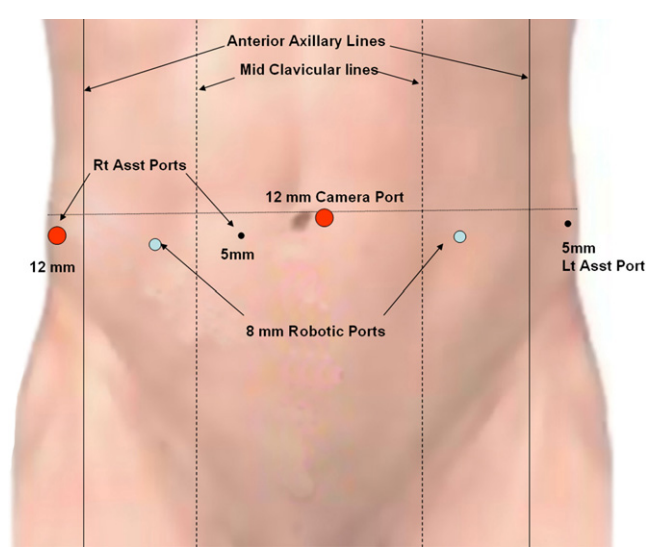

Fig. 1 – Port placement.

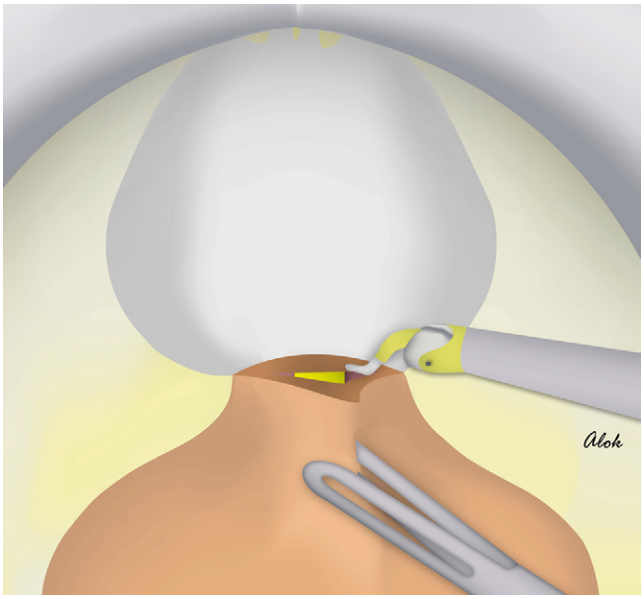

Fig. 2 – Incision of anterior detrusor wall at bladder neck.

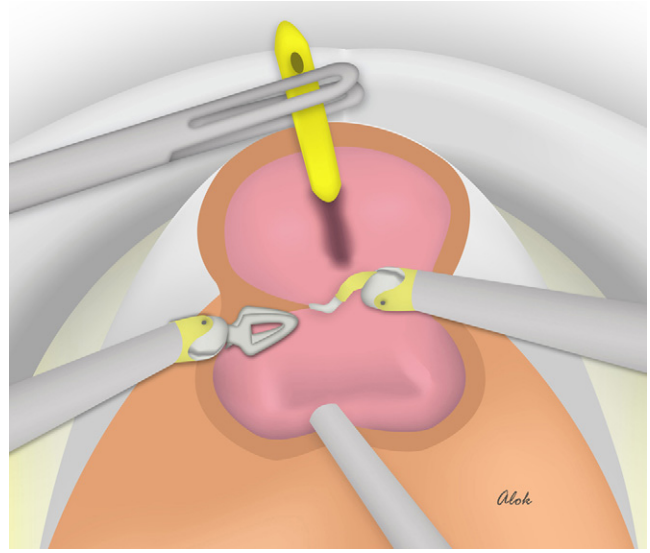

Fig. 3 – Incision of posterior detrusor wall at bladder neck.

2.2.4. *Lymph node dissection*

The tissue overlying the external iliac vein is incised and the lymph nodal package is pushed medially. The dissection is started at the lymph node of Cloquet at the femoral canal and continued proximally toward the bifurcation of iliac vessels. The obturator nerve lies on the floor of this dissection and is carefully preserved. In patients with Gleason 8–9 disease, the nodal package between the obturator nerve and the hypogastric vein is also removed.

2.2.5. *Bladder-neck transection*

We next approach the bladder neck directly, without opening endopelvic fascia or ligating the dorsal vein complex, a modification over our previously described technique [7]. This portion of the procedure is best done with a 30° lens looking down. The right assistant grasps the anterior bladder wall in the midline with an atraumatic grasper and lifts it directly toward the ceiling; the left assistant deflates the Foley balloon while keeping the catheter in the bladder. This simple maneuver aids in the identification of the bladder neck, as the bladder pulls away from the prostate excepting at the midline anterior to the catheter. A 1-cm incision is made in the anterior bladder neck at 12 o'clock, cutting down the detrusor to the expose the catheter in the midline (Fig. 2).

A detrusor apron may be seen on the anterior surface of the prostate [13]. The incision in the bladder neck is made immediately superior to the detrusor apron. After the anterior bladder neck is incised, the left-side assistant grasps the tip of the Foley catheter with firm anterior traction. This exposes the posterior bladder neck, which is incised (Fig. 3).

The posterior bladder neck is gradually dissected away from the prostate. The anterior layer of Denonvilliers fascia, covering the vasa and the seminal vesicles is now exposed. This layer is incised precisely, exposing the vasa and the seminal vesicles. The left-side assistant provides upward traction to the posterior base of the prostate to facilitate dissection of the vasa and seminal vesicles (Fig. 4).

First, the vasa are skeletonized and transected, then held upward by the left assistant providing further traction for dissection of the seminal vesicles (Fig. 5).The artery to the seminal vesicle is controlled by clipping or fine bipolar coagulation.

Both the vasa and seminal vesicles are then grasped and the posterior prostate is retracted upward, allowing exposure of posterior layer of the Denonvilliers fascia. An incision is made in this fascia and a plane is developed between the posterior layer of the Denonvilliers fascia and perirectal fat. This hypovascular plane can be created easily using blunt dissection (Fig. 6). The dissection is carried down to the apex of the prostate. This plane of dissection is extended laterally to expose the lateral pedicles of the prostate.

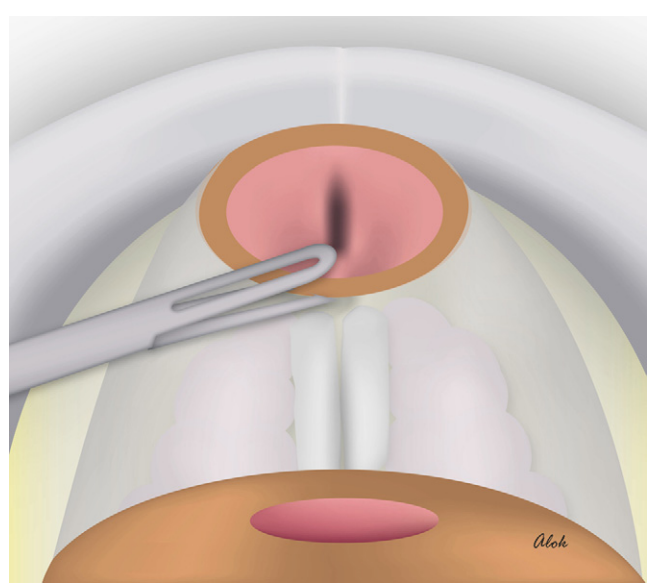

Fig. 4 – Exposure of anterior layer of Denonvilliers fascia.

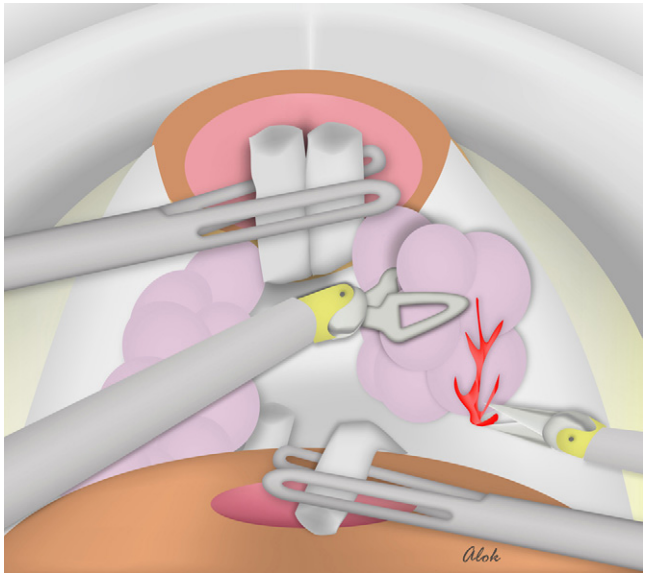

Fig. 5 – Dissection of left seminal vesicle.

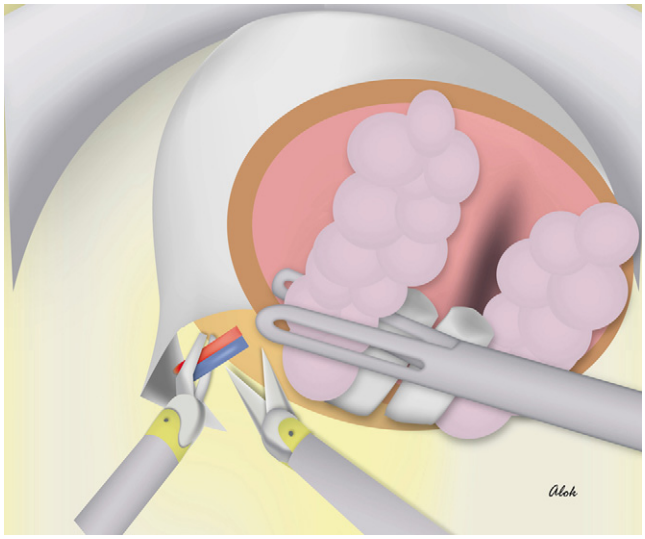

Fig. 7 – Control of right prostatic pedicle.

The base of the seminal vesicle is retracted superomedially by the assistant on the opposite side and the prostatic pedicle is delineated and divided. This pedicle lies anterior to the pelvic plexus and neurovascular bundle and includes only prostatic blood supply (Fig. 7). The pedicles are controlled by either clipping or individually coagulating the vessels by bipolar cauterization.

2.2.6. Nerve-sparing techniques: the "veil of Aphrodite"

Although the classical description of the neurovascular bundles is that of two bundles of tissue that are located near the posterolateral surface of the prostate [1], accumulating evidence indicates that this complex has a certain amount of variability. In some patients, rather than distinct neurovascular bundles, the cavernosal nerves form lattices or curtains that extend from the posterolateral to the anterolateral surface of the prostate [14–18]. To preserve these nerves, several surgeons [3,18] and we [12] have modified nerve-sparing techniques by incising the prostatic fascia anteriorly. We termed this approach, the "veil of Aphrodite" nerve-sparing technique (Aphrodite is the Greek goddess of love who causes strong men to fight over her); lately, others have called it "high anterior release, "curtain dissection," or "incremental nerve sparing. In the "veil" procedure we accomplish this through an antegrade approach. A plane between the prostatic capsule and the prostatic fascia is developed cranially, at the base of the seminal vesicles. With appropriate countertraction provided by the assistants, the surgeon is able to enter a plane between the prostatic fascia and the prostate. This plane is deep to the venous sinuses of the Santorini plexus. Careful sharp and blunt dissection of the neurovascular bundle and contiguous prostatic fascia is performed using the articulated "cold" scissors until the entire prostatic fascia up to the pubourethral ligament is mobilized in continuity. This plane is mostly avascular except anteriorly where the fascia is fused with the puboprostatic ligament and covers the dorsal venous plexus. When performed properly, curtains of periprostatic tissue hang from the pubourethral ligament, the veil of Aphrodite (Fig. 8).

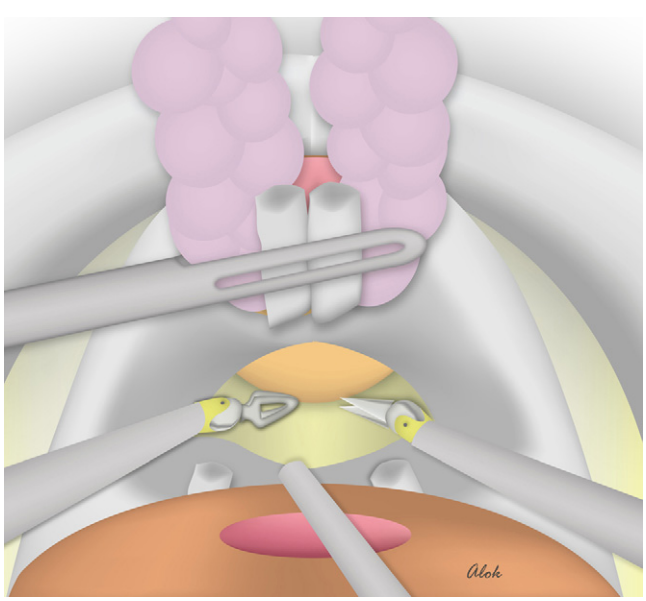

Fig. 6 – Incision in posterior layer of Denonvilliers fascia to expose perirectal fat.

If this plane is difficult to enter (as in patients with fibrosis after biopsy), it may be advantageous to perform part of the dissection retrograde and enter the plane of dissection on the anterolateral surface of the prostatic capsule at the 10- or 2-o'clock position.

2.2.7. Exposure of prostatic apex and control of dorsal venous complex

The prostatic apex is best visualized using the 0° lens; this is particularly useful in patients with an overhanging pubic symphysis. Once the lateral prostatic fascia is dissected off the prostatic apex, the right assistant retracts the prostate firmly

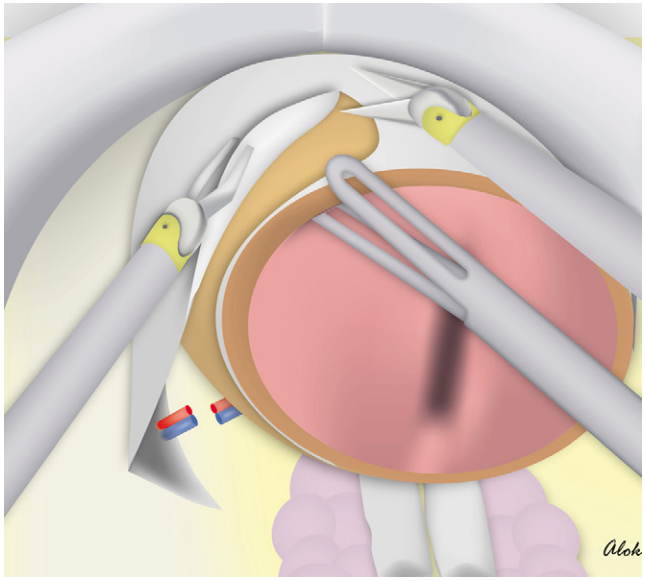

Fig. 8 – Plane of dissection for veil of Aphrodite.

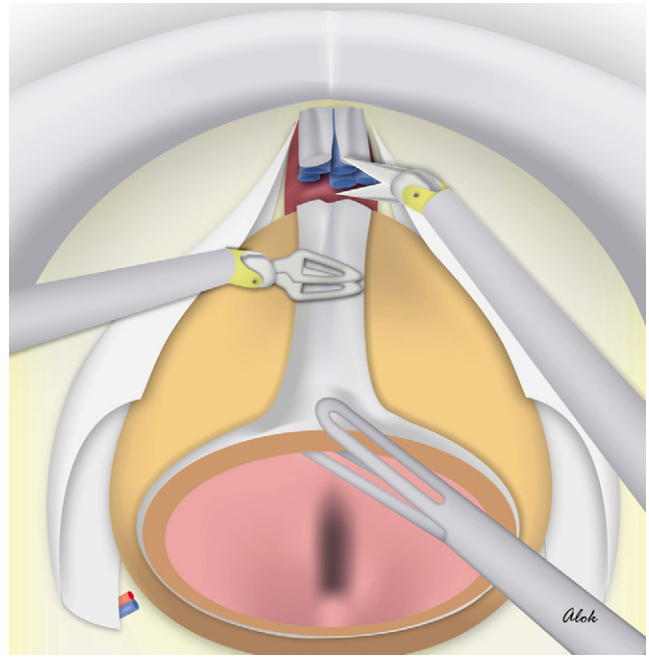

Fig. 9 – Transection of puboprostatic ligaments and dorsal venous complex.

to the patient's head. The puboprostatic ligament is incised with the cold scissors where it inserts into the apical prostatic notch (Fig. 9). It is important not to skeletonize the urethra, maintaining the fibrovascular support of the urethra intact hastens the return of continence. The cavernosal nerves are close to the urethra and are vulnerable to thermal or traction injury.

The urethra is then dissected into the prostatic notch and transected sharply 5 mm distal to the notch (Fig. 10). The freed specimen is placed in an Endopouch™ (Ethicon Endo-Surgery, Cincinnati, OH).

The dorsal venous complex is controlled with an over-running suture of 20 braided polyglactin on 17-mm taper-cut needle (Fig. 11). Depending on the amount of oozing from the dorsal vein complex, control is done before or after urethral transection.

2.2.8. *Urethrovesical anastomosis*

A running suture is used for the urethrovesical anastomosis. We use a minor modification of the technique described by Van Velthoven [19]. One dyed and one undyed 7-inch 3-0 monofilament polyglecaprone-25 sutures on 17-mm taper-cut needles are tied back to back. The suture is now double-armed with a pledget of the knots in the middle. We start with dyed arm, on the posterior bladder wall at the 4 o'clock position outside-in, continuing into the urethra at the corresponding site, inside-out. The dyed arm is run for two bites in the urethra and three in the bladder neck (Fig. 12A); the bladder is then cinched down to the urethra, with the right assistant "following" the suture. After the

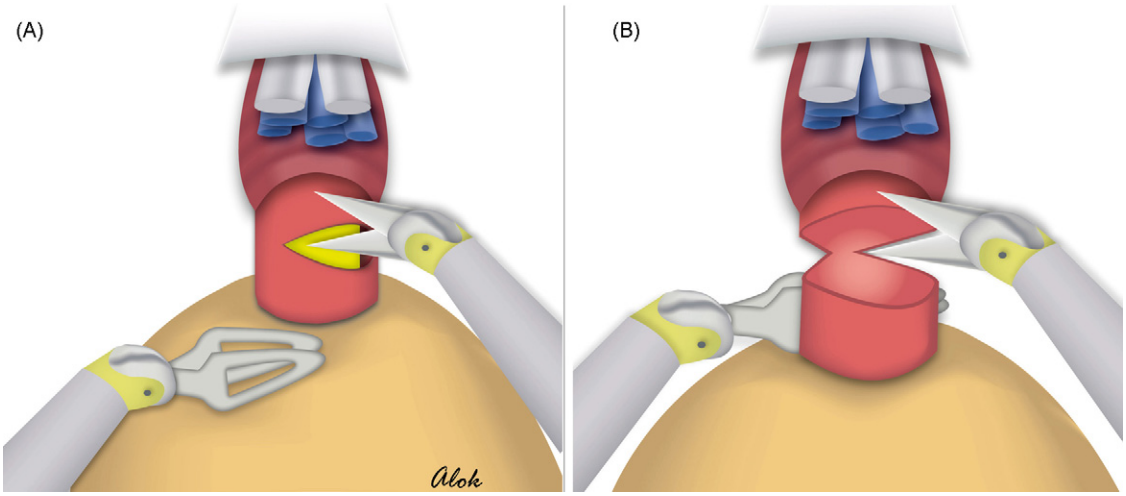

Fig. 10 – Urethral transaction. (A) Anterior urethral wall. (B) Posterior urethral wall.

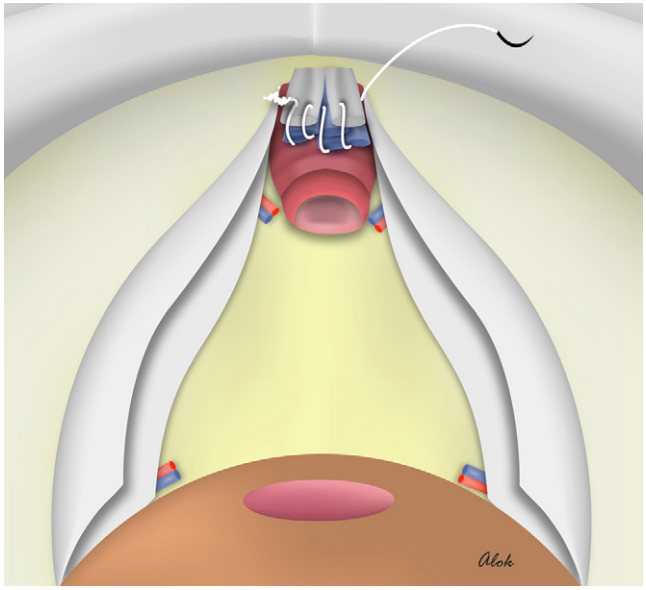

Fig. 11 – Control of dorsal venous complex and completed bilateral veil of Aphrodite after removal of specimen.

posterior urethral wall is approximated to the bladder neck in its entirety, the direction of the stitch is then changed to get passage of the needle from outside-in bladder to inside out (Fig. 12B). The suture is run clockwise up to 11 o'clock position and handed to the left assistant to hold with gentle, approximating traction. The undyed arm is then run counterclockwise from 4 o'clock to 11 o'clock (Fig. 12C). During the placement of anastomotic sutures the left assistant moves the tip of urethral Foley in and out of the urethral stump to prevent suturing of the back wall of urethra. Both arms of the suture are tied to each other to complete the anastomosis (Fig. 12D).

A new 20F Foley catheter is introduced and its balloon is inflated to 30 cc. The bladder is filled with 250 cc saline to test the integrity of the anastomosis.

2.2.9. *Retrieval of specimen and completion of surgery*

A Jackson-Pratt drain is placed through the left 5-mm port. The specimen is removed after enlarging the umbilical port incision as required. The incision is closed with interrupted sutures of 0 braided polyester. The skin is closed with subcuticular sutures.

2.3. *Postoperative care*

To minimize the urine spillage into the operating field, intravenous fluids are restricted to a minimum during the surgery. Patient who are clinically dehydrated receive a 1000-ml bolus of intravenous fluid in recovery room. Once the patient is out of the recovery room, he starts on clear liquid diet and advances to regular diet after a bowel movement. All patients are encouraged to ambulate within 4–6 h of arrival to a regular room. The Jackson-Pratt drain is removed on day 1 and patients are discharged within 24 h with an indwelling Foley catheter. The catheter is removed on day 4–7 under cystographic control.

2.4. *Data collection and analysis*

Operative data were collected prospectively in a customized database. Pathologic specimens were examined by one of several individual pathologists, with randomly selected specimens being reviewed by a referee pathologist. Patients were surveyed with a mailed-in questionnaire that included International Prostate Symptom Score (IPSS) and Sexual Health Inventory for Men (SHIM) scoring sheets, and questions about pad usage and duration of incontinence. Non-responders were sent a follow-up questionnaire. A third party not involved in direct patient care collected the data. The data were entered into

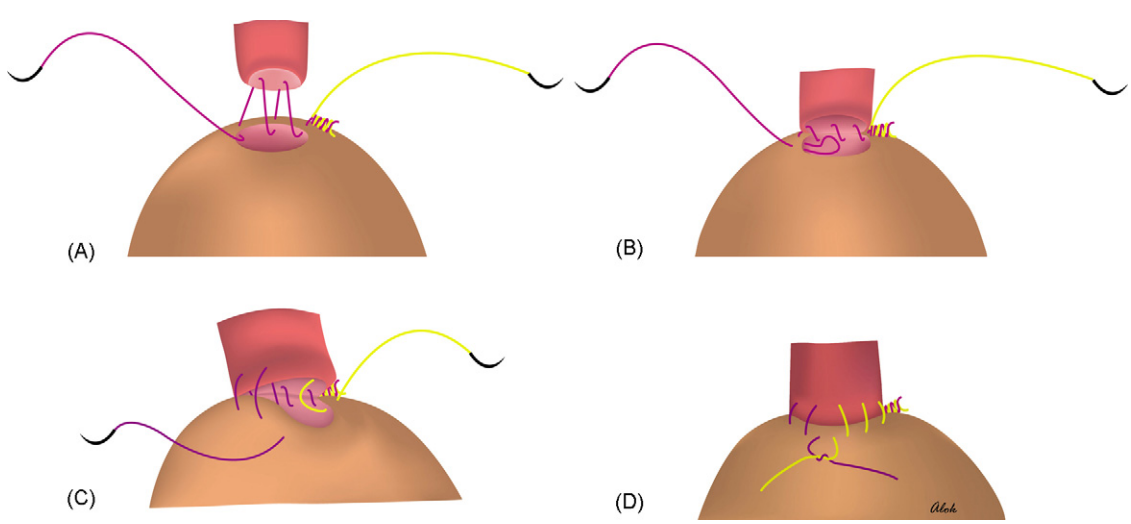

Fig. 12 – Urethrovesical anastomosis. (A) Posterior wall with anti-clockwise dyed Monocryl arm of suture. (B) Change of direction of needle passage at transition of anterior and posterior walls. (C) Clockwise stitches with undyed Monocryl arm of suture. (D) Completion of anastomosis.

an Access™ (Microsoft, Redmond, WA) database and analyzed with an SPSS™ (SPSS, Chicago, IL) statistical software package.

3. Results

3.1. Preoperative and operative parameters

From March 2001 to September 2006, we have operated on 2652 patients, 2582 at our own institution. Preoperative and operative parameters are detailed in Table 1. In keeping with our philosophy, patients in this series had higher grade disease (66% > Gleason 6) than those in many contemporary studies on radical prostatectomy.

Table 1 – Preoperative and operative parameters

Age, yr, mean (range)	60.2 (39–80)
Body mass index, kg/m^2, mean (range)	27.6 (19–44)
Clinical stage	
T1c	77.6%
T2a/b	22.0%
T3	0.4%
D'Amico risk	
Low	69.1%
Intermediate	22.7%
High	8.2%
Prior abdominal surgery	30.1%
Operative time, min	
Mean (range)	154 (71–387)
Median	148
Console time, min	
Mean (range)	116 (45–331)
Median	111
Estimated blood loss, ml	
Mean (range)	142 (10–750)
Median	100
No. of intraoperative blood transfusions	0
Pathologic stage	
T2a/b/c	77.7%
T3a	16.9%
T3b	5.1%
T4	0.3%
Pathologic Gleason score	
6	34.6%
7	54.1%
8	5.1%
9	6.2%
Hospital stay, d, mean (range)	1.14 (1–18)
Postoperative complications	
No complications	97.7%
Clavien I	1.5%
Clavien II	0.8%
Clavien III	0
Clavien IV	0
Positive margins	13%
Prostate weight, g, mean (range)	49.91 (13–220)
Percentage tumor volume	
Mean (range)	17.2 (1–90)

The average operative time decreased from 195 min in the first 100 patients to 131 min in the last 100 patients and robotic console time decreased from 165 min to 92 min, respectively. This decrease in times was noted despite progressively increasing house staff participation and surgical complexity (greater use of veil nerve sparing), suggesting an efficient transfer of skills. The positive margin rate at the apex was 12% for the first 100 cases [20]. When initial bulk ligation of the dorsal vein complex was replaced with suture ligation of the individual vessels after removal of the prostate, the apical margin rate decreased to 1.5% in patients with T2 disease. Only 0.8% patients had Clavien grade 2 [21] postoperative complications requiring any surgical intervention.

3.2. Biochemical recurrence

Many of the patients were from outside our geographic area and are followed locally. Complete follow-up data were obtained at our institution for 1142 patients with a minimum follow-up of 12 mo (range: 12–66 mo). The median follow-up in these patients is 36 mo, and so these results must be considered early. Nonetheless, they represent the longest follow-up available in patients undergoing robotic prostatectomy anywhere. Twenty-six patients (2.3%) had a biochemical recurrence [22]. The predicted PSA recurrence rate at 5 yr was 8.4% (Fig. 13). On multivariate analysis, preoperative PSA and pathologic Gleason score but not biopsy Gleason score, tumor volume, or margin status were independent predictors of PSA recurrence. Patients with pathologic Gleason score of 6 had an actuarial recurrence rate of 1.5% at 5 yr, patients with Gleason score 7 had a recurrence rate of 4.6%, and those with scores of 8 and 9 had a recurrence rate of 39.9%.

3.3. Return of continence

At 12 mo of follow-up, 33% of patients reported a >3-point improvement in IPSS scores compared to baseline, whereas 5% reported a decline. Of these, 84% had total urinary control and 8% used a liner for security reasons or for occasional stress incontinence (Table 2). A total of 95.2% of patients were socially dry as defined by use of one pad or less per day. Of patients who were totally dry, 25% were dry within 24 h of catheter removal, 50% were dry within 4 wk (median duration of incontinence), and 90%

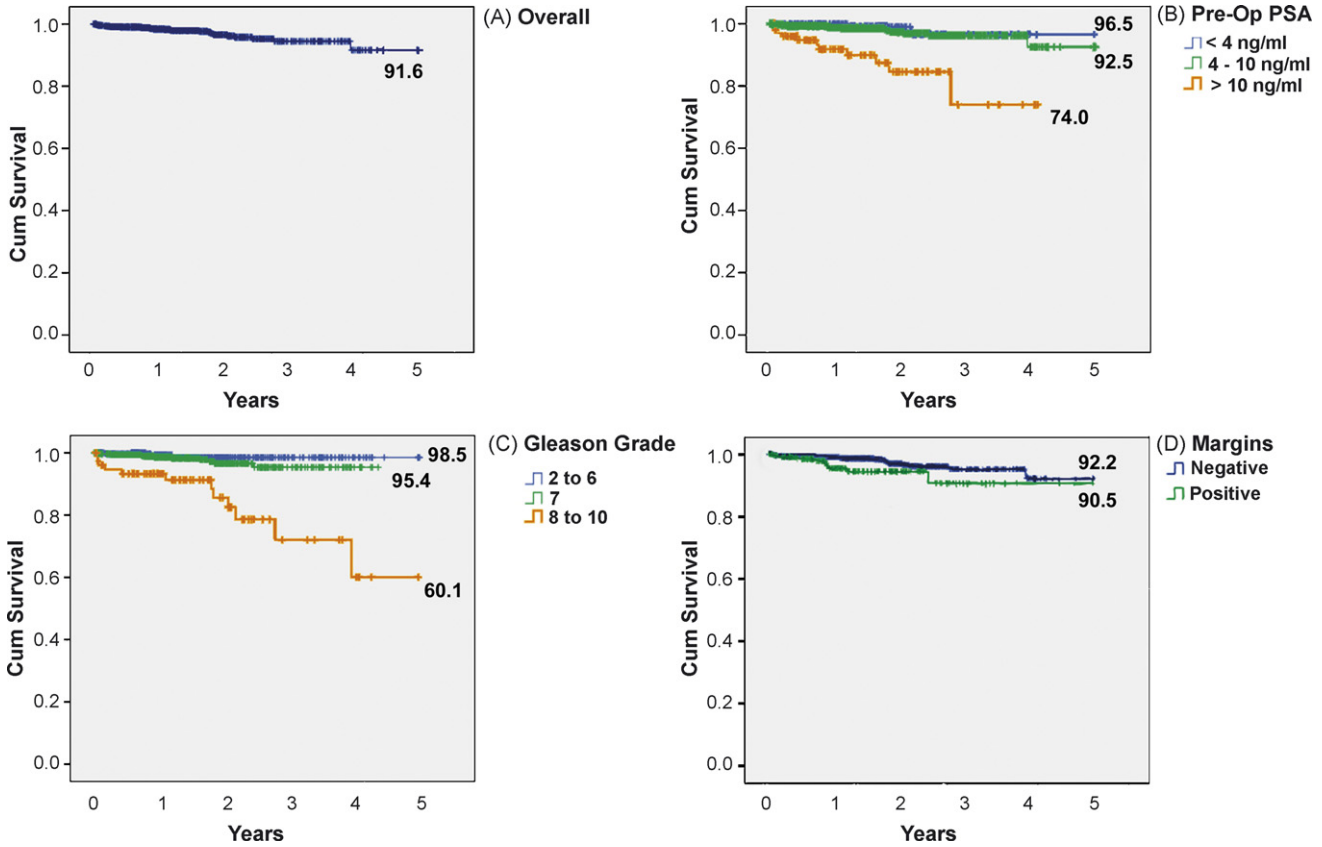

Fig. 13 – Biochemical recurrence-free survival in 1142 patients.

within 3 mo. Less than 1% of patients reported total urinary incontinence and four, including one patient who had a salvage robotic prostatectomy after failed brachytherapy (0.4%), had undergone placement of an artificial urinary sphincter. The median time to achieve urinary control appeared to be shorter in patients undergoing robotic surgery, but the overall continence rates at 12 mo are comparable to those reported in patients undergoing open radical prostatectomy [2,3].

3.4. *Return of potency*

Forty-two percent of patients underwent standard nerve sparing on both sides. Twenty-five percent of patients had a unilateral veil with contralateral standard nerve sparing. Thirty-three percent of patients underwent a bilateral nerve-sparing operation. Patients undergoing bilateral veils had significantly better return of potency than patients with conventional nerve-sparing surgery (Fig. 14). In patients with no preoperative erectile dysfunction (SHIM > 21), intercourse was reported in 70% and 100% of the patients undergoing bilateral veil nerve-sparing surgery at 12 and 48 mo of follow-up, respectively, although only half of these patients attained normal SHIM score without medication.

Table 2 – Return of continence in 12 mo

No urinary leak (total control)	84%
Liner for security (stress incontinence about once a week)	8%
1 pad/d (occasional stress incontinence)	3.2%
2–3 pads/d (frequent stress incontinence)	4%
Total incontinence	0.8%

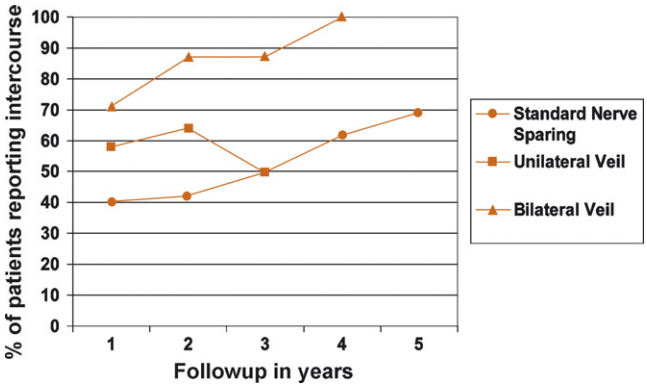

Fig. 14 – Return of potency in patients with normal preoperative potency.

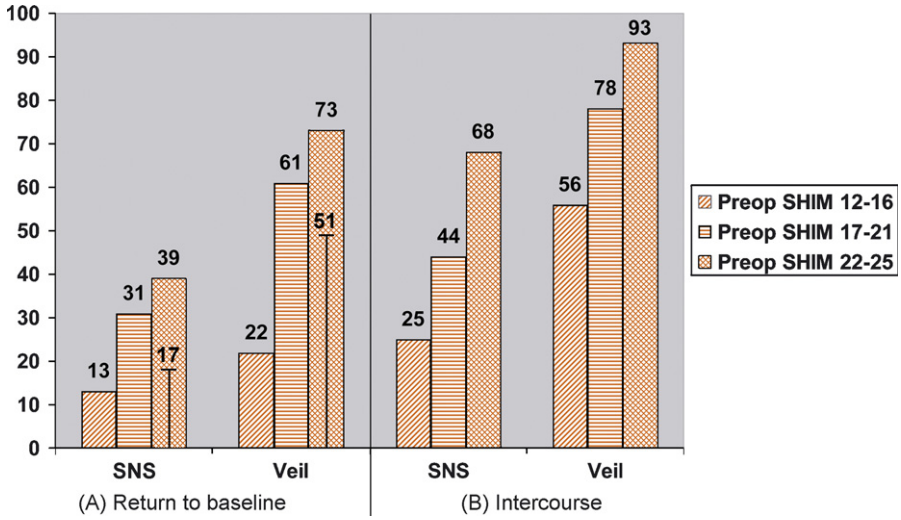

Fig. 15 – Postoperative return of potency in patients with various levels of preoperative erectile dysfunction (the line inside the bars represents the percentage of patients not receiving postoperative phosphodiesterase 5 inhibitors).

Fig. 15 shows postoperative potency rates in patients with no, mild, and moderate erectile dysfunction preoperatively. Because patients with preoperative erectile dysfunction are included in this analysis, outcomes are measured as return to baseline function and not as return to normal erections. As expected, potency rates were higher in patients who had no erectile dysfunction preoperatively. This trend was seen in patients undergoing both standard or veil nerve-sparing procedures. The figure demonstrates that at all levels of preoperative erectile function, patients undergoing a veil nerve-sparing procedure had better potency outcomes than patients undergoing conventional nerve-sparing prostatectomy.

4. Summary

Radical retropubic prostatectomy has evolved over the last three decades to a precise, sophisticated procedure with minimal mortality and excellent surgical outcomes. Our own experience suggests that equally good results can be obtained with robotic assistance. Our VIP technique continues to evolve with experience, much as ''open'' radical prostatectomy does. In our hands, the veil nerve-sparing procedure offers superior erectile function compared with conventional nerve-sparing surgery without compromising cancer control. It is our preferred technique in potent men with low or moderately aggressive prostate cancer. However, our results are far from perfect. Alas, robotic radical prostatectomy still awaits its Tiger Woods.

Conflicts of interest

The authors have nothing to disclose.

Appendix A. Supplementary data

Supplementary data associated with this article can be found, in the online version, at doi:10.1016/j.eururo.2006.10.055 and via www.europeanurology.com. Subscribers to the printed journal will find the supplementary data attached (DVD).

References

[1] Walsh PC, Lepor H, Eggleston JC. Radical prostatectomy with preservation of sexual function: anatomical and pathological considerations. Prostate 1983;4:473–85.
[2] Walsh PC, Marschke P, Ricker D, Burnett AL. Patient-reported urinary continence and sexual function after anatomic radical prostatectomy. Urology 2000;55:58–61.
[3] Graefen M, Walz J, Huland H. Open retropubic nerve-sparing radical prostatectomy. Eur Urol 2006;49:38–48.
[4] Abbou CC, Salomon L, Hoznek A, et al. Laparoscopic radical prostatectomy: preliminary results. Urology 2000;55:630–4.
[5] Guillonneau B, Vallancien G. Laparoscopic radical prostatectomy: the Montsouris technique. J Urol 2000;163:1643–9.
[6] Menon M, Shrivastava A, Tewari A, et al. Laparoscopic and robot assisted radical prostatectomy: establishment of a structured program and preliminary analysis of outcomes. J Urol 2002;168:945–9.
[7] Menon M, Tewari A, Peabody J. Vattikuti Institute prostatectomy team: Vattikuti Institute prostatectomy: technique. J Urol 2003;169:2289–92.

[8] Ahlering TE, Skarecky D, Lee D, Clayman RV. Successful transfer of open surgical skills to a laparoscopic environment using a robotic interface: initial experience with laparoscopic radical prostatectomy. J Urol 2003;170:1738–41.
[9] Patel VR, Tully AS, Holmes R, Lindsay J. Robotic radical prostatectomy in the community setting—the learning curve and beyond: initial 200 cases. J Urol 2005;174: 269–72.
[10] Smith Jr JA. Robotically assisted laparoscopic prostatectomy: an assessment of its contemporary role in the surgical management of localized prostate cancer. Am J Surg 2004;188:63S–7S.
[11] Saranchuk JW, Kattan MW, Elkin E, et al. Achieving optimal outcomes after radical prostatectomy. J Clin Oncol 2005;23:4146–51.
[12] Kaul S, Bhandari A, Hemal A, et al. Robotic radical prostatectomy with preservation of the prostatic fascia: a feasibility study. Urology 2005;66:1261–5.
[13] Myers RP. Detrusor apron, associated vascular plexus, and avascular plane: relevance to radical retropubic prostatectomy—anatomic and surgical commentary. Urology 2002;59:472–9.
[14] Tewari A, Peabody JO, Fischer M, et al. An operative and anatomic study to help in nerve sparing during laparoscopic and robotic radical prostatectomy. Eur Urol 2003;43:44454.
[15] Takenaka A, Murakami G, Soga H, et al. Anatomical analysis of the neurovascular bundle supplying penile cavernous tissue to ensure a reliable nerve graft after radical prostatectomy. J Urol 2004;172:1032–5.
[16] Costello AJ, Brooks M, Cole OJ. Anatomical studies of the neurovascular bundle and cavernosal nerves. BJU Int 2004;94:1071–6.
[17] Kiyoshima K, Yokomizo A, Yoshida T, et al. Anatomical features of periprostatic tissue and its surroundings: a histological analysis of 79 radical retropubic prostatectomy specimens. Jpn J Clin Oncol 2004;34:463–8.
[18] Lunacek A, Schwentner C, Fritsch H, Bartsch G, Strasser H. Anatomical radical retropubic prostatectomy: 'curtain dissection' of the neurovascular bundle. BJU Int 2005;95:1226–31.
[19] Van Velthoven RF, Ahlering TE, Peltier A, Skarecky DW, Clayman RV. Technique for laparoscopic running urethrovesical anastomosis: the single knot method. Urology 2003;61:699–702.
[20] Menon M, Shrivastava A, Sarle R, Hemal A, Tewari A. Vattikuti Institute prostatectomy: a single-team experience of 100 cases. J Endourol 2003;17:785–90.
[21] Clavien PA, Sanabria JR, Strasberg SM. Proposed classification of complications of surgery with examples of utility in cholecystectomy. Surgery 1992;111:518–26.
[22] Stephenson AJ, Kattan MW, Eastham JA, et al. Defining biochemical recurrence of prostate cancer after radical prostatectomy: a proposal for a standardized definition. J Clin Oncol 2006;24:3973–8.

Editorial Comment

Markus Graefen, Hartwig Huland, *Martini-Clinic, Prostate Cancer Centre, University Hospital Hamburg-Eppendorf, Martinistr. 52, 20246 Hamburg, Germany*
graefen@uke.uni-hamburg.de

In this paper, the development of surgical technique and outcome of robotic radical prostatectomy (RP) is demonstrated. With the inclusion of the data from >2500 patients, this is the largest cohort reported in the literature so far.

The data presented are excellent and in line with results reported by experienced open retropubic prostatectomy series [1,2]. We therefore can state today that besides open retropubic prostatectomy, perineal prostatectomy, and conventional laparoscopic prostatectomy another surgical approach is on the way to develop to an additional established method to excise a cancerous prostate.

Should we all train on the robot now? I do not think that this is necessary. Even though this is a large series the reported data definitely need to be reproduced by other groups. The reported "veil technique" has previously been published by several other surgeons under less prosaic descriptions [2,3]. In my opinion, the described high anterior release of the neurovascular bundles should be the standard technique of nerve-sparing procedures today because solid anatomic evidence indicates that a substantial number of nerve fibres are located anterior-lateral in the apical and midpart of the prostate [4,5]. Yet, considering this anatomic principle is independent of whether the surgical approach is open, conventional laparoscopic, or robotic assisted.

Furthermore, there is no evidence in the literature that in RP a laparoscopic approach is less invasive than an open or perineal approach [6]. The potential advantages of robotic surgery, which are magnification, three-dimensional vision, and the degree of freedom in moving the instruments, are similar to those achieved in modern open series by headlight, magnification loops, etc.

We have to wait to see how the various surgical approaches will develop in the future. As Dr Menon mentioned, the robotic RP is developing rapidly and we know that instruments, standardisation of the procedure, and experience of the surgeons will lead to even better results in the upcoming years. Nevertheless, this progression is not restricted to robotic RP alone but to all surgical approaches of RP. It is important that we seriously obtain our data to make the future results of various techniques comparable and reliable. We have to

be careful not to follow the temptation of misusing new techniques for marketing reasons. At least for the German situation, I am skeptical whether the robotic approach will offer advantages over other techniques that will make health insurers feel compelled to cover the tremendous extra costs of this procedure.

If you have followed our ''Surgery in Motion'' series you could see that several contributions on RP are published showing amazing progress for all approaches. We strongly believe that the ''competition'' among the various techniques is a continuous motivation for all of us to not stand still but to constantly improve on what we are doing. Finally, we are convinced that the most important factor for oncologic and functional outcome after RP is the experience of the surgical team rather than the surgical approach.

References

[1] Walsh PC, Marschke P, Ricker D, et al. Patient-reported urinary continence and sexual function after anatomic radical prostatectomy. Urology 2000;55:58–61.

[2] Graefen M, Walz J, Huland H. Open retropubic nerve-sparing radical prostatectomy. Eur Urol 2006;49:38–48.

[3] Lunacek A, Schwentner C, Fritsch H, et al. Anatomical radical retropubic prostatectomy: 'curtain dissection' of the neurovascular bundle. BJU Int 2005;95:1226–31.

[4] Costello AJ, Brooks M, Cole OJ. Anatomical studies of the neurovascular bundle and cavernosal nerves. BJU Int 2004;94:1071–6.

[5] Eichelberg C, Erbersdobler A, Michl U, et al. Nerve distribution along the prostatic capsule. Eur Urol 2007; 51:105–11.

[6] Fornara P, Zacharias M. Minimal invasiveness of laparoscopic radical prostatectomy: reality or dream? Aktuelle Urol 2004;35:395–405.