Considering the role of radical prostatectomy in 21st century prostate cancer care

Anthony J. Costello

Abstract | The practice of radical prostatectomy for treating prostate cancer has evolved remarkably since its general introduction around 1900. Initially described using a perineal approach, the procedure was later popularized using a retropubic one, after it was first described as such in 1948. The open surgical method has now largely been abandoned in favour of the minimally invasive robot-assisted method, which was first described in 2000. Until 1980, the procedure was hazardous, often accompanied by massive blood loss and poor outcomes. For patients in whom surgery is indicated, prostatectomy is increasingly being used as the first step in a multitherapeutic approach in advanced local, and even early metastatic, disease. However, contemporary molecular insights have enabled many men to safely avoid surgical intervention when the disease is phenotypically indolent and use of active surveillance programmes continues to expand worldwide. In 2020, surgery is not recommended in those men with low-grade, low-volume Gleason 6 prostate cancer; previously these men — a large cohort of ~40% of men with newly diagnosed prostate cancer — were offered surgery in large numbers, with little clinical benefit and considerable adverse effects. Radical prostatectomy is appropriate for men with intermediate-risk and high-risk disease (Gleason score 7–9 or Grade Groups 2–5) in whom radical prostatectomy prevents further metastatic seeding of potentially lethal clones of prostate cancer cells. Small series have suggested that it might be appropriate to offer radical prostatectomy to men presenting with small metastatic burden (nodal and or bone) as part of a multimodal therapeutic approach. Furthermore, surgical treatment of prostate cancer has been reported in cohorts of octogenarian men in good health with minimal comorbidities, when 20 years ago such men were rarely treated surgically even when diagnosed with localized high-risk disease. As medical therapies for prostate cancer continue to increase, the use of surgery might seem to be less relevant; however, the changing demographics of prostate cancer means that radical prostatectomy remains an important and useful option in many men, with a changing indication.

The use of radical prostatectomy to treat prostate cancer began in 1905, when Hugh Hampton Young published the first major description of the procedure, via a perineal approach, in *Annals of Surgery*[1,2] (FIG. 1). Young's technique was popular for the first half of the 20th century, until 1948, when Millin refined and popularized the operation using an abdominal incision from umbilicus to pubis into the extraperitoneal space. Eventually, the retropubic approach, which made the operation considerably safer, was developed by Walsh[3]. As Young's perineal approach was used in an era before antibiotics, balloon catheters and blood transfusion, it was associated with complications including infection, blood loss and urinary extravasation, as described in the 1938 edition of Bailey and Love, which quoted severe operative morbidity, including rectal fistulae, and which reported that 10% of patients died in hospital after undergoing Young's operation[4,5].

The Millin retropubic approach was further vastly improved and popularized by Walsh in the 1980s[6]. However, up until 1984, use of the Millin retropubic technique was usually associated with severe blood loss from the dorsal venous complex, which was cut but not tied, as the technique of ligation had not yet been universally adopted. Instead, a balloon catheter was used to tamponade the vein and this was left in traction for 2–3 days. This traction also compressed or crushed the skeletal muscle of the striated sphincter, causing ischaemia of the sphincter and increased risk of postoperative urinary incontinence[7]. A technique of pubic bone resection was described in 1987 in an attempt to improve access to the urethra for the anastomosis between bladder neck and urethra after prostatic removal[8]. However, this modification was abandoned after Walsh described his technique of haemostasis and surgeons slowly adopted this manoeuvre instead. Pubic bone resection did not help to reduce bleeding or improve the ability to perform a watertight anastomosis and also caused a postoperative disturbance in gait.

The inability to control bleeding, the ignorance of neuroanatomy of erection (which was first described in 1979 (REF.[7])), the use of sharp dissection around the urethral sphincter and the difficulty in visualizing the vesicourethral anastomosis for suture placement all contributed to a high degree of postoperative complications. In some cases during retropubic prostatectomy, the bladder neck could not be approximated to the urethra for an anastomosis. Whilst undertaking a Fellowship at MD Anderson, I was taught under these circumstances to place what were called 'vest sutures', which ran from the bladder neck and were passed through to the skin of the perineum to anchor the bladder neck over the urethra. A balloon catheter on traction was used to reinforce the suture traction[9]. In particular, the lack of anatomical insight regarding the neurovascular bundle meant that, before 1984, almost all men (84%) undergoing radical retropubic prostatectomy suffered from postoperative erectile dysfunction (ED)

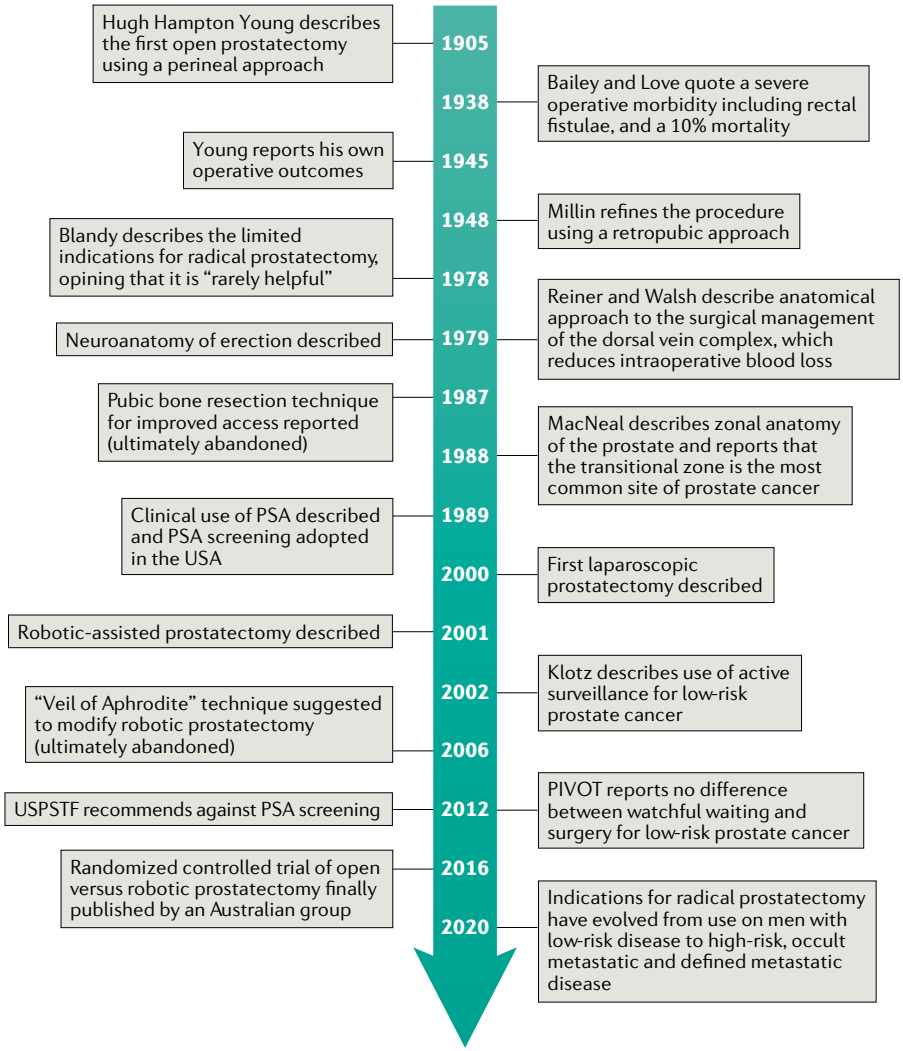

Fig. 1 | **Landmarks in prostatectomy.** Since Hugh Hampton Young reported the first open radical prostatectomy in 1904, the technique has been frequently modified. Particular changes came in the 1980s, when Walsh described the nerve-sparing technique, which considerably improved outcomes, and in 2000, when robotic radical prostatectomy was introduced. PIVOT, Prostate Cancer Intervention Versus Observation Trial; USPSTF, United States Preventive Services Task Force.

as the nerves were simply cut because their location and importance were unknown[10]. Poor visualization during suture placement for the vesicourethral anastomosis often resulted in postoperative urinary extravasation, which led to scarring around the anastomosis and resulted in many men requiring bladder neck incision at the site of vesicourethral stenosis after this retropubic operative approach[11,12]. Overall, until the mid-1980s, the operation was extremely hazardous for the patient. Morbidity was high and quality-of-life outcomes were poor[13], as could be expected after a procedure that resulted in severe incontinence, an ED rate of 84%[10] and considerable blood loss owing to the inability to control bleeding from the dorsal venous complex.

Advances in diagnosis and treatment of prostate cancer can be illustrated by contrasting the fate of a man who presented with prostate cancer in 1924, as described by Young[1], with that of a man who presents with prostate cancer in 2020. A man with prostate cancer in 1924 would normally have presented with urinary obstruction, prostatic bleeding and, almost certainly, painful backache as a result of bone metastases. A diagnosis of prostate cancer was made by rectal examination alone. In the unlikely event of treatment being offered, it was either perineal prostatectomy, which was associated with a 50% cancer mortality after 5 years, or radium insertion via the urethra or rectum, which was associated with a 75% mortality 2 years after insertion[14,15]. No hormonal therapy option was available; pain relief was with opioid medication for bone pain; and urinary obstruction would have been treated by some form of catheter drainage[4]. Interestingly, Young's 1945 review of 179 men presenting with prostate cancer shows that very few patients were suitable for any form of surgical excision[5] and, even when the prostate was excised, the morbidity of this operation was considerable[15].

This view was maintained even as late as 1978, when Professor John Blandy, in his *Operative Urology* textbook[16], described the limited indications for radical prostatectomy at the time. Although the procedure was popular in the USA, Blandy felt that surgery was rarely helpful.

By contrast, a man presenting with prostate cancer nowadays will usually have been diagnosed using a serum PSA test[17]. This type of diagnosis provides a 7–9-year lead time before metastasis occurs[17]. If surgery is offered, it is usually a robotic procedure performed as a day case[18]. Alternatively, a full course of potentially curative external beam radiotherapy can be offered. Should metastasis occur, sequenced combinations of hormone therapy, chemotherapy, targeted androgen receptor blockers, immunotherapeutic drugs or prostate-specific membrane antigen (PSMA)-guided theranostic radioactive nucleotide therapies are all treatment options in 2020 (REF.[19]).

The inception of radical prostatectomy

Hugh Hampton Young was a trainee of William Halsted — a pioneer of modern surgery — at Johns Hopkins in Baltimore. Young devised the perineal prostatectomy technique, publishing the results of his operation in 1905 (REF.[1]). He later reviewed all his own perineal prostatectomy operative outcomes in 1945 (REF.[5]). In Bailey and Love's textbook of surgery in 1938 (REF.[4]), the prognosis for men with prostate cancer was described as being very poor; radium had been tried without much success and with considerable morbidity, and recurrence within 2 years was common in those who survived prostatectomy. In a subsequent edition of the same textbook in 1968, radical cure by surgery was described as playing very little part in the management of prostate cancer[20].

This lack of enthusiasm continued until the 1980s, until Walsh described his anatomical insights, which coincided with the advent of PSA testing[2]. PSA testing resulted in earlier diagnosis of prostate cancer, 7–9 years before symptoms of metastatic disease manifested[21]. Thus, these advances meant that safe surgery could be

performed early in the disease course, before it became incurable.

The Walsh contribution

In the 1980s, Patrick Walsh made a contribution that dramatically improved the safety and quality-of-life outcomes of radical prostatectomy[10]. His insights into surgical technique and anatomical understanding during the 1980s enabled the development of a surgical approach that both reduced blood loss and preserved the erectile nerves.

Walsh is best known for his discovery of the neurovascular bundle — before this report, the cavernous nerves were thought to actually travel through the prostate, meaning that they would necessarily be removed during the prostatectomy[10]. However, the recognition that the neurovascular bundle ran in a groove between the rectum and prostate and that, as such, it could be preserved meant that nerve-sparing prostatectomy with the possibility of erectile recovery became widely available[10].

In 1979, Walsh had described formal haemostatic control in radical prostatectomy[6], suggesting ligation of the dorsal venous drainage from the penis as a first step in the operation, although his contributions in this field are less well known. Ligation of the dorsal vein provided excellent haemostatic control compared with Millin's previous version of the procedure, which had been associated with considerable blood loss. Before this report, the surgeon simply cut the dorsal vein, which often caused severe attendant haemorrhage[7]. A number of other intriguing techniques had previously been employed in an attempt to control this dorsal venous bleeding, including excision of the anterior pubic bone to improve access to the prostatic apex to gain better access to the prostatourethral junction, which caused substantial postoperative pain and gait disturbance[8].

The two surgical improvements described by Walsh improved the safety of the operation and enabled potency preservation, improving functional outcomes[6].

A window of opportunity

The clinical utility of PSA as a biomarker for early prostate cancer was first recognized in 1989 by Catalona[22,23]. Before these insights, the disease was often diagnosed at a late stage when the cancer caused voiding symptoms or haematuria or had metastasized to bone, causing bone pain. The introduction of serum PSA testing in the late 1980s meant that prostate cancer could be diagnosed nearly 10 years earlier than previously[21]. Thus, instead of operating on a man with advanced disease, often with occult metastases, surgeons could now offer safe surgery much earlier in the course of the disease.

Serendipitously, the arrival of the testing of serum PSA as a prostate cancer biomarker in the late 1980s[22] coincided with the advent of transrectal ultrasound (TRUS)-guided imaging of the prostate to aid the biopsy procedure[24]. Before the use of TRUS-guided imaging of the prostate, biopsy was performed blindly, using either a true cut needle or Franzen needle cytological aspiration, guided transrectally with the clinician's index finger. These blind finger-guided biopsies were notoriously inaccurate[24]. Improvements in understanding the zonal anatomy of the prostate[25] (FIG. 2) were provided by McNeal[26] who, in 1988, described the peripheral zone as the most common site of early prostate cancer and the transition zone as a site of benign prostatic hyperplasia. These anatomical and histopathological insights combined with TRUS-guided imaging enabled improvements in the accuracy of targeted sextant 12-core biopsy.

A rapid evolution

The technology change from open to minimally invasive laparoscopic surgery and then to robot-assisted surgery throughout the 1990s and early 2000s meant that many more men could be offered a procedure with reduced associated morbidity to manage their prostate cancer.

Evolution of the surgical approach

After functional outcomes, particularly potency, of retropubic radical prostatectomy were improved by Walsh, the nerve-sparing retropubic open operation became the standard surgical procedure for prostate cancer for over a decade.

The advent of laparoscopy. The 1990s heralded the introduction of a minimally invasive surgical approach using laparoscopy. By this time, laparoscopy had been in use for diagnostics in gynaecology for many years. Laparoscopy was introduced into gynaecology in 1970, primarily as a diagnostic tool and also for tubal ligation[27]. In the early 1990s, general surgeons adopted laparoscopy to perform cholecystectomy[28]. Urologists began to perform laparoscopic lymph node dissection (LND) for diagnosis in bladder and prostate cancer. Initially, laparoscopy was used in urology for diagnosis, for LND in prostate cancer and as a staging modality in bladder cancer[29]; the first laparoscopic prostatectomy was described in 2000 (REF.[30]). This procedure was extremely difficult to perform and required great skill, as laparoscopy is performed

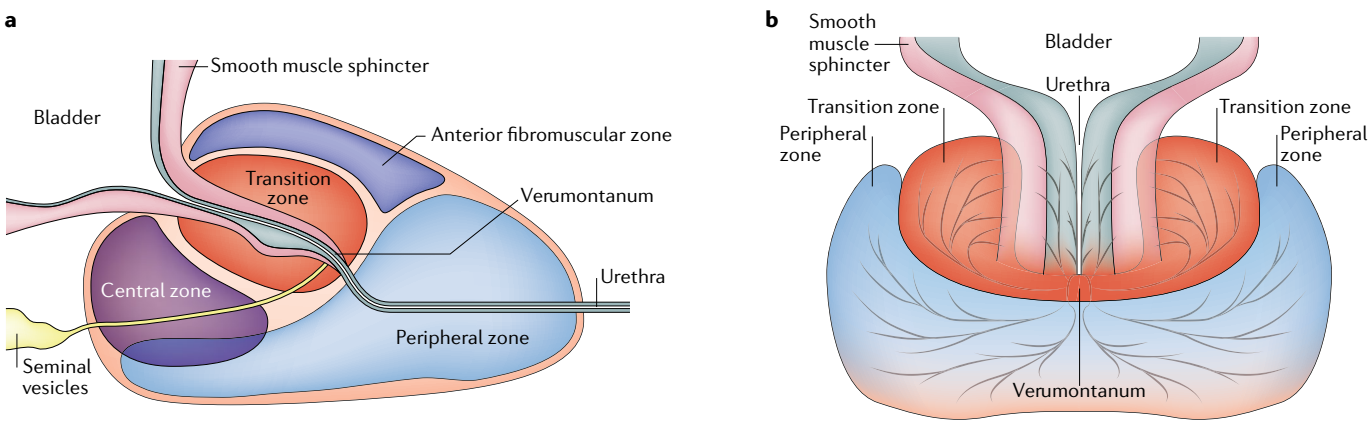

Fig. 2 | **Zonal anatomy of the prostate.** The anatomy of the prostate in the prone position (part **a**) and the upright position (part **b**). Zonal anatomy of the prostate was originally described by McNeal et al.[26] in 1988, who observed that the peripheral zone was the most common site of early prostate cancer and the transition zone a site of benign prostatic hyperplasia. Adapted from REF.[113], Springer Nature Limited.

via a 2D onscreen view and necessitated counterintuitive hand movements compared with open surgery[30]. Surgeons performing laparoscopic radical prostatectomy found that they could not match the continence outcomes obtained by surgeons using the open retropubic prostatectomy method[31,32]. At the time of this report, the continence outcomes in this series comparing open and laparoscopic prostatectomy were not equivalent laparoscopically to open surgery[32].

The rise of robotic surgery. In 1998, the Intuitive Surgical Company developed a prototype robotic machine, which used a 3D camera to provide the surgeon with a ×10 magnified view, with 3D depth perception and required intuitive hand movements equivalent to the human wrist[33]. Using the robot, the surgeon sat remote from the patient at a console and inserted their hands into telestration ports, which in turn digitized their hand movements and reproduced them exactly inside the patient's body at the tip of the surgical instruments. The robot enabled the surgeon to reconstruct tissues using sutures, as suturing became much easier using this enhanced view than it had been using standard laparoscopy[33].

Menon was one of the earliest to report the robotic prostatectomy technique, and he listed the steps of the operation, popularized it and, in 2004, produced the first large series to describe the technique for the application of robotic technology to remove the prostate[34]. This paper and other reports heralded the introduction of digitized, computerized surgery[35,36].

With the arrival of robot-assisted radical prostatectomy (RARP), the change in the way in which prostate cancer was surgically treated was profound. In 1980, a patient undergoing prostatectomy could expect a 3-week hospital stay, massive blood loss[37], almost certain ED owing to complete dissection of the neurovascular bundle and a high rate of incontinence[32]. By contrast, RARP required a hospital stay of just 24 h, a blood transfusion rate of near zero, continence outcomes of >90% and erectile function recovery of ~40% in high-volume centres[38,39].

In 2020, RARP has almost completely replaced laparoscopy for radical prostatectomy, except in countries where robotic machines are not affordable owing to the high initial costs of ~US$2.5 million[40].

An era of robotic prostatectomy

As RARP increased in popularity, it attracted considerable resistance from surgeons trained in the open radical retropubic prostatectomy method, as no randomized controlled trial (RCT) had demonstrated the superiority of the minimally invasive robotic method over the open method. Robotic prostatectomy was widely adopted for a number of reasons, but the very heavy marketing of the Da Vinci robot by vendors, hospitals and surgeons meant that patients were demanding the high-tech robot approach despite a lack of evidence to support its use. In many countries, especially the USA, patients were beguiled by this amazing new robot machine. Thus, a randomized trial was difficult because patients were unwilling to be randomized to the 'old' open method.

However, in 2010, surgeons in Australia were still providing open radical prostatectomy to patients in the public hospital system, where the robot was not available, and so recruitment for a randomized trial of open versus RARP was still possible[41]. By comparison, at this point, the open method had been largely abandoned in the USA. The RCT from Australia reported that continence and erectile function outcomes were similar after both robotic and open surgery at 12 weeks after surgery (urinary function score 83.80 open versus 82.50 robotic; $P = 0.48$; International Index of Erectile Function (IIEF) 35.00 open versus 38.90 robotic; $P = 0.18$)[41]. The main benefits associated with robot-assisted surgery relate to its minimally invasive nature. RARP requires no abdominal incision and blood loss is minimized[21]; thus, the patients do not need a blood transfusion and can quickly return to their normal activities, which means that inpatient stays are reduced and an increased number of procedures can be performed. Thus, rates of deep vein thrombosis (DVT) and pulmonary embolism dropped 1.55% to 0.001%, as patients can ambulate 12 h after RARP, and usually 24 h after open surgery[42,43]. The rates of bladder neck stenosis dramatically reduced using the robotic method, as the precision of a running sutured watertight join using the robot is far superior to the difficult anastomosis performed using the open method[8]. In 2011, Breyer and McAninch[11] reported a 16% bladder neck stricture rate after open prostatectomy, compared with a 2% rate after RARP reported by Msezane et al.[12] in 2008. Interestingly, insights gained from the robotic technique were then applied to the open surgical technique to improve open surgical outcomes; for example, the subumbilical incision used to perform open retropubic prostatectomy could be made smaller without compromising the surgical outcome and powerful magnifying glasses using ×4.3 magnification were introduced for use in open surgery[44].

Despite the improvements resulting from the use of robot-assisted techniques, the introduction of robotic surgery was generally not without criticism, much of which has been economic[45]. The monopoly of the Intuitive Surgical Company in the production of the robot has meant that both the disposable instruments and machines are extremely expensive. This cost has increased rather than decreased. Their monopoly in the market meant that as Intuitive made later versions of the robot, they could increase the price (Australian $3 million for the Si model to Australian $4.2 million for the Xi model); thus the persistent high costs of the machine and disposable instruments prevented its adoption in countries with limited health-care budgets. In 2020, surgical robots remain scarce in Asia-Pacific and Eastern Europe[46]. This monopoly situation is likely to change with the addition of new robotic machine manufacturers, such as Cambridge Medical Robotics (CMR), Medtronic and J&J/Google, who will enter the market of robotic surgical technology in 2020–2021 (REF.[47]).

In February 2019, a group from Memorial Sloan Kettering, NY, USA, a very high-volume robotic centre, published an analysis of potency outcomes in patients who underwent radical prostatectomy over the past decade, which included 2,364 patients treated with open or minimally invasive prostatectomy, both robotic and laparoscopic, between 2008 and 2015 (REF.[46]). Erectile function before and after radical prostatectomy was assessed using the IIEF score. After accounting for baseline pathological characteristics, urinary function and type of surgery, year of surgery was not associated with erectile function recovery on multivariate analysis (12 months OR 0.97, 95% CI 0.91–1.03, $P = 0.4$); regardless of whether the surgery was performed using the open or the minimally invasive method, erectile function recovery rates were ~30%[48]. Thus, the transition between open and robotic surgery approaches does not seem to have improved erectile outcomes after radical prostatectomy. The true benefits of robotic prostatectomy relate instead to its minimally invasive approach but have not translated into improved outcomes of continence, potency and surgical cancer margins[49]. Many of the early claims of improved benefit came from single-surgeon series[34], the majority of which could not be matched by other surgeons using the robotic method[50]. The alleged benefits of robot-assisted

surgery seemed to have been overstated. However, robotic prostatectomy has been almost universally adopted in countries in which the health-system economics enable installation of the technology.

Thus, despite widespread robotic surgery adoption, the measurable outcomes for the robotic prostatectomy method do not seem to have improved over the past 5 years[51]. In fact, in centres where only a few robotic procedures are performed annually, the results probably do not match those of open radical prostatectomy[52]. In 2016, two studies demonstrated that open surgery can reach near equivalence in terms of urinary continence, potency and oncological outcomes[41,51].

As well as reduced blood loss, early hospital discharge and early return to normal activity, the safe nature of robotic surgery means that many more men can be offered prostate cancer surgery than was previously the case. Unlike open extraperitoneal prostatectomy and extra-peritoneal laparoscopic prostatectomy, RARP can be offered to men with previous mesh hernia surgery (in whom dissection can be hazardous owing to mesh scarring and inflammation), in those who have previously received radiotherapy or in those who have undergone focal therapy. Men aged >70 years and even some healthy octogenarians are able to undergo RARP[53]. The advent of minimally invasive RARP has enabled expansion of surgery as a therapeutic option to many men who previously could not be offered extirpative prostate cancer surgery. Overall, RARP has resulted in remarkable benefits for patients. However, 20 years after its introduction, one must consider whether we have reached our limit in terms of optimizing the technical aspects of radical prostatectomy for improving quality of life outcome.

Is RARP superior to open surgery?

Since the introduction of RARP in 2000, the robotic method has generally been considered to be superior to the open method because it is minimally invasive and demonstrates equivalence in the outcome measures of cancer control continence and potency[18,54].

However, data published subsequently have provided a more nuanced evaluation of the benefit of RARP. In a study from Coughlin and colleagues[55] published in *The Lancet* in 2018, the two modalities were compared in an RCT, in which 100 men were randomized to each group. No significant difference was seen in outcomes of cancer control — there was no statistically significant difference in the evidence of disease progression in the two groups ($P = 0.2956$), and continence rates (that is, no pad use) were 95% at 24 months in the open group versus 91% in the robotic group. A modest benefit in erectile function was observed in the robotic group: 12 months after surgery, 75% of men reported ED in the open group versus 70% in the robotic group. However, benefits of RARP were observed in terms of reduced blood loss (open 1,338 ml versus robotic 443 ml), shorter operating time (open 234 min versus robotic 202 min) and shorter hospital stay (open 2.39 days versus robotic 1.55 days).

What is clear from comparative studies is that outcomes very much depend on the individual surgeon's skill, irrespective of whether the surgical method is open or robotic. The 2016 LAPPRO study compared 24-month outcomes from 14 Swedish centres and included 4,000 patients (3,000 of whom underwent RARP and 1,000 open prostatectomy) operated on by experienced surgeons[51]. A single surgeon carrying out open prostatectomy achieved the best continence outcomes, with 94% continence at 24 months. The best erectile function outcome was achieved by a surgeon carrying out robotic prostatectomy, with 62% potency at 24 months. Furthermore, in centres with a high surgical volume of radical prostatectomy (>150 cases/annum), outcomes were more favourable than when the procedure was performed in low-volume centres. Institutions performing high volumes of robotic radical prostatectomy achieved significantly better outcomes in all measurable parameters. Rates of urinary complications after radical prostatectomy are strongly associated with surgical volume, with surgeons in the lowest quartile for surgical volume exhibiting an increase of 25% in the relative risk of postoperative complications compared with the highest volume surgeons (26% versus 32%)[56–58].

The probability of biochemical recurrence within 5 years for a patient with organ-confined prostate cancer treated by a surgeon with 10 previous cases is estimated at 14% compared with <3% for a patient treated by a highly experienced surgeon with >1,000 prior cases[50].

Furthermore, the same paper[50] also reports that high-volume surgeons obtain a greater yield of lymph nodes at the dissection before radical prostatectomy than their low-volume counterparts, even though all surgeons use the same surgical template; this parameter might, in fact, be a surrogate measure of surgical competence[50,56]. I believe that these data support the regionalization of cancer services so that a small number of surgeons treat a large number of patients rather than a large number of surgeons treat only a few patients each.

RARP has now become the operation of choice for both localized and locally advanced prostate cancer and open radical prostatectomy is uncommonly performed in the USA. This change is supported by data that demonstrate equivalence in oncological and urinary continence outcomes and slightly improved outcomes with regard to erectile function[55].

Ultimately, the lifestyle benefits accorded by implementation of robotic technology in surgery have enabled more patients — even those who are elderly, frail or who have previous hernia repair — to be offered surgery for localized prostate cancer and in the salvage setting[55].

Where do we stand now?

Evolution in surgical technique has occurred concurrently with rapid progress in other forms of therapy for prostate cancer, including radiotherapy[59], chemotherapy[60], the introduction of immunotherapy[61] and a move towards active surveillance for men with low-risk disease[62]. The variety of options that are, therefore, available for contemporary prostate cancer management raise the question of where surgery fits into the current treatment algorithm and how it will continue to be used. It also raises the intriguing question of whether we have reached the limit of efficacy of robotic prostatectomy as a surgery to achieve cancer control or whether the technique can be further refined. For example, although continence outcomes of RARP are excellent, numerous studies have been published suggesting procedures to further improve continence (BOX 1) via the use of a suburethral stitch[63,64], maximizing urethral length[65,66] and Retzius sparing[66–68]. Similarly, one study has claimed a potency rate of 96% 12 months after surgery, using a veil of Aphrodite technique[69]. However, a study that included outcomes from multiple high-volume surgeons performing radical prostatectomy across 14 centres reported more modest outcomes of ~70% erectile function 1 year after surgery[70]. Thus, a major consideration when assessing changes to surgical technique is that single-centre reports are inherently biased and are often not reproducible when tested by a diverse cohort of surgeons. Overall, despite the technological improvements that transformed radical prostatectomy from a morbid open procedure to a minimally invasive, minimally morbid operation, the

original potency, continence and oncological outcomes of prostatectomy have not been improved upon, despite robot machine introduction and a learning curve that was achieved by surgeons who have now become expert robotic prostatectomists. Perhaps instead the answer to optimizing the role of surgery in prostate cancer will come from improved understanding of the molecular biology of prostate cancer, resulting in a treatment plan whereby radical prostatectomy is only part of the repertoire of multimodal therapy that also includes chemotherapy, targeted radiotherapy and immunotherapy[71]. Multimodal therapy is slowly developing, but some therapies are still not available or affordable in many health-care systems.

The role of surgery in 2020

Radical prostatectomy[9] was originally introduced as a local therapy for localized disease, with the intention to cure the patient of prostate cancer[2]. However, over the past 40 years, the role of surgery in prostate cancer management has changed considerably. For example, many men operated on for prostate cancer between 1980 and 2005, who were, in retrospect, good candidates for active surveillance, were instead offered radical prostatectomy[72]. This overtreatment was due to a lack of insight into the lethal phenotype of prostate cancer and understanding that Gleason score 3 + 3 (Grade Group 1) cancer rarely — if ever — metastasizes[72]. Evidence now shows that

Box 1 | **Modifications in robotic surgery without evidence of efficacy**

Since the introduction of robot-assisted radical prostatectomy (RARP), a number of variations on the original description of this operation have been described[38].

The Veil of Aphrodite technique

This technical modification to preserve the neurovascular bundle was described in 2006 in a study from Menon's group in Detroit that reported erectile outcomes following RARP with a questionnaire-based analysis. Conventional nerve sparing was compared with a prostatic fascia-sparing technique, which was coined the "Veil of Aphrodite technique". This approach involved resection of the periprostatic fascia high on the lateral sides of the prostate to drop this fascia and to prevent damage to the neurovascular bundle, which sits below. This technique was only popularized by the Detroit group, who first described it, and its rationale was questioned in a subsequent cadaveric analysis of periprostatic nerve distribution from our group in Melbourne, which examined the level of the cavernous nerves in the neurovascular bundle[106]. This study found that the majority of nerves of the neurovascular bundle were situated inferolateral to the prostate above the rectum; thus, high release of the fascia above the midline of the prostate could have little effect on preservation of these important nerves. Instead, high release of the anterior fascia around the prostate at radical prostatectomy might steer the surgeon away from damaging those nerves, as they swing anteriorly towards the apex of the prostate and urethra bilaterally. The Veil of Aphrodite dissection has, therefore, fallen from favour and is not now described in textbooks on robotic surgical techniques.

Preservation of the urethral smooth muscle

Preservation of the smooth muscle of the urethra has been postulated to aid restoration of postoperative incontinence following radical prostatectomy[66]. However, the smooth muscle of the urethral sphincter supplies only passive continence and true active continence is mediated via the striated muscle, which is supplied by the pudendal nerve[107]. Unless urethral preservation length correlates with improved preservation of skeletal muscle fibres, preservation of urethral smooth muscle has no anatomical basis for improving postoperative continence following radical prostatectomy.

The suburethral plication stitch

Several studies have suggested that a plication stitch running suburethrally at the apex of the prostate to the Denonvilliers layer below the bladder aids restoration of postoperative continence[64,108]. The plication stitch is implemented before performing the anastomosis. The stitch is placed into the baseplate of tissue beneath the anastomosis to improve postoperative continence. However, this method — also known as the Rocco stitch — does not seem to be associated with improved continence following RARP and no trials have supported its use.

A 2012 systematic review and meta-analysis of studies reporting urinary continence recovery after RARP reviewed 51 articles reporting urinary continence rates after RARP[109]. The incidence of no pad and/or safety pad use following surgery at 12 months ranged from 89% to 92% irrespective of the technique used and whether the plication stitch was used. The meta-analysis concluded that prevalence of urinary incontinence after robotic prostatectomy is influenced by preoperative patient characteristics, surgeon experience, surgical technique and methods used to collect report data, and that posterior muscular fascial reconstruction using the Rocco stitch seems to offer a slight advantage at 1 month after surgery but not thereafter.

Seminal vesicle-sparing prostatectomy

Reports that sparing of the seminal vesicles leads to improved postoperative continence after radical prostatectomy are, at the time of writing, purely anecdotal. No specific report in the literature supports this claim, which has been handed down from surgeon to surgeon. A 2017 randomized control trial compared functional outcomes following standard nerve-sparing RARP ($n = 70$) and the nerve-sparing technique augmented by seminal vesicle sparing ($n = 70$)[110]. No differences were seen in sexual and urinary functional scores, surgical margin status or PSA biochemical recurrence between the groups, and the authors concluded that seminal vesicle-sparing prostatectomy was of little use. This conclusion was supported by anatomical studies from our group at the Royal Melbourne Hospital, which demonstrated that the autonomic neural components of the neurovascular bundle were not in close proximity to the tips of the seminal vesicles[49]. In fact, the S2–S4 parasympathetic autonomic nerves join a ganglion 1–2 cm away from the seminal vesicle tips, close to the base of the prostate. Thus, dissection of the seminal vesicles is unlikely to compromise autonomic function, and a link between seminal vesicle preservation and the functional and oncological outcomes of radical prostatectomy is unlikely.

Retzius-sparing radical prostatectomy

In 2015, Rha et al.[111] reported the Retzius-sparing RARP technique. In this approach, the surgery commences with an incision through the peritoneum posterior to the bladder and the seminal vesicles are dissected as a first step. Rha and colleagues' initial reports of this technique described a high T2-positive margin rate of 12% compared with 5.3% in a matched robotic-assisted laparoscopic prostatectomy (RALP) cohort. This high rate of T2 margin positivity was explained as being a result of the steep learning curve associated with performing this technique. Subsequent reports have been based on single institutions. A 2017 study from Menon's group in Detroit investigated functional recovery, oncological outcomes and postoperative complications in a randomized study of 120 patients after standard RARP (which is performed anterior to the prostate in the space of Retzius) versus the Retzius-sparing approach[67]. They concluded that, in patients with low-risk or intermediate-risk prostate cancer, outcomes at a 12-month follow-up point were not significantly different in any of the measurable parameters and that return to continence in Retzius-sparing surgery was no different from that in conventional surgery ($P = 0.001$)[112]. However, the Retzius-sparing approach is technically difficult, associated with a steep learning curve and should be performed by surgeons already skilled in the standard RALP all technique.

these men with Gleason Grade Group 1 disease have biologically insignificant cancer[72] and can be safely managed on an active surveillance programme[73]. At the other end of the disease spectrum, during the same period, if a frozen section demonstrated a pelvic node metastasis, the operation was abandoned; the prostate remained in situ and the man was offered androgen deprivation therapy (ADT) alone[9]. Now, 40 years later, the approach to prostate cancer has changed completely, owing to modern imaging techniques that have enabled early diagnosis and staging. In 2020, such imaging techniques include PET scanning with ^{72}Ga-PSMA (PSMA PET), which has superseded staging imaging modalities such as technetium bone scan and abdominal and pelvic CT[74]. In the past, negative Tc scan or CT showing no evidence of metastases and, therefore, indicating localized prostate cancer meant that surgery was then offered in the hope that it would be curative. Improved imaging means that aggressive prostate cancer (Gleason score 4 + 3; Grade Group 3 and above) is now found more often as a systemic disease and ab initio. Thus, surgeons in 2020 are now operating on men with metastatic disease in whom these metastases would previously have been invisible before surgery. Some men with metastatic prostate cancer might benefit from removal of the primary tumour[75].

The contribution of imaging techniques

PET scanning with ^{72}Ga-PSMA can detect most prostate cancer metastases when they reach the size of 4 mm in diameter[76]. Now that prostate cancer can be more accurately staged, clinicians have to grapple with positioning the different therapies in their armamentarium so that the sequence of therapies provides the optimal potential for increased longevity whilst balancing a good quality of life. Currently, many surgeons operate on patients without imaged metastatic disease, relying on conventional bone scan and CT scan for information about metastatic burden. However, now that ^{72}Ga-PSMA scanning can determine if the patient has metastatic disease, it raises the question of whether we should continue to operate on these patients using radical prostatectomy as a first step in a therapeutic algorithm.

Our insights into the prostate cancer phenotype provide a strong rationale for surgical intervention as soon as Gleason grade ≥7 is diagnosed, before mutation to a more lethal phenotype occurs. In this scenario, radical prostatectomy might be the only necessary intervention to prevent a man from dying of prostate cancer. In 2010, a study investigating the association between lead time and prostate cancer grade showed evidence of grade progression from long-term follow-up monitoring of large population-based cohorts (n = 1,041), who were not subject to PSA screening[77]. The data convincingly supported grade progression whereby tracking a prostate tumour over time demonstrated transitions from benign to low-grade and then to high-grade prostate cancer. Men with a longer lead time between detection of elevated PSA and subsequent prostate cancer diagnosis were more likely to have high-grade cancer at diagnosis (OR 1.13)[78].

Rather than being the sole approach for definitive therapy, modern RARP could now be the first step. Removing the prostate will control disease in the primary cancer in the pelvis, obviating the potential for later urinary obstruction and bleeding from an enlarging and increasingly aggressive primary prostate tumour. Thus, surgery would be the first step in treating clinically localized prostate cancer and, as stated above, might be the only treatment necessary. In patients with a limited metastatic burden, it could also have a role after neoadjuvant therapy. The subsequent chemotherapeutics used in the multi-pronged and sequenced therapy cascade carry more morbidity and are more hazardous than surgery. In this scenario, surgery is performed to achieve local control and life extension, but also to avoid the delay in initiating ADT. If prostate removal is performed early enough in the course of the cancer evolution, the operation could truly be curative, as has been demonstrated in Scandinavian screening studies in which PSA testing resulted in a difference of 6–8 years in lead time over those men who were not tested, resulting in improved outcomes[77,78].

Considering pelvic node dissection

Insights from modern imaging techniques have given us cause to question the validity of combining RARP with pelvic node dissection, either limited or extensive. In 1898, Halsted promoted the concept of wide local excision of the primary tumour in conjunction with regional node dissection, based on the hypothesis that primary prostate cancer metastasized in a stepwise, locoregional fashion from the prostate and then to the pelvic nodes[79]. Subsequently, surgeons even now apply this principal of extirpation of the primary cancer and local pelvic regional node dissection.

Some tumour types do seem to metastasize in a stepwise Halstedian fashion. For example, bladder cancer tends to spread first to the locoregional nodes[80]. Thus, the concept of wide local excision including the draining lymph nodes is logical in the surgical management of these cancers. However, prostate cancer behaves differently and can metastasize first haematogenously to the bone marrow, or skip the pelvis altogether, with nodal spread being first noted in the abdomen[81]. PSMA PET has demonstrated the capricious nature of prostate cancer metastases, and, in some cases, the first echelon node metastasis is found in the supraclavicular region. In fact, contrary to previous dogma, lymph nodes might, in fact, be a type of oncological cul-de-sac and be associated with a less lethal phenotype than haematogenously borne metastatic disease[82].

A role for node dissection? Improved accuracy of imaging now raises the conundrum of how to proceed when obvious metastases are imaged. Pelvic lymph node metastases might be identified preoperatively and can then be removed at primary surgery. If the scan is only performed after surgery, then it might be feasible to perform salvage node dissection treating identified disease rather than blind node dissection, which accompanies prostatectomy surgery at present. However, if the use of preoperative PSMA PET scanning becomes more widespread, enabling synchronous diagnosis of nodal spread, then performing node dissection of imaged disease at the time of primary surgery could be a logical approach. Pelvic lymph node dissection (PLND) at radical prostatectomy is currently performed blind, without knowledge of the presence of metastases. Limited and extended node dissection templates are available[83,84] (FIG. 3). These templates only cover 50–60% of the pelvic prostatic node drainage, with 40% of nodes outside the surgical dissection template[85].

The majority of patients staged with less accurate imaging (such as bone scan and CT) do not have imaged metastases when primary surgery is considered[86]. Blind PLND — template-standardized pelvic en bloc node dissection — can be an extensive operation and is associated with substantial adverse effects, including lymphocele, DVT and pulmonary embolism[87]. Before node dissection is performed, these effects must be weighed against the benefits of performing blind locoregional node dissection. If stereotactic body radiotherapy

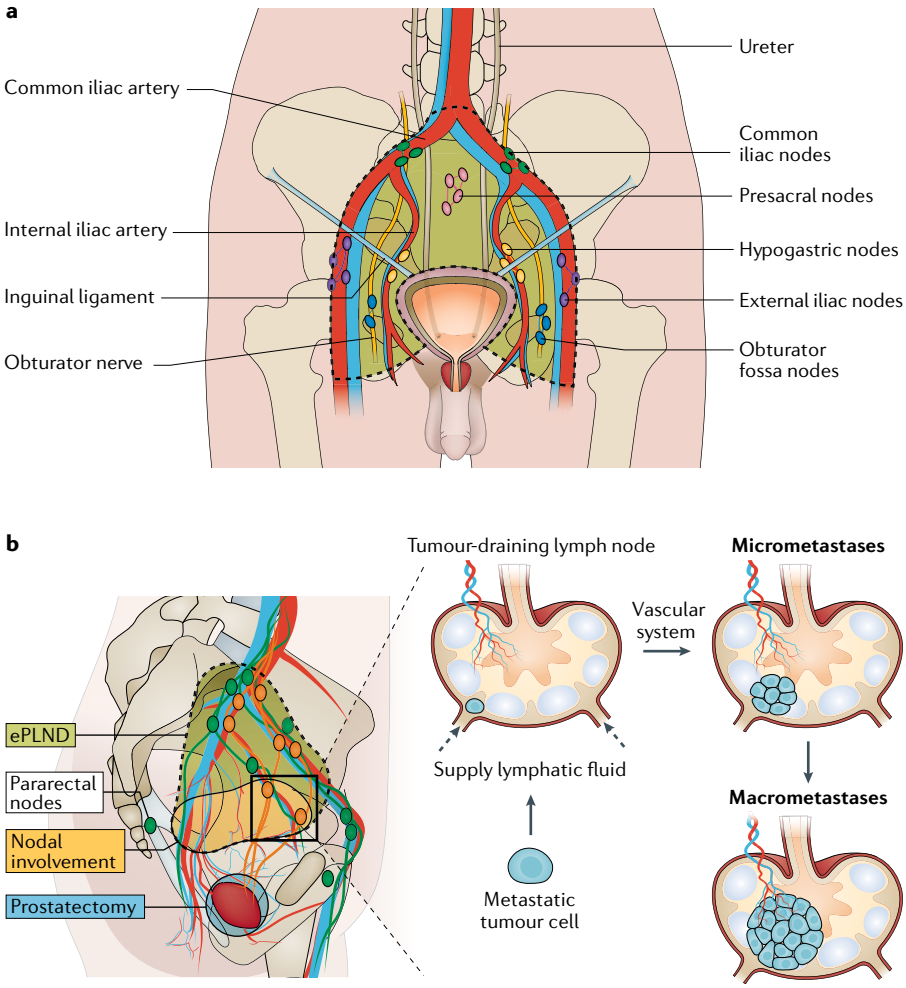

Fig. 3 | **Lymph node dissection templates. a** | Limited pelvic lymph node dissection (PLND) usually includes dissection restricted to the obturator fossa bilaterally. **b** | Standard PLND includes nodal dissection between the bifurcation of the common iliac artery proximally, the inguinal ligament distally, the genitofemoral nerve laterally and the bladder wall medially, and typically includes the distal common iliac, external iliac, obturator and hypogastric nodes on either side. **c** | Extended PLND (ePLND) typically refers to the removal of nodes between the aortic bifurcation and common iliac vessels proximally, the genitofemoral nerve laterally, the circumflex iliac vein distally and the internal iliac vessels posteriorly. **d** | Super-extended PLND refers to a dissection that is continued proximally to the root of the inferior mesenteric artery. Adapted from REF.[84], Springer Nature Limited.

(SBRT) is a logical treatment option in sequenced prostate cancer therapy, then there might also be a role for limited targeted pelvic node dissection following prostatectomy in certain instances. As yet, whether salvage surgery is better than SBRT is uncertain. SBRT is able to cover a wider field than surgery. PSMA PET scanning will not detect nodal disease <4 mm in diameter; thus, small metastatic nodes might be missed, whereas the radiation field of SBRT can cover a wide field and might be more effective.

No studies have demonstrated the oncological benefit of either limited or extended pelvic lymph node dissection (ePLND) that justifies the attendant morbidity associated with LND[86,87].

The vast majority of ePLNDs reveal benign histology only, possibly owing to the wide variation in lymph node drainage from the primary prostate tumour[88,89], which means that pelvic nodes might not be the first site of metastases. In a 2018 study, Yaxley et al.[86] reported that only 61 of 1,184 LNDs showed node-positive cancer; the other 1,123 patients had benign tissue only. As PSMA PET imaging has demonstrated that the first echelon of imageable node metastases of primary prostate cancer can be in the sigmoid or rectal mesentery, para-aortic nodes above the pelvis, subclavian nodes and even the lung, the clinical value of PLND is called into question, as lymph node section templates, whether standard or extended, will never remove these nodes[90].

Proponents of pelvic node dissection at radical prostatectomy argue that its value comes from providing staging information[91]. However, staging can also be accurately assessed using postoperative PSA testing and PSMA PET scanning[90]. The histological importance of pelvic node metastases remains uncertain, in particular the question of whether some of these cell nests in the pelvic nodes are necessarily lethal. Prostate cancer cells in pelvic nodes can remain dormant for many years[92], but lymph node metastases might be phenotypically less aggressive than bone or visceral metastases[82]. Yaxley and colleagues' 2018 study[86] of a series of 1,180 patients treated with ePLND by 13 surgeons reported a positive node yield of just 5.5%; however, 40 of 62 surgeries in which node dissection was positive also demonstrated seminal vesicle invasion and the median Gleason score in these patients was 4 + 5. The number needed to treat for PLND to detect node metastases was 19, and to hypothetically improve survival outcomes beyond those of prostatectomy alone, the number needed to treat for cure by PLND was 395. In such patients, the high-grade disease is likely systemic and adding the very-low-yield node dissection procedure, which is associated with considerable morbidity, is not justifiable given the number needed to treat.

In another study, 7 of 88 (8%) men with node-positive disease remained free from biochemical recurrence at 5.6 years following surgery and only 8% of these men remained free of biochemical recurrence at 15 years[93]. This report demonstrates that the therapeutic benefit of removing the nodes is minimal when 92% recurred regardless of node dissection after 15 years. A series of 19,633 patients who underwent PLND reported 505 positive lymph nodes, which translates to 2.5% of this cohort having node metastases[94]. Only 7.1% of the node-positive patients remained free of biochemical recurrence at 15 years[94], also suggesting that node dissection does not have a therapeutic benefit, as patients fail treatment irrespective of node removal.

In my view, the addition of standard PLND or ePLND to RARP is not indicated. No consensus is available in the literature to determine what standard node dissection includes and whether it covers the obturator only, or the obturator and the internal iliac. LND is justified in neither a therapeutic scenario (that is, to delay disease progression) nor in an oncological sense for cancer staging. The advent of modern PSMA PET imaging has given us knowledge of the multiplicity of primary nodal metastatic

drainage from prostate cancer, illustrating that primary node metastases are not uncommonly found outside the surgical dissection template, undermining the rationale for primary dissection of the pelvic nodes.

Node dissection in oligometastatic disease. If there is doubt about the efficacy of primary LND at the time of prostatectomy, it raises the question of whether salvage node dissection has a role in contemporary prostate cancer management. PSMA PET imaging has demonstrated that nodal metastatic disease post-prostatectomy might be amenable to surgical removal or salvage SBRT[76]. The minimum diameter needed for PSMA PET to detect node metastases is 4 mm (REF.[76]) and, even when imaging seems to show a single node deposit, histology often reveals a greater nodal disease burden than the imaging[76]. However, surgical removal or SBRT of imageable disease has been shown to increase the time before institution of hormone therapy by up to 36 months[95]. Node dissection might well have a role in the treatment of oligometastatic disease, but, as the literature stands, the evidence is currently insufficient to draw conclusions.

Considering nerve sparing

Several studies have suggested that meticulous neurovascular bundle sparing at radical prostatectomy improves postoperative continence outcomes[96–98]. However, in a 2016 meta-analysis no difference in continence outcomes beyond 6 months was observed, regardless of whether a nerve-sparing or non-nerve-sparing procedure was performed, although time to continence was improved[97]. The hypothesis that nerve sparing of the autonomic neurovascular bundle nerves can affect urinary control, mediated by the (somatic) pudendal nerve to the skeletal muscle of the rhabdosphincter, is curious. The autonomic nerves control erectile function, not continence; the pudendal nerve, a motor nerve to the skeletal muscle of the striated sphincter, is the continence mechanism. Thus, these two different nerve supplies have separate functions. The course of the pudendal nerve is between the levator ani and the obturator muscles; the pudendal nerve pierces the levator ani at the apex of the prostate and sends branches to the rhabdosphincter at this position. Thus, apical dissection is a critical step in radical prostatectomy, as both the erectile and continence nerves are in close proximity. Damage to the erectile nerves is more likely here as they are very close to the prostatic apex, but rough dissection at the apex can conceivably damage the pudendal nerve, which, although further away, is still close enough to be injured. Thus, careful sparing of the potency nerves at the apex might also help to prevent injury to the nearby pudendal continence nerves. The discovery and description of the anatomy of the neurovascular bundle in 1984 (REF.[10]) heralded a new era in prostatectomy, enabling preservation of erectile function in up to ~40% of patients[70], as the erectile nerves were no longer cut. Very few patients are unsuitable for nerve sparing, which can usually be performed incrementally to some degree, even in men with extracapsular disease, although in advanced localized prostate cancer sometimes a wide excision has to be performed. Studies have shown that extracapsular extension of prostate cancer rarely extends histologically beyond 3 mm (REF.[99]), whereas anatomical studies have demonstrated that the distance between the prostatic capsule and the cavernous nerves (which are in a posterolateral fascial compartment in the bundle) is around 5 mm (REF.[100]). Thus, even if preoperative MRI of the prostate suggests extracapsular extension, the nerves do not have to be completely dissected or resected. Digital rectal examination suggesting extracapsular extension should not predicate extirpation of the nerve bundles — if the palpable disease is unilateral, then at least unilateral nerve sparing can be performed on the contralateral side.

Radical prostatectomy in 2020?

The early prostatectomy techniques of perineal prostatectomy developed 120 years ago by Young and the retropubic prostatectomy popularized by Millin in 1948 both fell out of favour owing to extreme associated morbidity[4]. In 1980, when Walsh reintroduced anatomical radical prostatectomy with a much improved safety profile, the operation was widely readopted[6]. However, at that time, the operation was often performed on patients with low-risk disease who did not need surgery, and men with high-risk prostate cancer were denied surgery in the belief that the surgery could not possibly be curative. Thus, many radical prostatectomies performed in the 1980s and 1990s were for patients with low-risk and very-low-risk prostate cancer. Improved biological insights, particularly the information that Gleason 6 prostate cancer is not lethal, mean that in contemporary clinical practice, many men who had previously been offered surgery for low-grade prostate cancer are instead enrolled in an active surveillance programme. Active surveillance is now offered to ~40% of men with a histological diagnosis of low-grade prostate cancer in Victoria, Australia[101]. The uptake of active surveillance for low-grade, Gleason 6, cancer has been variable around the world.

As we head into the third decade of the 21st century, it seems inevitable that almost all prostate cancer surgery will be performed robotically from now on. Although randomized trials have not shown markedly improved benefit in terms of functional or oncological outcomes after RARP, robotic surgery is associated with the known benefits of minimally invasive surgery and, therefore, open surgery is unlikely to have a renaissance, particularly given that the economics of robotic surgery will improve with the advent of new systems[47]. However, quality-of-life outcomes following radical prostatectomy have not improved over the past 10 years, as demonstrated in a study that compared functional outcomes after prostatectomy from 2008 to 2018 (REF.[48]); such functional outcomes of continence and potency directly translate to quality of life.

Numerous technical modifications to robotic technique have been suggested, the outcomes of which have not lived up to the initial promise (BOX 1). Thus, we seem to have reached the technical limits of our ability to provide a quality surgical procedure for prostate cancer using robotic technology.

Changing indications

In 2020, the primary indication for radical prostatectomy is a diagnosis of intermediate-risk or high-risk disease. These men undergo a metastatic work-up, which includes technetium bone scan and abdominal and pelvic CT scan, but currently does not include PSMA PET imaging as standard. If the metastatic work-up indicates localized disease, the patient is offered radical prostatectomy with a curative aim. If surgery is performed early in the mutational cascade of the tumour, the patient could indeed be cured and will not, therefore, die of prostate cancer[78].

Based on extrapolation of data from the STAMPEDE trial[102], prostatectomy might be an appropriate first step in a multidisciplinary approach to prostate cancer in men with a limited metastatic burden. STAMPEDE demonstrated that a combination of treatment of the primary cancer plus radiation therapy in patients with oligometastatic disease did improve survival. Failure-free survival was improved in those patients with low metastatic burden

(HR 0.78, 95% CI 0.63–0.98; $P = 0.033$) and a beneficial effect of prostatic radiotherapy was seen in men newly diagnosed with limited metastatic disease compared with those given hormone therapy alone[102]. Thus, the contemporary role of surgery becomes sterilization of the pelvis, removing the primary malignant organ to prevent further metastatic seeding. Removal of the primary tumour also prevents late complications of aggressive prostate cancer, such as bilateral ureteric obstruction, bleeding and urinary incontinence[4]. The logic of this approach is partly based on the adverse effects profile of ADT, the most favoured alternative option for men with metastatic prostate cancer. ADT leads to sexual dysfunction, with loss of libido in 90% of treated men and loss of erectile function in 50%[103]. Taking this high rate of sexual dysfunction into consideration demonstrates the appeal of surgery, which permits deferment of ADT, and making the main risk of treatment a 5% risk of urinary incontinence at 24 months using modern robotic techniques[55]. The lack of sexual dysfunction as an adverse effect means that prostatectomy can be more safely offered to men who might otherwise have been offered ADT for limited metastatic disease.

The insights obtained using PSMA PET imaging have altered the way in which we view high-grade prostate cancer[104], so that, in 2020, the current understanding is that high-grade prostate cancer might be a systemic disease ab initio and that surgery or radiotherapy are reasonable therapeutic approaches, either early or late in disease management.

Thus, the role of radical prostatectomy for prostate cancer has evolved over the past 120 years. Initially high rates of morbidity almost led to the operation being abandoned. Then, as the operation evolved to become safer, it was offered to men with low-risk and very low-risk prostate cancer. In 2020, radical prostatectomy is now a proven, effective cancer therapy in men with moderate-risk and high-risk disease and is also an option for men with occult or proven low-volume metastatic disease.

Future directions

Use of diagnostic prostate MRI is likely to increase; in time, all men who have suspected prostate cancer will most likely undergo a prebiopsy MRI[25].

The use of diagnostic MRI can then guide targeted biopsy of lesions described by radiologists as Prostate Imaging Reporting and Data System (PIRADS) score 3, 4 and 5, reducing the number of unnecessary biopsies performed. Surgeons will then be more certain that they are offering radical prostatectomy to those men who can truly benefit.

We are entering the next generation of robotic surgical machines. Numerous new robotic systems will become available as the patents for the first-generation da Vinci platform expire and the technology expands[47]. Several console-based robots for laparoscopic multiport and single-port surgery will come to market in 2020, including platforms from CMR and Medtronic, and the features of these new robots are likely to differ considerably, using a variety of instrumentation, consoles and video technologies[45]. Furthermore, the loss of Intuitive's monopoly and associated cost reduction will enable more widespread uptake of new systems, as the availability of less expensive robots will mean that many more patients can be offered robotic surgery. In the past, the major concern in the application of robotics has been cost, but the arrival of modular robotic machines, such as the upcoming model from CMR, which plans to include the instrument cost in the machine cost and increase the number of uses of the instruments by 50%, will reduce the instrumentation cost of RARP to be equivalent to that of laparoscopic surgery, leading to dissemination of robotics throughout pelvic and upper abdominal surgery. The development of the safe provision of robotic surgery in prostatectomy has blazed a trail for dissemination of robotic surgery into many other applications in addition to prostate cancer and indeed in specialties outside urology and gynaecology[105]. These expanded uses will mandate the embedding of a robotic surgery curriculum in all surgical residency training programmes alongside appropriate simulation and virtual reality systems for surgical teaching, improving surgical training and, therefore, most likely leading to improved patient outcomes.

Conclusions

No clear improvement in quality-of-life outcomes after radical prostatectomy have been observed over the past 10 years as RARP has become the norm. A number of reports, mainly from single centres, have described the benefits of some technical modifications to this surgery; however, examination of these modifications seems to reveal no benefit in improving functional outcomes. Thus, we seem to have reached the technical limits of our ability to provide a quality surgical procedure for prostate cancer using robotic technology[70].

As the role of surgery evolves, robotic prostatectomy might become the first salvo, sterilizing the pelvis of local disease in preparation for the targeted and systemic therapies to follow. Prostatectomy might instead be reserved for use after aggressive neoadjuvant therapy, similar to the role of cystectomy in muscle-invasive bladder cancer.

Imaging insights obtained using PSMA PET scanning now lead us to believe that high-grade prostate cancer is a systemic disease and that surgery or radiation are two approaches that can be applied in early or late disease management.

For many years, prostatectomy has been offered to men with limited metastatic disease. Thus, in 2020, where radical prostatectomy was once an operation for men with very-low-risk and low-risk prostate cancer, its indication has now changed to be used instead in men with high-risk, occult metastatic and defined metastatic disease.

Anthony J. Costello

Department of Urology, Royal Melbourne Hospital, University of Melbourne, Melbourne, Australia.

e-mail: tony@tonycostello.com.au

https://doi.org/10.1038/s41585-020-0287-y

Published online 21 February 2020

1. Young, H. H. VIII. conservative perineal prostatectomy: the results of two years' experience and report of seventy-five cases. *Ann. Surg.* **41**, 549–557 (1905).
2. Sathianathen, N. J. et al. Landmarks in prostate cancer. *Nat. Rev. Urol.* **15**, 627–642 (2018).
3. Millin, T. Retropubic prostatectomy. *J. Urol.* **59**, 267–280 (1948).
4. Bailey, H., Love, R. J. *A Short Practice of Surgery*. 4th ed. (H.K.Lewis & Co Ltd., 1938).
5. Young, H. H. The cure of cancer of the prostate by radical perineal prostatectomy (prostato-seminal vesiculectomy). *J. Urol.* **53**, 188–253 (1945).
6. Walsh, P. C. Radical prostatectomy for the treatment of localized prostatic carcinoma. *Urol. Clin. North Am.* **7**, 583–591 (1980).
7. Reiner, W. G. & Walsh, P. C. An anatomical approach to the surgical management of the dorsal vein complex. *J. Urol.* **121**, 198–200 (1979).
8. Lange, P. H. & Reddy, P. K. Technical nuances and surgical results of radical retropubic prostatectomy in 150 patients. *J. Urol.* **138**, 348–352 (1987).
9. Johnson & Boileau. in *Genito Urinary Tumours* Ch 3 46–47 (Grune and Stratton Sullivan, 1982).
10. Walsh, P. C. & Donker, P. J. Impotence following radical prostatectomy: insight into etiology and prevention. *J. Urol.* **128**, 492–497 (1982).
11. Breyer, B. N. & McAninch, J. W. Management of recalcitrant bladder neck contracture after radical prostatectomy for prostate cancer. Endoscopic and open surgery. *J. Urol.* **185**, 390–391 (2011).
12. Msezane, L. P. et al. Bladder neck contracture after robot-assisted laparoscopic radical prostatectomy: evaluation of incidence and risk factors and impact on urinary function. *J. Endourol.* **22**, 97–104 (2008).
13. Harding Rains, A. J., Capper, M. *Bailey & Love's Short Practice of Surgery*. (H.K.Lewis & Co Ltd., 1968).
14. Bumpus, H. C. Carcinoma of the prostate radium and surgical treatment. *Surg. Gynaecol. Obstet.* **35**, 177 (1922).
15. Cabot, H. Factors influencing the mortality of suprapubic prostatectomy. *Surg. Gynaecol. Obstet.* **17**, 689 (1913).
16. Blandy, J. P. *Operative Urology* (Blackwell, (1978).
17. Tornblom, M. et al. Lead time associated with screening for prostate cancer. *Int. J. Cancer* **108**, 122–129 (2004).

18. Chang, S. L., Kibel, A. S., Brooks, J. D. & Chung, B. I. The impact of robotic surgery on the surgical management of prostate cancer in the USA. *BJU Int.* **115**, 929–936 (2015).
19. Nuhn, P. et al. Update on systemic prostate cancer therapies: management of metastatic castration-resistant prostate cancer in the Era of precision oncology. *Eur. Urol.* **75**, 88–99 (2019).
20. Harding Rains, A. J. & Capper, M. *Bailey & Love's Short Practice of Surgery*. 14th ed. (H.K.Lewis & Co Ltd, 1998).
21. Hudson, M. A., Bahnson, R. R. & Catalona, W. J. Clinical use of prostate specific antigen in patients with prostate cancer. *J. Urol.* **142**, 1011–1017 (1989).
22. Catalona, W. J. et al. Detection of organ confined prostate cancer is increased through PSA based screening. *JAMA* **270**, 948–954 (1993).
23. Ellis, W. J. et al. Early detection of prostate cancer with an ultrasensitive chemoluminescent PSA assay. *Urology* **50**, 573–579 (1997).
24. Ragde, H. H., Aldape, H. C. & Bagley, C. M. Ultrasound guided prostate biopsy. Biopsy gun superior to aspiration. *Urology* **32**, 503–506 (1988).
25. Stabile, A. et al. Multiparametric MRI for prostate cancer diagnosis: current status and future directions. *Nat. Rev. Urol.* **17**, 41–61 (2020).
26. McNeal, J. E., Redwine, E. A., Freiha, F. S. & Stamey, T. A. Zonal distribution of prostate cancer. Correlation with histologic pattern and direction of spread. *Am. J. Surg. Pathol.* **12**, 897–906 (1988).
27. Cohen, M. R. *Laparoscopy, Culdography and Ginecography; Technique* (Atlas Saunders, 1970).
28. Ferguson, C. M. Electrosurgical laparoscopic cholecystectomy. *Am. Surg.* **58**, 96–99 (1992).
29. Ferzili, G. J., Trapasso, A., Raboy, A. & Albert, P. Extraperitoneal endoscopic pelvic lymph node dissection. *J. Laparoendosc. Surg.* **2**, 39–44 (1992).
30. Abbou, C. C. et al. Laparoscopic radical prostatectomy: preliminary results. *Urology* **55**, 630–633 (2000).
31. Steiner, M., Morton, R. A. & Walsh, P. C. Impact of anatomical radical prostatectomy on urinary continence. *J. Urol.* **145**, 512–515 (1991).
32. Touijer, K. et al. Comprehensive prospective comparative analysis of outcomes between open and laparoscopic radical prostatectomy conducted in 2003 to 2005. *J. Urol.* **179**, 1811–1817 (2008).
33. Ballantyne, G. H. & Moll, F. The daVinci telerobotic surgical system: the virtual operative field and telepresence surgery. *Surg. Clin. North Am.* **83**, 1293–1304 (2003).
34. Menon, M. et al. Vattikuti institute prostatectomy, a technique of robotic radical prostatectomy for management of localized carcinoma of the prostate: experience of over 1100 cases. *Urol. Clin. North Am.* **31**, 701–717 (2004).
35. Abbou, C. C. et al. Laparoscopic radical prostatectomy with a remote controlled robot. *J. Urol.* **165**, 1964–1966 (2001).
36. Binder, J. & Kramer, W. Robotically-assisted laparoscopic radical prostatectomy. *BJU Int.* **87**, 408–410 (2001).
37. Goad, J. R. Scardino 1994 modifications of technique of radical prostatectomy to minimise blood loss. *Atlas Urol. Clin. North Am.* **2**, 510–513 (1994).
38. Patel, V. R. et al. Pentafecta: a new concept for reporting outcomes of robot-assisted laparoscopic radical prostatectomy. *Eur. Urol.* **59**, 702–707 (2011).
39. Nelson, J. B. The ongoing challenge of urinary incontinence after radical prostatectomy. *J. Urol.* **198**, 1223–1225 (2017).
40. Kaye, D. R. et al. Robotic surgery in urological oncology: patient care or market share? *Nat. Rev. Urol.* **12**, 55–60 (2015).
41. Yaxley, J. W. et al. Robot-assisted laparoscopic prostatectomy versus open radical retropubic prostatectomy: early outcomes from a randomised controlled phase 3 study. *Lancet* **388**, 1057–1066 (2016).
42. Secin, F. P., Joborn-Andres, T. & Bjartell, S. Multi-institutional study of symptomatic deep venous thrombosis and pulmonary embolism in prostate cancer patients undergoing laparoscopic or robot-assisted laparoscopic radical prostatectomy. *Eur. Urol* **53**, 134–145 (2008).
43. Cisek, L. J. & Walsh, P. C. Thromboembolic complications after radical retropubic prostatectomy. *Urology* **42**, 406–408 (1993).
44. Magera, J. S. et al. Increased optical magnification from 2.5× to 4.3× with technical modification lowers the positive margin rate in open radical retropubic prostatectomy. *J. Urol.* **179**, 130–135 (2008).
45. Kaye, D. R., Mullins, J. K., Carter, H. B. & Bivalacqua, T. J. Robotic surgery in urological oncology: patient care or market share? *Nat. Rev. Urol.* **12**, 55–60 (2015).
46. Vaessen, C. Location of robotic surgical systems world-wide and in France. *J. Visc. Surg.* **148** (Suppl.), e9–e11 (2011).
47. Rassweiler, J. J. et al. Future of robotic surgery in urology. *BJU Int.* **120**, 822–841 (2017).
48. Capogrosso, P. et al. Are we improving erectile function recovery after radical prostatectomy? Analysis of patients treated over the last decade. *Eur. Urol.* **75**, 221–228 (2019).
49. Costello, A. J. Editorial comment. *J. Urol.* **198**, 606 (2017).
50. Novara, G. et al. Systematic review and meta-analysis of studies reporting oncologic outcome after robot-assisted radical prostatectomy. *Eur. Urol.* **62**, 382–404 (2012).
51. Carlsson, S. et al. Oncological and functional outcomes 1 year after radical prostatectomy for very-low-risk prostate cancer: results from the prospective LAPPRO trial. *BJU Int.* **118**, 205–212 (2016).
52. Trinh, Q. D. et al. A systematic review of the volume-outcome relationship for radical prostatectomy. *Eur. Urol.* **64**, 786–798 (2013).
53. Thompson, R. H., Slezak, J. M., Webster, W. S. & Lieber, M. M. Radical prostatectomy for octogenarians: how old is too old? *Urology* **68**, 1042–1045 (2006).
54. Costello, A. J. Beyond marketing: the real value of robotic radical prostatectomy. *BJU Int.* **96**, 1–2 (2005).
55. Coughlin, G. D. et al. Robot-assisted laparoscopic prostatectomy versus open radical retropubic prostatectomy: 24-month outcomes from a randomised controlled study. *Lancet Oncol.* **19**, 1051–1060 (2018).
56. Vickers, A. J. Editorial comment on: impact of surgical volume on the rate of lymph node metastases in patients undergoing radical prostatectomy and extended pelvic lymph node dissection for clinically localized prostate cancer. *Eur. Urol.* **54**, 802–803 (2008).
57. Begg, C. B. et al. Variations in morbidity after radical prostatectomy. *N. Engl. J. Med.* **346**, 1138–1144 (2002).
58. Vickers, A. J. et al. Effects of pathologic stage on the learning curve for radical prostatectomy: evidence that recurrence in organ-confined cancer is largely related to inadequate surgical technique. *Eur. Urol.* **53**, 960–966 (2008).
59. Tharmalingam, H. et al. New approaches for effective and safe pelvic radiotherapy in high-risk prostate cancer. *Nat. Rev. Urol.* **16**, 523–538 (2019).
60. Ku, S., Gleave, M. E. & Beltran, H. Towards precision oncology in advanced prostate cancer. *Nat. Rev. Urol.* **16**, 645–654 (2019).
61. Rescigno, P. & de Bono, J. S. Immunotherapy for lethal prostate cancer. *Nat. Rev. Urol.* **16**, 69–70 (2019).
62. Bruinsma, S. et al. Semantics in active surveillance for men with localized prostate cancer — results of a modified Delphi consensus procedure. *Nat. Rev. Urol.* **14**, 312–322 (2017).
63. Student, V. Jr. et al. Advanced reconstruction of vesicourethral support (ARVUS) during robot-assisted radical prostatectomy: one-year functional outcomes in a two-group randomised controlled trial. *Eur. Urol.* **71**, 822–830 (2017).
64. Rocco, B. et al. Posterior musculofascial reconstruction after radical prostatectomy: a systematic review of the literature. *Eur. Urol.* **62**, 779–790 (2012).
65. Coakley, F. V. et al. Urinary continence after radical retropubic prostatectomy: relationship with membranous urethral length on preoperative endorectal magnetic resonance imaging. *J. Urol.* **168**, 1032–1035 (2002).
66. Schlomm, T. et al. Full functional-length urethral sphincter preservation during radical prostatectomy. *Eur. Urol.* **60**, 320–329 (2011).
67. Menon, M. et al. Functional recovery, oncologic outcomes and postoperative complications after robot-assisted radical prostatectomy: an evidence-based analysis comparing the retzius sparing and standard approaches. *J. Urol.* **199**, 1210–1217 (2018).
68. John, H. & Hauri, D. Seminal vesicle-sparing radical prostatectomy: a novel concept to restore early urinary continence. *Urology* **55**, 820–824 (2000).
69. Savera, A. T. et al. Robotic radical prostatectomy with the "Veil of Aphrodite" technique: histologic evidence of enhanced nerve sparing. *Eur. Urol.* **49**, 1065–1073 (2006).
70. Haglind, E. et al. Urinary incontinence and erectile dysfunction after robotic versus open radical prostatectomy: a prospective, controlled, nonrandomised trial. *Eur. Urol.* **68**, 216–225 (2015).
71. Pignot, G. et al. Systemic treatments for high-risk localized prostate cancer. *Nat. Rev. Urol.* **15**, 498–510 (2018).
72. Klotz, L. et al. Clinical results of long-term follow-up of a large, active surveillance cohort with localized prostate cancer. *J. Clin. Oncol.* **28**, 126–131 (2010).
73. Dall'Era, M. A. et al. Active surveillance for prostate cancer: a systematic review of the literature. *Eur. Urol.* **62**, 976–983 (2012).
74. Lengana, T. et al. (68)Ga-PSMA PET/CT replacing bone scan in the initial staging of skeletal metastasis in prostate cancer: a fait accompli? *Clin. Genitourin. Cancer* **16**, 392–401 (2018).
75. Culp, S. H., Schellhammer, P. F. & Williams, M. B. Might men diagnosed with metastatic prostate cancer benefit from definitive treatment of the primary tumor? A SEER-based study. *Eur. Urol.* **65**, 1058–1066 (2014).
76. Dundee, P. et al. Ga-labeled prostate-specific membrane antigen ligand-positron-emission tomography: still just the tip of the iceberg. *Urology* **120**, 187–191 (2018).
77. Finne, P. et al. Lead time in the European randomised study of screening for prostate cancer. *Eur. J. Can.* **46**, 3102–3108 (2010).
78. Assel, M. et al. Association between lead time and prostate cancer grade: evidence of grade progression from long-term follow-up of large population-based cohorts not subject to prostate-specific antigen screening. *Eur. Urol.* **73**, 961–967 (2018).
79. Halsted, W. S. I. A clinical and histological study of certain adenocarcinomata of the breast: and a brief consideration of the supraclavicular operation and of the results of operations for cancer of the breast from 1889 to 1898 at the Johns Hopkins Hospital. *Ann. Surg.* **28**, 557–576 (1898).
80. Babaian, R. et al. Metastases from transitional cell carcinoma of the bladder. *Urology* **16**, 142–144 (1980).
81. Shah, R. B. et al. Androgen independant prostate cancer is a heterogenous group of diseases. *Cancer Res.* **64**, 9209–9216 (2004).
82. Sharma, V. et al. Gene expression correlates of site-specific metastasis among men with lymph node positive prostate cancer treated with radical prostatectomy: a case series. *Urology* **112**, 29–32 (2018).
83. van Leeuwen, F. W. B. et al. Technologies for image-guided surgery for managing lymphatic metastases in prostate cancer. *Nat. Rev. Urol.* **16**, 159–171 (2019).
84. Perera et al. Pelvic lymph node dissection during radical cystectomy for muscle-invasive bladder cancer. *Nat. Rev. Urol.* **15**, 686–692 (2018).
85. Mattei, A. et al. The template of theprimary lymphatic landing sites of the prostate should be revisited: results of a multimodality mapping study. *Eur. Urol.* **53**, 118–125 (2008).
86. Yaxley, J. W. et al. Reconsidering the role of pelvic lymph node dissection with radical prostatectomy for prostate cancer in an era of improving radiological staging techniques. *World J. Urol.* **36**, 15–20 (2018).
87. Ploussard, G. et al. Pelvic lymph node dissection during robot-assisted radical prostatectomy: efficacy, limitations, and complications-a systematic review of the literature. *Eur. Urol.* **65**, 7–16 (2014).
88. Donin, N. M. & Reiter, R. E. Why targeting PSMA is a game changer in the management of prostate cancer. *J. Nucl. Med.* **59**, 177–182 (2018).
89. Jadvar, H. & Ballas, L. K. PSMA PET: transformational change in prostate cancer management? *J. Nucl. Med.* **59**, 228–229 (2018).
90. Meredith, G. et al. The use of GaPSMA PET/CT in men with biochemical recurrence after definitive treatment of acinar prostate cancer. *BJU Int.* **118**, 49–55 (2016).
91. Burkhard, F. C. & Studer, U. E. The role of lymphadenectomy in high risk prostate cancer. *World J. Urol.* **26**, 231–236 (2008).
92. Aguirre-Ghiso, J. A. Models, mechanisms and clinical evidence for cancer dormancy. *Nat. Rev. Cancer* **7**, 834–846 (2007).
93. Seiler, R., Studer, U. E., Tschan, K., Bader, P. & Burkhard, F. C. Removal of limited nodal disease in

patients undergoing radical prostatectomy: long-term results confirm a chance for cure. *J. Urol.* **191**, 1280–1285 (2014).
94. Pierorazio, P. M. et al. Pathological and oncologic outcomes for men with positive lymph nodes at radical prostatectomy: the Johns Hopkins Hospital 30-year experience. *Prostate* **73**, 1673–1680 (2013).
95. Ost, P. et al. Progression-free survival following stereotactic body radiotherapy for oligometastatic prostate cancer treatment-naive recurrence: a multi-institutional analysis. *Eur. Urol.* **69**, 9–12 (2016).
96. Murphy, D. G. & Costello, A. J. How can the autonomic nervous system contribute to urinary continence following radical prostatectomy? a "boson-like" conundrum. *Eur. Urol.* **63**, 445–447 (2013).
97. Reeves, F. et al. Preservation of the neurovascular bundles is associated with improved time to continence after radical prostatectomy but not long-term continence rates: results of a systematic review and meta-analysis. *Eur. Urol.* **68**, 692–704 (2015).
98. Takenaka, A. et al. Preservation of the puboprostatic collar and puboperineoplasty for early recovery of urinary continence after robotic prostatectomy: anatomic basis and preliminary outcomes. *Eur. Urol.* **51**, 433–440 (2007).
99. Sohayda, C. et al. Extent of extracapsular extension in localized prostate cancer. *Urology* **55**, 382–386 (2000).
100. Costello, A. J., Brooks, M. & Cole, O. J. Anatomical studies of the neurovascular bundle and cavernosal nerves. *BJU Int.* **94**, 1071–1076 (2004).
101. Weerakoon, M. et al. The current use of active surveillance in an Australian cohort of men: a pattern of care analysis from the Victorian Prostate Cancer Registry. *BJU Int.* **115**, 50–56 (2015).
102. Parker, C. C. et al. Radiotherapy to the primary tumour for newly diagnosed, metastatic prostate cancer (STAMPEDE): a randomised controlled phase 3 trial. *Lancet* **392**, 2353–2366 (2018).
103. DiBlasio, C. J. et al. Patterns of sexual and erectile dysfunction and response to treatment in patients receiving androgen derivation therapy for prostate cancer. *BJU Int.* **102**, 39–43 (2008).
104. Jadvar, H. & Ballas, L. K. PSMA PET: transformational change in prostate cancer management. *J. Nucl. Med.* **59**, 228–229 (2018).
105. Clark, C. E. et al. Adopting robotics training into a general surgery residency curriculum: where are we now? *Curr. Surg. Rep.* **7**, 2 (2019).
106. Clarebrough, E. E. et al. Cadaveric analysis of periprostatic nerve distribution: an anatomical basis for high anterior release during radical prostatectomy? *J. Urol.* **185**, 1519–1525 (2011).
107. Koraitim, M. M. The male urethral sphincter complex revisited: an anatomical concept and its physiological correlate. *J. Urol.* **179**, 1683–1689 (2008).
108. Kim, P. H. et al. Trends in the use of incontinence procedures after radical prostatectomy: a population based analysis. *J. Urol.* **189**, 602–608 (2013).
109. Ficarra, V. et al. Systematic review and meta-analysis of studies reporting potency rates after robot-assisted radical prostatectomy. *Eur. Urol.* **62**, 418–430 (2012).
110. Gilbert, S. M. et al. Functional outcomes following nerve sparing prostatectomy augmented with seminal vesicle sparing compared to standard nerve sparing prostatectomy: results from a randomized controlled trial. *J. Urol.* **198**, 600–607 (2017).
111. Lim, S. K. et al. Retzius-sparing robot-assisted laparoscopic radical prostatectomy: combining the best of retropubic and perineal approaches. *BJU Int.* **114**, 236–244 (2014).
112. Dalela, D. et al. A pragmatic randomized controlled trial examining the impact of Retzius-sparing approach on early urinary continence recovery after robot-assisted radical prostatectomy. *Eur. Urol.* **72**, 677–685 (2017).
113. Brennen, W. N. & Isaacs, J. T. Mesenchymal stem cells and the embryonic reawakening theory of BPH. *Nat. Rev. Urol.* **15**, 703–715 (2018).

Acknowledgements
The author thanks H. Crowe for her valuable contributions to the manuscript.

Competing interests
The author declares no competing interests.

Publisher's note
Springer Nature remains neutral with regard to jurisdictional claims in published maps and institutional affiliations.