La Revue de médecine interne 36 (2015) 15–21

Disponible en ligne sur
ScienceDirect
www.sciencedirect.com

Elsevier Masson France
EM|consulte
www.em-consulte.com

Review

Idiopathic and secondary forms of retroperitoneal fibrosis: A diagnostic approach

M.L. Urban[a], A. Palmisano[a], M. Nicastro[a], D. Corradi[b], C. Buzio[a], A. Vaglio[a,*]

[a] Unit of nephrology, university hospital, Parma, Italy
[b] Section of pathology and laboratory medicine, department of biomedical, biotechnological and translational sciences, university hospital, Parma, Italy

ARTICLE INFO

Article history:
Available online 18 November 2014

Keywords:
Retroperitoneal fibrosis
IgG4-related disease
Idiopathic retroperitoneal fibrosis
Secondary retroperitoneal fibrosis

ABSTRACT

Retroperitoneal fibrosis (RPF) is an uncommon disease characterized by a fibrous reaction that takes place in the peri-aortic retroperitoneum and often entraps the ureters causing obstructive uropathy. RPF is idiopathic in the majority of cases, but can also be secondary to malignancies, infections, drugs, radiotherapy, and rare histiocytic disorders such as Erdheim–Chester disease. Idiopathic RPF is an immune-mediated disease, which can either be isolated, associated with other autoimmune diseases, or arise in the context of a multifocal fibro-inflammatory disorder recently renamed as IgG4-related disease. The differential diagnosis between idiopathic, IgG4-related and secondary RPF is crucial, essentially because the therapeutic approaches – especially of idiopathic vs. secondary RPF – can be dramatically different. This review focuses on the clinical, laboratory and imaging features of the different RPF forms, and also provides an overview of the available treatment options.

1. Introduction

Retroperitoneal fibrosis (RPF) comprises a spectrum of rare diseases hallmarked by the presence of an aberrant fibro-inflammatory tissue that usually develops around the infra-renal portion of the abdominal aorta and the iliac arteries and frequently entraps neighbouring structures such as the ureters and the inferior vena cava [1]. Retroperitoneal fibrosis may develop around an undilated or a dilated aorta, therefore “non-aneurysmal forms” and “peri-aneurysmal forms” of RPF can be distinguished.

Idiopathic RPF accounts for more than two thirds of the cases of RPF, the remaining third being secondary to other causes such as neoplasms, infections, trauma, radiotherapy, surgery, and intake of drugs [2]. The diagnosis is generally obtained by means of appropriate imaging studies (e.g., abdomen computed tomography, or magnetic resonance imaging) but, in patients presenting with a newly diagnosed RPF, it is mandatory to exclude malignancy with an age-appropriate cancer screening and, when there are clinical and radiological signs of underlying malignancies or infections, a retroperitoneal biopsy should be performed.

There are no standardized criteria to classify idiopathic RPF, but this is currently included in the spectrum of chronic periaortitis (CP) together with peri-aneurysmal RPF and inflammatory abdominal aortic aneurysms, as all of these forms have common histological features and a similar clinical presentation; recently, it has been proposed that CP is a form of large vessel vasculitis, especially in cases that also show thoracic aorta involvement [3]. Furthermore, idiopathic RPF (or CP) may be isolated or may develop in the context of a systemic immune-mediated disease.

Some authors argued that idiopathic RPF is part of the spectrum of immunoglobulin G4 (IgG4)-related disease (IgG4-RD) an immune-mediated disorder that may affect different organs (e.g., pancreas, gallbladder, salivary glands) and that is histologically hallmarked by a lymphoplasmacytic infiltrate rich in IgG4-bearing plasma cells, storiform fibrosis, tissue eosinophilia and obliterative phlebitis, and also characterised by increased levels of serum IgG4 in a significant proportion of cases [4,5]; some cases of idiopathic RPF have indeed such histological and clinical features, and can therefore be classified as being IgG4-related [6], although the exact proportion of IgG4-related out of the total number of idiopathic RPF cases is still unclear.

This review will focus on the clinical features of idiopathic RPF and will explore how to differentiate this entity from other diseases affecting the retroperitoneal space that can have a similar clinical presentation.

* Corresponding author. Unità Operativa di Nefrologia, Azienda Ospedaliero-Universitaria di Parma, Via Gramsci 14, 43126 Parma, Italy.
E-mail address: augusto.vaglio@virgilio.it (A. Vaglio).

http://dx.doi.org/10.1016/j.revmed.2014.10.008
0248-8663

2. Epidemiology

There are limited data about the epidemiology of this rare disease. One study from Finland showed an incidence of 0.1/100,000 inhabitants/year, and a prevalence of 1.4/100,000 inhabitants, whereas a more recent analysis performed in the Netherlands reported a 13-fold higher incidence, of 1.3/100,000 inhabitants/year [7,8]. This could mean that, with improved knowledge of the disease and greater accuracy of imaging techniques, the incidence of idiopathic RPF might turn out to be significantly higher than previously thought. The mean age at presentation is 50–60 years and there is a male predominance (male/female ratio 2:1 to 3:1). Pediatric cases are rare, with up to 30 patients described in the literature [9]. No clear data are available concerning the prevalence and incidence of secondary RPF [10].

3. Etiopathogenesis

Different mechanisms have been proposed to explain the pathogenesis of idiopathic RPF.

An early theory, proposed in the mid-1980s by Parums and Mitchinson, defined idiopathic RPF as a complication of advanced aortic atherosclerosis. These authors postulated that the fibro-inflammatory tissue may result from an initial processing of oxidized lipids by plaque macrophages, which migrate from the intima-media to the adventitia (especially when there is medial thinning as it occurs in atherosclerosis), where they present such lipids to lymphocytes and plasma cells, thus triggering adventitial and peri-adventitial inflammation and fibrosis [11]. However, this theory contrasts with the clinical evidence of idiopathic RPF in patients who do not suffer from atherosclerosis or have suffered no major cardiovascular events. In addition, this view cannot explain the complex systemic nature of idiopathic RPF, which in many cases presents with systemic symptoms, raised levels of inflammatory markers and concomitant autoimmune diseases involving other organs (e.g., Hashimoto's thyroiditis, small-vessel vasculitis, psoriasis and Sjögren's syndrome) [12,13].

Idiopathic RPF may instead be a manifestation of a systemic autoimmune disease, and may arise as a primary aortitis that subsequently elicits a peri-aortic fibro-inflammatory response. In keeping with this hypothesis is the observation that inflammation predominates in the adventitia, where vasculitis of *vasa vasorum* together with lymphoid follicles with germinal centers can also be found. Studies conducted on aortic biopsies showed the presence of gene transcripts of interferon-γ (IFN-γ), interleukin-1α (IL-1α), IL-2 and IL-4, suggesting lymphocytic activation [1,3,14]. Moreover, it has been reported that idiopathic RPF often affects other vascular segments (e.g., thoracic aorta, mesenteric arteries) that are usually spared by atherosclerosis [3,15]. Clinical findings such as the presence of systemic symptoms, the association with other autoimmune disorders as well as the good response to immunosuppressive therapies fit this systemic immune-mediated theory.

Multiple factors may contribute to this process. Martorana et al. [16] demonstrated a strong association between idiopathic RPF and HLA-DRB1*03, an allele linked to many autoimmune conditions such as type 1 diabetes, myasthenia gravis and autoimmune thyroiditis. A recent study also described an increased susceptibility to develop idiopathic RPF, especially its aneurysmal form, in patients carrying the delta 32 (Δ32) polymorphism of the CC-chemokine receptor 5 (*CCR5*) gene [17]. CCR5 is expressed on many immune cells, particularly Th1 cells, and acts by binding several chemokines, including RANTES, MIP-1α and MIP-1β. The *CCR5*Δ32 polymorphism creates a truncated, nonfunctional receptor and probably shifts the immune response toward a Th2 pattern.

Environmental factors also play a role in the susceptibility to idiopathic RPF. Occupational asbestos exposure and tobacco smoke are two important risk factors for the development of idiopathic RPF [7]. Goldoni et al. [18] have recently shown that the interaction between these two factors has a multiplicative effect rather than just an additive one: this translates into a markedly increased risk of developing idiopathic RPF (with an odds ratio > 10) when a patient is exposed to both factors [18].

The role of microbial agents as disease triggers is still elusive [19,20].

A broad range of factors may cause secondary forms of RPF, including drugs, infections, external-beam radiation and malignancies.

With regards to drugs, the most frequent associations are between RPF and derivatives of ergot alkaloids (e.g., methysergide, ergotamine), or with dopamine agonists (e.g., pergolide, methyldopa). Methysergide and the other ergotamine-derived agents increase the levels of endogenous serotonin and this has been suggested to lead to fibrotic reactions through proliferation of myofibroblasts and increase in collagen matrix deposition. This fibrogenic effect is not only limited to the retroperitoneum, but may also involve pericardium, pleura, and lungs [21]. Other medications reported as associated with RPF include β-blockers, hydralazine and phenacetin but whether there is a true causal relationship is still debated [1,22,23].

Recently, cases of RPF secondary to the use of biological agents have been reported, especially with the use of infliximab, a monoclonal antibody directed against tumor necrosis factor-α (TNF-α), and etanercept, a soluble receptor that acts as a TNF-α blocker [24,25]. How these drugs, widely employed in the treatment of rheumatic diseases, may trigger a fibrotic reaction in the retroperitoneum is still unclear, although it is well known that they may trigger a number of autoimmune conditions.

Malignancies are often listed as potential causes of secondary RPF. In most of these cases, RPF is the consequence of an exuberant desmoplastic response of retroperitoneal metastases (e.g., carcinoma of the prostate, breast, colon) or of a primary retroperitoneal tumor (e.g., Hodgkin's and non-Hodgkin lymphomas, inflammatory myofibroblastic tumour, well-differentiated liposarcoma sclerosing variant and various types of sarcomas) [26]. The only exception are carcinoids, that are likely to induce RPF in the absence of metastases, or primary localisations in the retroperitoneum, probably through a mechanism mediated by serotonin or by the release of profibrogenic growth factors such as platelet-derived growth factor, insulin-like growth factors, epidermal growth factor and the family of transforming growth factors α and β [27].

In case of infection-related RPF, the disease is usually secondary to the local spread of a contiguous infectious focus (e.g., spinal or paraspinal abscesses in patients with tuberculosis), or to an immune response triggered by a remote infection. In addition to *Mycobacterium tuberculosis*, which has often been reported as etiologic agent, actinomycosis or histoplasmosis can sometimes represent the primary infections [28].

Other potential causes of RPF include radiotherapy, trauma, major abdominal surgery, proliferative disorders such as Erdheim–Chester disease, a rare form of non-Langerhans cell histiocytosis, and other histiocytoses [29].

4. Pathology: gross and microscopic findings

In terms of macroscopic findings the idiopathic and secondary forms of RPF may look similar. RPF appears as a hard and grayish mass that infiltrates the retroperitoneal adipose tissue and does not have a fibrous capsule. In neoplastic forms the retroperitoneal

masses appear irregular in morphology depending on the type of tumors.

The microscopic observation of idiopathic RPF samples reveals the presence of two components: a fibrous tissue and an inflammatory infiltrate [30]. The fibrous component consists of an abundant matrix composed of type I collagen and a population of spindle-shaped cells characterized immuno-histochemically as fibroblasts and myofibroblasts (positive for vimentin and α-smooth muscle actin, respectively). The fibroblast population does not show any sign of active proliferation (mitoses). The collagenous stroma contains varying quantities of nerves and small blood vessels that often show a prominent perivascular hyalinisation. The inflammatory component infiltrates variably the fibrous tissue and consists of lymphocytes, macrophages, plasma cells and rare eosinophils organized into perivascular and diffuse patterns (Fig. 1). In the first pattern, aggregated lymphocytes surround the small retroperitoneal vessels and tend to have a central core of B cells and a periphery of CD4+ and CD8+ T cells. In contrast, the diffuse pattern is characterized by inflammatory infiltration of the narrow spaces within the collagen bundles with T cells outnumbering B cells [10].

In IgG4-related RPF the microscopic findings are very similar to those of idiopathic RPF; IgG4-related RPF shows more commonly obliterative phlebitis, a mild-to-moderate eosinophil infiltrate, and fibrosis with a storiform pattern. As in idiopathic RPF, the inflammatory infiltrate is composed of T and B lymphocytes, whereas B cells are typically organized in germinal centers and T cells are distributed diffusely. Although IgG4-bearing plasma cells may be also found in the inflammatory infiltrate of idiopathic RPF, what is essential for the diagnosis of IgG4-RD is a ratio of IgG4-bearing plasma cells to total IgG-bearing plasma cells higher than 30–50% (Fig. 1) [5].

The secondary forms of RPF caused by malignancies are characterized by the presence of neoplastic cells scattered into an abundant fibrous tissue; disruption or infiltration of neighboring muscle and bone structures is commonly found. The inflammatory infiltrate can be monoclonal in case of lymphomas and the presence of lipoblasts may suggest the diagnosis of well-differentiated liposarcomas with sclerosing and inflammatory features.

Finally, Erdheim–Chester disease is characterized by varying amounts of "foamy" histiocytes (consistently CD68KP1 positive and negative for CD1a) in dense collagen tissue [29].

5. Clinical features and laboratory tests

All the forms of RPF (i.e., idiopathic, secondary, and IgG4-related) have similar clinical manifestations, thus their clinical presentation may not be of help in the differential diagnosis.

At disease onset, the patients often suffer from a dull and constant side, back, or abdominal pain, which can become colic-like when the ureters are encased. Renal failure due to a bilateral ureteral obstruction is seen in about 42–95% of the cases; other, less frequent complications include: lower extremity edema and deep vein thrombosis arising as a consequence of the chronic compression/obstruction of the lymphatic vessels and veins respectively, scrotal swelling, varicocoele or hydrocoele, resulting from the involvement of the gonadal vessels, and constipation [31]. When the thoracic aorta or the peri-aortic arteries are involved, patients may suffer from hoarseness, secondary to recurrent laryngeal nerve paralysis, dry cough or upper limb claudication.

In most patients, systemic or constitutional symptoms are present and they include fatigue, low-grade fever, nausea, anorexia, weight loss, and myalgia [1]. Inflammatory markers such as erythrocyte sedimentation rate (ESR) and C-reactive protein (CRP) are elevated in more than half of the patients and do not help in differentiating idiopathic and secondary RPF [32]. The monitoring of ESR and CRP levels is often useful to follow the clinical course of the disease [2].

There is a strong association between idiopathic RPF and other autoimmune/inflammatory diseases, especially autoimmune thyroid diseases (e.g., Hashimoto's and Riedel's thyroiditis), anti-neutrophil cytoplasmic antibody (ANCA)-positive glomerulonephritis, rheumatoid arthritis, psoriasis and systemic lupus erythematosus [2,12,13,16,32–34].

IgG4-related (systemic) disease is often diagnosed incidentally through radiologic findings and, contrary to idiopathic RPF, usually shows a subacute course with no significant elevation of the inflammatory markers and absence of constitutional symptoms [5]. The disease ranges from organ-limited to multi-systemic forms, where the clinical manifestations can be synchronous or metachronous [5]. Unlike patients with idiopathic RPF, those with IgG4-RD usually have a history of chronic allergic conditions (e.g., atopy, eczema, asthma and peripheral blood eosinophilia) and they tend to develop tumour-like lesions, which may be responsible for tumorous swellings of the affected organs [5].

Ureteral encasement and renal dysfunction are closely related but, since an underlying glomerulonephritis can be present, proteinuria and urinary sediment should always be checked. Microscopic or macroscopic hematuria may be found even in absence of any renal parenchymal disease, probably as a result of ureteral entrapment/injury.

Idiopathic RPF requires a detailed evaluation of autoimmune tests. Antinuclear antibodies (ANAs) and anti-smooth-muscle antibodies are the most frequently positive autoantibodies followed by rheumatoid factor. The presence of these autoantibodies, although non-organ specific and often positive at low titers, may suggest an autoimmune origin of the disease. ANCA have been identified in cases associated with granulomatosis with polyangiitis (previously Wegener's disease) and microscopic polyangiitis while the presence of antibodies against thyroid microsome and thyroglobulin is usually associated with an autoimmune thyroiditis, probably the autoimmune disease most frequently associated with idiopathic RPF [2,32].

One of the most important characteristics of IgG4-RD is the presence of high IgG4 serum levels [6]. Few data exist on serum IgG4 levels in patients with extra-pancreatic IgG4-RD. Most patients have elevated serum IgG4 concentrations, but the range varies. Published data reported that approximately 30% of patients have normal serum IgG4 concentrations, despite the presence of classic histopathological and immunohistochemical findings, including a significant infiltration of IgG4-bearing plasma cells [5].

Malignancies of the retroperitoneum cannot be identified by any specific laboratory test but, when approaching a patient with a suspected RPF, it is mandatory to perform an age-appropriate cancer screening.

6. Imaging

Imaging studies play a key role in the diagnosis and management of idiopathic RPF and can help classify RPF as idiopathic or secondary.

Ultrasonography is usually the first-line study performed at the disease onset to assess the presence of hydronephrosis and aortic dilatation/aneurysm; in a few cases, a hypo-echoic peri-aortic tissue may be disclosed.

Currently, abdominal computed tomography (CT) and magnetic resonance imaging (MRI) are considered the imaging studies of choice to diagnose idiopathic RPF [1,35]. On CT, it appears as a homogeneous tissue, isodense to muscle, surrounding the lower abdominal aorta and the iliac arteries, and often enveloping

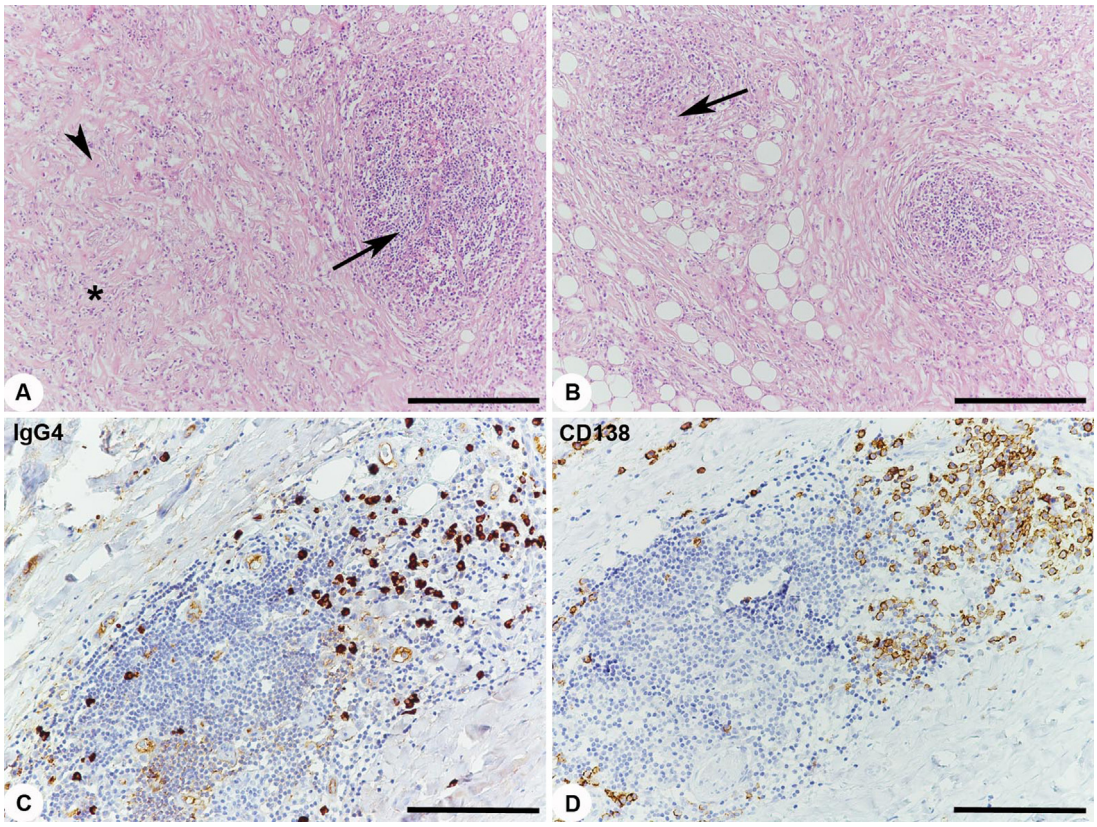

Fig. 1. Pathology of idiopathic retroperitoneal fibrosis. A. Idiopathic retroperitoneal fibrosis is a fibro-inflammatory disorder whose main components are a dense fibrous tissue with thick collagen bands (arrowhead) and an inflammatory infiltrate that is organized in a perivascular (arrow) or diffuse (asterisk) pattern. B. Especially within the perivascular inflammatory aggregates, vasculitic images (arrow) are sometimes detectable. In a fraction of cases, there are significant amounts of IgG4-positive plasma cells (C), compared to the total population of CD138-positive plasma cells (D). Staining. A and B. Hematoxylin-eosin. C and D. 3,3'-diaminobenzidine-revealed immunohistochemical analysis. Original magnification. A and B. ×10 (bar is 300 μm). C and D. ×20 (bar is 150 μm).

neighboring structures such as the ureters that generally are displaced medially [10].

Magnetic resonance imaging may provide a better definition of RPF against the surrounding tissues, mainly when fat-saturation images are used. Idiopathic Retroperitoneal fibrosis on MRI is hypointense in T1-weighted images; in T2-weighted images its intensity is low in the quiescent phases of the disease and high in the active stages when there is abundant tissue oedema and hypercellularity. In a recent retrospective study, diffusion-weighted imaging (DWI) features and signal intensity values at T2-weighted MRI were evaluated for the differential diagnosis of benign RPF and plaque-like retroperitoneal malignant neoplasms. The authors concluded that DWI could contribute to differential diagnosis of chronic RPF and malignant neoplasms with RPF morphology. Lesions in the malignant group and active RPF group had similar enhancement patterns, while those in the chronic RPF group demonstrated weak enhancement. Signal intensity values on T2-weighted images were not useful for differentiating these conditions [36]. The administration of contrast medium is firmly recommended in the active phase of the disease when the mass enhances on CT and MRI [37].

Nuclear medicine is a useful complement to radiographic imaging as it provides an easy visualisation of the almost entire body. Fluorodeoxyglucose-positron emission tomography (FDG-PET) is a technique that assesses disease activity and is useful in diagnosis and monitoring. Specifically PET may show abnormal FDG uptake by the retroperitoneal mass in active disease whereas in later stages it is usually negative. FDG-PET can also reveal active vasculitis in other vascular territories and it may disclose other affected areas, such as those observed in IgG4-RD, or occult neoplastic or infectious processes which could potentially cause or be associated with RPF [38,39].

Morphological aspects of RPF on CT or MRI may help the physician to differentiate idiopathic from secondary forms. Idiopathic forms are usually characterized by plaque-like densities with peripheral infiltration whereas the proliferation of secondary forms is usually nodular and lobulated [40]. In terms of mass size, idiopathic RPF, unlike lymphomas and metastases, is usually located distal to the kidney hilium, anteriorly and laterally to the aorta that is not displaced forward, and the ureters are pushed medially. Cancers generally appear as fibrous mass dislocating the psoas muscles or destroying the bone whereas idiopathic RPF does not include any of these features [41]. Localized lymphadenopathies adjacent to RPF occur in idiopathic forms but when they become confluent and tend to surround the large vessels they are likely to be malignant.

Erdheim–Chester disease should be suspected when peri-aortic fibrosis is associated with symmetrical and bilateral peri-renal fibrosis [2]. The Fig. 2 shows representative CT images of idiopathic RPF, RPF secondary to non-Hodgkin lymphoma and RPF secondary to Erdheim–Chester disease.

When imaging studies do not show typical findings of idiopathic RPF, tissue biopsy is often required; biopsy may also be recommended in patients refractory to conventional steroid therapy. Multiple biopsy techniques have been used in sampling RPF, including open, laparoscopic or transcaval retroperitoneal biopsy, and fine-needle aspiration. However, in malignant RPF, the metastatic cells are usually dispersed so diffusely in the fibrotic tissue that multiple deep surgical biopsies are needed [40].

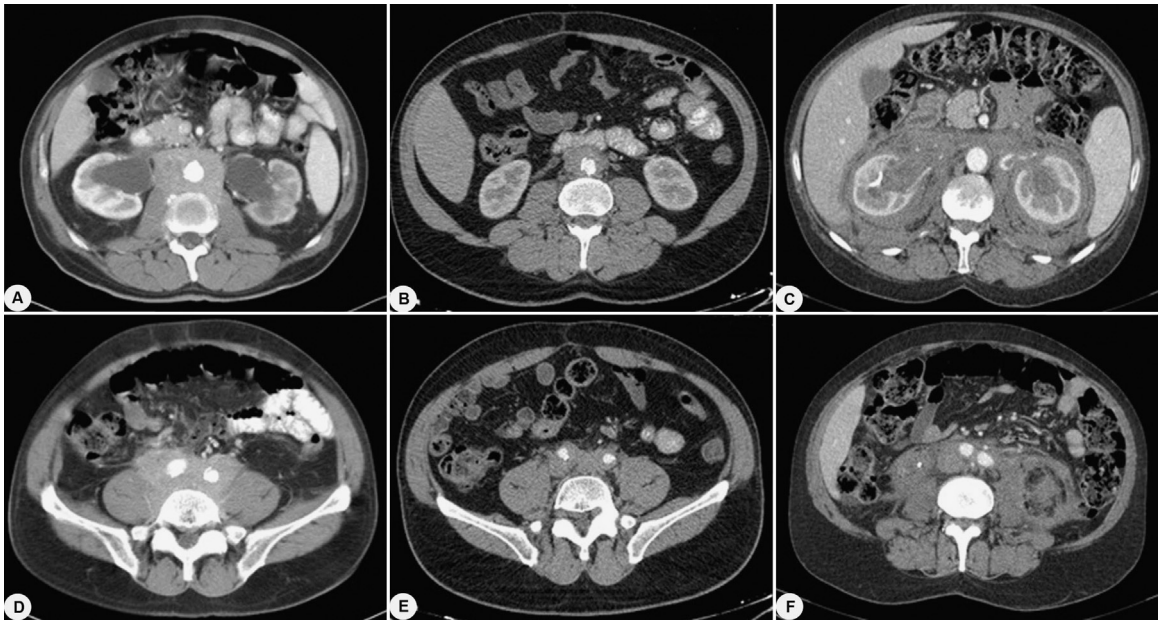

Fig. 2. Representative abdominal contrast-enhanced computed tomographic (CT) scan of idiopathic and secondary retroperitoneal fibrosis (RPF). The images show a case of non-Hodgkin lymphoma mimicking RPF; the muscle-isodense tissue encircles the abdominal aorta and displaces it anteriorly (A), a feature more common in malignant than in idiopathic disease. Bilateral hydronephrosis due to ureteral encasement is also seen. The tissue extends caudally to involve both common iliac arteries (D), and tends to infiltrate the psoas muscles, a feature that is unusual in idiopathic RPF. The scans show a typical case of idiopathic RPF, where the tissue develops around the anterior and lateral sides of the abdominal aorta (B) and encircles both common iliac arteries (E). RPF secondary to Erdheim–Chester disease; the retroperitoneal tissue diffusely and irregularly infiltrates the peri-aortic and peri-renal space, causing bilateral hydronephrosis (C), and also extends to surround the common iliac arteries (F). Peri-renal infiltration is rare in idiopathic RPF.

7. Therapy

The aims of treatment of idiopathic RPF are to induce regression of the fibro-inflammatory reaction, to relieve the obstruction of the ureters or other retroperitoneal structures, to switch off the acute-phase reaction and its systemic manifestations, and to avoid disease recurrence.

In all cases of renal failure and severe bilateral hydronephrosis, ureteral decompression should be promptly performed to avoid permanent kidney damage. If the "conservative" approach (ureteral stents or nephrostomies followed by medical therapy) is ineffective, it becomes mandatory to perform surgical/laparoscopic ureterolysis.

Medical therapy should also be initiated as soon as it is possible. Induction therapy with the use of high doses of prednisone (1 mg/kg/day for the first month) is the best option to curb disease activity. After one month of therapy, a re-evaluation of disease activity (symptoms, ESR and CRP) together with a morphological assessment of the mass is recommended. If remission is obtained, prednisone may be progressively tapered to 5–10 mg daily within 3–4 months, and then maintained for an additional 6–9 months. When a contraindication to glucocorticoid therapy is present, a good alternative may be the use of tamoxifen. This drug seems to have positive effects on fibrosing disorders based on its antiangiogenic properties and its capacity to down-regulate the release of growth factors involved in fibroblast proliferation and collagen production [42]. In the only randomized controlled trial performed in idiopathic RPF patients, 36 of 39 patients who obtained remission after induction therapy with prednisone were randomised to prednisone tapering or to switch to tamoxifen (0.5 mg/kg/day) for an overall duration of 8 months. Relapses were more frequent in the tamoxifen group, with the between-group difference in relapse rates being significant both at the end of treatment (month 8) and at 26 months follow-up [43]. Recently, tamoxifen has been employed as monotherapy in idiopathic RPF in a retrospective study on 55 patients; the results showed response in terms of mass reduction in 71% of the patients at month 4 and 85% at month 8, and confirmed its good tolerability [44]. In summary, although probably inferior to prednisone in maintaining remission, tamoxifen can be reserved to those patients who have contraindications to the use of glucocorticoids.

The treatment of the refractory/relapsing forms of idiopathic RPF (resistant to glucocorticoid therapy or frequently relapsing upon glucocorticoid tapering/withdrawal) is still a challenge. Several immunosuppressive drugs (e.g., mycophenolate mofetil, azathioprine, methotrexate, cyclosporine, cyclophosphamide, tamoxifen) have been employed but so far there have been only observational, uncontrolled clinical trials [43,45,46]. Low-dose prednisone plus methotrexate may represent an option for the treatment of relapsing patients who need a long-term therapy, and so is probably mycophenolate mofetil, due to its anti-inflammatory and antifibrotic activity [45,47]. However, both therapeutic approaches need to be investigated in prospective randomized studies.

Recently there have been some reports of a successful use of biologic agents in case of refractory idiopathic RPF. The agents employed are rituximab, infliximab (anti-TNF-α monoclonal antibody), and tocilizumab (anti-interleukin-6 receptor antibody) but the data are so scarce that no definitive conclusions can be drawn [24,48,49].

Idiopathic RPF in the context of IgG4-RD tends to respond promptly to 6–9 months of glucocorticoid therapy but in the refractory cases rituximab has been efficiently employed [5]. However, IgG4-related and -unrelated RPF probably represent different ends of the same disease spectrum; the degree of IgG4-plasma cell infiltration is the main histological distinctive feature, but no clinical or radiological differences are found [6]; thus, although studies comparing the outcome of these two entities are lacking, it is likely that they may be treated with similar medical approaches.

Treatment of the secondary forms of RPF requires, when possible, an approach based on the cause. Unfortunately, RPF caused by untreatable cancers, trauma, major surgery, and

radiotherapy, has no clear indications for systemic medical treatment and might only draw benefit from palliative surgical approaches. Malignant RPF carries a poor prognosis, with a mean survival of as little as 3–6 months. Retroperitoneal fibrosis secondary to Erdheim–Chester disease also requires interventional procedures in order to relieve ureteral obstruction, followed by specific medical therapies, which are now based on the use of interferon-α, various immunosuppressive therapies and, in cases bearing the V600E mutation of the *BRAF* proto-oncogene, the BRAF inhibitor vemurafenib.

8. Conclusions

Idiopathic RPF is a rare disorder, for which an early diagnosis is warranted in order to promptly start systemic therapy and to treat obstructive complications such as ureteral obstruction that may lead to irreversible kidney damage. The exclusion of secondary forms of RPF is mandatory as the effect of the drugs usually employed in cases of idiopathic RPF, especially immunosuppressive agents, may worsen the prognosis of RPF secondary to malignancies or infections. All patients with newly diagnosed RPF should undergo an age-appropriate cancer screening; with the aid of imaging studies (abdominal CT and MRI, whole body PET-CT) and of clinical and laboratory features, a diagnosis of idiopathic or secondary RPF is usually possible. In doubtful case, a tissue biopsy should be performed.

Finally, in the algorithm of the diagnostic approach for idiopathic RPF, physicians should always keep in mind that the disease may be associated with other extra-retroperitoneal inflammatory or autoimmune disorders.

Disclosure of interest

The authors declare that they have no conflicts of interest concerning this article.

References

[1] Vaglio A, Salvarani C, Buzio C. Retroperitoneal fibrosis. Lancet 2006;367:241–51.
[2] Palmisano A, Vaglio A. Chronic periaortitis: a fibro-inflammatory disorder. Best Pract Res Clin Rheumatol 2009;23:339–53.
[3] Pipitone N, Vaglio A, Salvarani C. Retroperitoneal fibrosis. Best Pract Res Clin Rheumatol 2012;26:439–48.
[4] Takahashi H, Yamamoto M, Suzuki C, Naishiro Y, Shinomura Y, Imai K. The birthday of a new syndrome: IgG4-related diseases constitute a clinical entity. Autoimmun Rev 2010;9:591–4.
[5] Stone JH, Zen Y, Deshpande V. IgG4-related disease. N Engl J Med 2012;366:539–51.
[6] Khosroshahi A, Carruthers MN, Stone JH, Shinagare S, Sainani N, Hasserjian RP, et al. Rethinking Ormond's disease: "idiopathic" retroperitoneal fibrosis in the era of IgG4-related disease. Medicine (Baltimore) 2013;92:82–91.
[7] Uibu T, Oksa P, Auvinen A, Honkanen E, Metsärinne K, Saha H, et al. Asbestos exposure as a risk factor for retroperitoneal fibrosis. Lancet 2004;363:1422–6.
[8] van Bommel EF, Jansen I, Hendriksz TR, Aarnoudse AL. Idiopathic retroperitoneal fibrosis: prospective evaluation of incidence and clinicoradiologic presentation. Medicine (Baltimore) 2009;88:193–201.
[9] Miller OF, Smith LJ, Ferrara EX, McAleer IM, Kaplan GW. Presentation of idiopathic retroperitoneal fibrosis in the pediatric population. J Pediatr Surg 2003;38:1685–8.
[10] Vaglio A, Palmisano A, Corradi D, Salvarani C, Buzio C. Retroperitoneal fibrosis: evolving concepts. Rheum Dis Clin North Am 2007;33:803–17 [vi–vii].
[11] Parums DV. The spectrum of chronic periaortitis. Histopathology 1990;16:423–31.
[12] Vaglio A, Manenti L, Allegri L, Ferrozzi F, Corradi D, Buzio C. ANCA-positive periaortic vasculitis: does it fall within the spectrum of vasculitis? J Intern Med 2002;251:268–71.
[13] Famularo G, Palmisano A, Afeltra A, Buzzulini F, Versari A, Minisola G, et al. Retroperitoneal fibrosis associated with psoriasis: a case series. Scand J Rheumatol 2009;38:68–9.
[14] Ramshaw AL, Roskell DE, Parums DV. Cytokine gene expression in aortic adventitial inflammation associated with advanced atherosclerosis (chronic periaortitis). J Clin Pathol 1994;47:721–7.
[15] Salvarani C, Calamia KT, Matteson EL, Hunder GG, Pipitone N, Miller DV, et al. Vasculitis of the gastrointestinal tract in chronic periaortitis. Medicine (Baltimore) 2011;90:28–39.
[16] Martorana D, Vaglio A, Greco P, Zanetti A, Moroni G, Salvarani C, et al. Chronic periaortitis and HLA-DRB1*03: another clue to an autoimmune origin. Arthritis Rheum 2006;55:126–30.
[17] Boiardi L, Vaglio A, Nicoli D, Farnetti E, Palmisano A, Pipitone N, et al. CC chemokine receptor 5 polymorphism in chronic periaortitis. Rheumatology (Oxford) 2011;50:1025–32.
[18] Goldoni M, Bonini S, Urban ML, Palmisano A, De Palma G, Galletti E, et al. Asbestos and smoking as risk factors for idiopathic retroperitoneal fibrosis: a case-control study. Ann Intern Med 2014;161:181–8.
[19] Tanaka S, Komori K, Okadome K, Sugimachi K, Mori R. Detection of active cytomegalovirus infection in inflammatory aortic aneurysms with RNA polymerase chain reaction. J Vasc Surg 1994;20:235–43.
[20] Tang T, Boyle JR, Dixon AK, Varty K. Inflammatory abdominal aortic aneurysms. Eur J Vasc Endovasc Surg 2005;29:353–62.
[21] Pfitzenmeyer P, Foucher P, Dennewald G, Chevalon B, Debieuvre D, Bensa P, et al. Pleuropulmonary changes induced by ergoline drugs. Eur Respir J 1996;9:1013–9.
[22] Ahmad S. Methyldopa and retroperitoneal fibrosis. Am Heart J 1983;105:1037–8.
[23] Ahmad S. Association of metoprolol and retroperitoneal fibrosis. Am Heart J 1996;131:202–3.
[24] Catanoso MG, Spaggiari L, Magnani L, Pipitone N, Versari A, Boiardi L, et al. Efficacy of infliximab in a patient with refractory idiopathic retroperitoneal fibrosis. Clin Exp Rheumatol 2012;30:776–8.
[25] Couderc M, Mathieu S, Dubost JJ, Soubrier M. Retroperitoneal fibrosis during etanercept therapy for rheumatoid arthritis. J Rheumatol 2013;40:1931–3.
[26] Thomas MH, Chisholm GD. Retroperitoneal fibrosis associated with malignant disease. Br J Cancer 1973;28:453–8.
[27] Rosenberg S, Katz R, Pode D, Gofrit NO, Pizov G, Hovav N. An ALK translocation positive carcinoma of the lung presenting as uremia due to bilateral renal obstruction. Can Urol Assoc J 2013;7:E490–4.
[28] Greco P, Vaglio A, Corradi D, Cobelli R, Zompatori M, Buzio C. Tuberculosis as a trigger of retroperitoneal fibrosis. Clin Infect Dis 2005;41:e72–5.
[29] Haroche J, Cohen-Aubart F, Arnaud L, Hervier B, Charlotte F, Drier A, et al. [Erdheim-Chester disease]. Rev Med Interne 2014, http://dx.doi.org/10.1016/j.revmed.2014.04.007.
[30] Corradi D, Maestri R, Palmisano A, Bosio S, Greco P, Manenti L, et al. Idiopathic retroperitoneal fibrosis: clinicopathologic features and differential diagnosis. Kidney Int 2007;72:742–53.
[31] Vaglio A, Buzio C. Chronic periaortitis: a spectrum of diseases. Curr Opin Rheumatol 2005;17:34–40.
[32] Vaglio A, Corradi D, Manenti L, Ferretti S, Garini G, Buzio C. Evidence of autoimmunity in chronic periaortitis: a prospective study. Am J Med 2003;114:454–62.
[33] Palmisano A, Corradi D, Carnevali ML, Alberici F, Silini EM, Gatti R, et al. Chronic periaortitis associated with membranous nephropathy: clues to common pathogenetic mechanisms. Clin Nephrol 2010;74:485–90.
[34] Vaglio A, Palmisano A, Ferretti S, Alberici F, Casazza I, Salvarani C, et al. Peripheral inflammatory arthritis in patients with chronic periaortitis: report of five cases and review of the literature. Rheumatology (Oxford) 2008;47:315–8.
[35] Salvarani C, Pipitone N, Versari A, Vaglio A, Serafini D, Bajocchi G, et al. Positron emission tomography (PET): evaluation of chronic periaortitis. Arthritis Rheum 2005;53:298–303.
[36] Bakir B, Yilmaz F, Turkay R, Ozel S, Bilgiç B, Velioglu A, et al. Role of diffusion-weighted MR imaging in the differentiation of benign retroperitoneal fibrosis from malignant neoplasm: preliminary study. Radiology 2014;272:438–45.
[37] Pipitone N, Ghinoi A, Versari A, Vaglio A, Palmisano A, Salvarani C. Images in cardiovascular medicine. Chronic periaortitis. Circulation 2008;118:1214–6.
[38] Pipitone N, Versari A, Vaglio A, Salvarani C. Role of 18F-fluorodeoxyglucose positron emission tomography in the workup of retroperitoneal fibrosis. Clin Exp Rheumatol 2011;29(1 Suppl 64):S72–8.
[39] Vaglio A, Versari A, Fraternali A, Ferrozzi F, Salvarani C, Buzio C. (18)F-fluorodeoxyglucose positron emission tomography in the diagnosis and follow-up of idiopathic retroperitoneal fibrosis. Arthritis Rheum 2005;53:122–5.
[40] Cronin CG, Lohan DG, Blake MA, Roche C, McCarthy P, Murphy JM. Retroperitoneal fibrosis: a review of clinical features and imaging findings. AJR Am J Roentgenol 2008;191:423–31.
[41] Mirault T, Lambert M, Puech P, Argatu D, Renaud A, Duhamel A, et al. Malignant retroperitoneal fibrosis: MRI characteristics in 50 patients. Medicine (Baltimore) 2012;91:242–50.
[42] Benson JR, Baum M. Tamoxifen for retroperitoneal fibrosis. Lancet 1993;341:836.
[43] Vaglio A, Palmisano A, Alberici F, Maggiore U, Ferretti S, Cobelli R, et al. Prednisone versus tamoxifen in patients with idiopathic retroperitoneal fibrosis: an open-label randomised controlled trial. Lancet 2011;378:338–46.
[44] van Bommel EF, Pelkmans LG, van Damme H, Hendriksz TR. Long-term safety and efficacy of a tamoxifen-based treatment strategy for idiopathic retroperitoneal fibrosis. Eur J Intern Med 2013;24:444–50.
[45] Alberici F, Palmisano A, Urban ML, Maritati F, Oliva E, Manenti L, et al. Methotrexate plus prednisone in patients with relapsing idiopathic retroperitoneal fibrosis. Ann Rheum Dis 2013;72:1584–6.

[46] Vaglio A, Greco P, Buzio C. Tamoxifen therapy for retroperitoneal fibrosis. Ann Intern Med 2006;144:619 [author reply –20].
[47] Scheel Jr PJ, Feeley N, Sozio SM. Combined prednisone and mycophenolate mofetil treatment for retroperitoneal fibrosis: a case series. Ann Intern Med 2011;154:31–6.
[48] Maritati F, Corradi D, Versari A, Casali M, Urban ML, Buzio C, et al. Rituximab therapy for chronic periaortitis. Ann Rheum Dis 2012;71:1262–4.
[49] Vaglio A, Catanoso MG, Spaggiari L, Magnani L, Pipitone N, Macchioni P, et al. Interleukin-6 as an inflammatory mediator and target of therapy in chronic periaortitis. Arthritis Rheum 2013;65:2469–75.